

Mesenchymal Glucocorticoid Receptor regulates the development of multiple cell layers of the mouse lung

Anthony D Bird¹, Yuen L Choo¹, Stuart B Hooper^{3,2}, Annie R.A McDougall^{1,3}, Timothy Cole¹

1. Monash University, Clayton, VIC, Australia

2. Department of Obstetrics and Gynaecology, Monash Medical Centre, Melbourne, VIC, Australia

3. The Ritchie Centre, Monash Institute of Medical Research, Melbourne, VIC, Australia

Endogenous glucocorticoid (GC) hormones, signaling via the GC receptor (GR), are essential for normal lung development, and synthetic GCs are routinely used to treat respiratory disorders of very preterm babies. Germline GR knockout (GR^{-/-}) mice show immature lung morphology and severe lung cellular hyperplasia during embryogenesis and die at birth due to respiratory failure. Two recent studies have reported contradictory results regarding the necessity for GR expression in specific lung germ layers during respiratory maturation. We further investigate in detail the lung phenotype in mice with a conditional deletion of GR in the endothelium, mesenchyme, and lung epithelium. We show that loss of GR in the mesenchyme alone produces a retarded lung phenotype almost identical to that of germline GR^{-/-} mice, including severe postnatal lethality and lung cell hyperplasia. Loss of GR in lung epithelial cells and the endothelium had no gross effect on survival or lung morphology, but loss of epithelial GR caused increased cell proliferation in multiple compartments. Mesenchymal GR loss also produced increased epithelial cell proliferation, implying the existence of GC-regulated germ layer cross-talk. Protein levels of GR-mediated cell cycle regulators, including the cyclin-dependent kinase inhibitor p21^{CIP1} and the growth factor midkine, were unaffected by mesenchymal GR deletion, yet expression of the extracellular matrix proteoglycan versican was up-regulated in the distal lung on loss of mesenchymal GR. These results show that GR-mediated signaling from the mesenchyme regulates respiratory maturation and ultimately survival at birth and that a key GR-repressed transcriptional target in lung mesenchymal cells is versican.

A pro-inflammatory T cell phenotype in women with gestational diabetes

Yi Xian Chan¹, Mohammad Bakhtyari¹, Umamainthan Palendira², Patrick Bertolino², Yuk Fun Chan¹, Monika Fazekas³, Bobby Chan¹, Chris White¹, Frederic Sierro², Sue Mei Lau¹

1. Prince of Wales Hospital, Randwick, NSW, Australia

2. The Centenary Institute, Newtown, NSW, Australia

3. St Vincents Hospital, Darlinghurst, NSW, Australia

Pregnancy is a state of immune tolerance that prevents maternal rejection of the fetus. Type 2 diabetes and obesity are associated with activation of the innate and adaptive immune system, with a low ratio of T regulatory (Treg) cells (immunomodulatory) to Th17 cells (proinflammatory). Alterations in T cell subsets have not been clearly elucidated in gestational diabetes (GDM) and previous studies have not employed weight-matched controls. We hypothesise that GDM is associated with a decreased immunoregulatory and an increased proinflammatory T cell phenotype compared to normoglycemic women with similar BMI.

AIM: To examine peripheral blood CD4 T cell subsets in women with GDM compared to normoglycemic women with similar BMI.

METHODS: Blood was collected at 36 weeks gestation in women with and without GDM in our antenatal clinic. Exclusion criteria included multiple pregnancy, preeclampsia/hypertension, immunosuppressive medication and autoimmune disease. Controls were matched for age and BMI. Using 9-colour flow cytometry, we compared the frequencies of circulating CD4(+) Th1, Th2, Th17 and Treg cells.

RESULTS: There were 15 GDM and 13 control women (prepregnancy BMI 25.6±6.4 vs 25.1±6.3kg/m² p=0.99). GDM women had a lower Treg:Th17 ratio (1.17±0.51 vs 1.81±0.96, p=0.03). Tregs were non significantly lower, and Th17 cells were non significantly higher in GDM. Pooling all women, there was a positive correlation between BMI and Th1 cell counts (r²=0.26, p=0.006) and a negative correlation with BMI and naïve Tregs (% of total Tregs)(r²=0.18, p=0.02), while the proportions of these, per se, were not different in GDM women. (Data expressed as means±SD).

CONCLUSIONS: These results suggest that increased maternal immune tolerance in pregnancy is less pronounced in GDM women compared to BMI-matched controls. While increasing BMI was associated with a proinflammatory CD4 T cell phenotype, the changes associated with GDM did not appear to be solely attributable to increased BMI.

Glandular epithelial AR regulates androgen mediated androgen effects on the uterine growth

Jaesung P Choi¹, Kate Skulte¹, Yu Zheng¹, David J Handelsman¹, Ulla Simanainen¹

1. ANZAC research institute, Concord, NSW, Australia

Estrogens are the major contributor to uterine development but androgens, acting via the androgen receptor (AR), can also promote uterine growth. We demonstrated that global AR inactivation in mice (ARKO) reduces uterine growth [1] and now test the hypothesis that androgens acting via AR can fully support uterine growth with the growth promoting effect of androgens mediated via AR in uterine endometrial glands.

To test our hypothesis, we used global ARKO and glandular epithelial ARKO (utARKO) mouse models to investigate uterine development (20 weeks) compared with wild-type (WT) females. Additionally, these mice were ovariectomised and treated with testosterone (OVX+T), DHT (OVX+DHT) or empty implant (OVX+empty).

Uterine weights in intact [$-96\pm 9\text{mg}$ (mean \pm SE)] and OVX+empty ($-12\pm 2\text{mg}$) groups were not affected by genotype. Uterine growth following OVX+T was modified by AR inactivation. No regrowth was observed in ARKO [$14\pm 1\text{mg}$], while the uterine weight in utARKO [$57\pm 3\text{mg}$; $n\geq 8$] was significantly ($p<0.05$) increased compared to ARKO but significantly reduced compared to WT [$95\pm 10\text{mg}$] that had full uterine regrowth. Histomorphologically, both the endometrial and myometrial areas were significantly ($p<0.05$) reduced in utARKO (0.4 ± 0.1 and $0.7\pm 0.1\text{mm}^2$ respectively; $n\geq 5$) compared to WT (0.7 ± 0.1 and $1.5\pm 0.5\text{mm}^2$; $n\geq 5$), suggesting that inactivation of glandular epithelial AR modified uterine growth. ARKO uteri were undeveloped demonstrating that the uterine regrowth following T replacement is AR mediated.

Furthermore, WT(OVX+DHT) mice ($86\pm 16\text{mg}$; $n\geq 3$) achieved similar uterine weights as WT(OVX+T) suggesting that androgens alone can promote full uterine regrowth and does not require estradiol.

In conclusion, androgens acting solely via AR can support full uterine growth. Furthermore, glandular epithelial AR mediates uterine (including myometrial) growth via AR mediated androgen actions. Thus further investigation of the role of AR and cross-talk involving AR expression in different type of cells is warranted. This could lead to better biomarkers and more effective novel treatment of uterine disorders.

1. Walters KA, McTavish KJ, Seneviratne MG, Jimenez M, McMahon AC, Allan CM, Salamonsen LA, Handelsman DJ: Subfertile female androgen receptor knockout mice exhibit defects in neuroendocrine signaling, intraovarian function, and uterine development but not uterine function. *Endocrinology* 2009, 150(7):3274-3282.

21

Differences in cortisol response to adrenocorticotropin (ACTH) reflect an innate alteration of the set-point of the hypothalamo-pituitary-adrenal (HPA) axis that is maternally inherited

Sakda D Hewagalamulage¹, Iain J Clarke¹, Belinda A Henry¹

1. Department of Physiology, Monash University, Building 13F, Vic 3800, Australia

Within any population, the cortisol response to ACTH covers a considerable range. High responders (HR) exhibit a heightened cortisol secretory response to stress or ACTH, whereas this response is attenuated in low responders (LR). We administered $0.2\mu\text{g/kg}$ ACTH (i.v.) to 100 female sheep and selected animals at the 10% extremes, to represent HR and LR. These animals show metabolic and behavioural differences that lead to an obesity prone phenotype in HR¹. In the present study we aimed to characterise the HPA axis in HR and LR and to identify factors that underlie their differing cortisol responses to ACTH.

Hypothalamic, pituitary and adrenal glands were collected from non-stressed HR and LR ewes ($n=4$). Expression of genes for corticotropin-releasing factor (CRF), arginine vasopressin (AVP), glucocorticoid receptor (GR) and mineralocorticoid receptor (MR) were measured by in situ hybridisation in the paraventricular nucleus of the hypothalamus and pro-opiomelanocortin (POMC) gene expression was measured in the pituitary. Expression of CRF ($P<0.05$), AVP ($P<0.01$) and POMC ($P<0.05$) was higher in HR, with no differences in GR and MR expression. In adrenals, PCR analysis showed that expression of the ACTH receptor and a range of synthetic enzymes in the steroidogenic pathway were similar in HR and LR ($n=5$). Adrenal weights, the cortex:medulla ratio and adrenal cortisol content were similar in LR and HR. To determine whether cortisol responsiveness is heritable, HR and LR ($n=5$) ewes were mated to a single ram. Cortisol responses to ACTH were greater ($P<0.05$) in offspring of HR mothers than in those of LR mothers. In conclusion, HR and LR display innate differences in the steady-state expression of CRF, AVP and POMC, indicating a different set-point of the HPA axis in the hypothalamus and pituitary. Preliminary breeding studies indicate that these differences are maternally inherited.

1. Lee TK, Clarke IJ, St. John J, Young IR, Leury BL, Rao A, Andrews ZB, and Henry BA. High cortisol responses identify propensity for obesity that is linked to thermogenesis in skeletal muscle. *The FASEB Journal* 28: 35-44, 2014.

22

PPAR γ and XIAP as potential targets for combination treatment of ovarian granulosa cell tumours

Dilys TH Leung^{2,1}, Peter Fuller², Simon Chu²

1. School of Biomedical Sciences, Monash University, Clayton, VIC, Australia

2. MIMR-PHI Institute of Medical Research, Clayton, VIC, Australia

Ovarian granulosa cell tumours (GCT) are hormonally active cancers characterised by indolent growth and late, invasive relapse. Our research has established that several nuclear receptors, including the anti-proliferative peroxisome proliferator-activated receptor gamma (PPAR γ), are upregulated in GCT. Subsequent studies using two GCT-derived cell lines (KGN and COV434), revealed that PPAR γ activity in these cell lines is transrepressed by constitutive NF- κ B signalling. NF- κ B induces a key effector protein, X-linked inhibitor of apoptosis protein (XIAP). Small molecule inhibitors of XIAP and PPAR γ agonists have been developed as potential anti-tumour therapeutic agents. We investigated what effects XIAP inhibition and PPAR γ activation have on GCT cells. We hypothesise that XIAP antagonism sensitises GCT cells to pro-apoptotic strategies such as PPAR γ activation.

We analysed PPAR γ and XIAP expression in GCT, other ovarian cancer subtypes and normal ovarian tissues using tissue microarray and immunohistochemistry. Strong immunostaining for PPAR γ and XIAP was observed in stage 1 and recurrent GCT as well as other ovarian cancers but not in normal ovaries. Utilizing apoptosis and proliferation assays, we observed that combined PPAR γ activation and XIAP inhibition in GCT-derived cells significantly increases apoptosis, decreases cell proliferation and viability. We examined using transactivation assays, the effect of small molecule inhibition of XIAP on PPAR γ

activity. PPAR γ signalling in GCT-derived cells was restored when treated with PPAR γ agonist (rosiglitazone) and XIAP inhibitor (smac mimetic).

The overexpression of PPAR γ and XIAP in GCT warrants investigation as potential targets for anti-tumour therapy. Removal of NF- κ B transrepression of PPAR γ leads to increase apoptosis in GCT cells. Given a similar effect is observed with XIAP inhibition on PPAR γ transactivation, we are currently determining if XIAP regulates NF- κ B activity as part of a regulatory loop. This will improve understanding of the molecular mechanisms in GCT pathophysiology and enable identification of new targets for therapeutic strategies.

23

Targeting androgen stimulation with abiraterone acetate: a novel therapeutic approach in adrenocortical cancer

Julia K Prague¹, Cindy K Pon¹, Edward Kim¹, Cameron Wood², Martyn Bullock¹, Trish Dwight¹, Lyndal J Tacon³, Diana (Dindy) E Benn¹, Bruce G Robinson¹, Roderick J Clifton-Bligh¹

1. Cancer Genetics, Kolling Institute, Australia, NSW

2. Biochemistry, Royal North Shore Hospital, Sydney, NSW, Australia

3. Endocrinology, Royal North Shore Hospital, Sydney, NSW, Australia

Publish consent withheld

24

CRISP3 regulates progression from *in situ* to invasive prostatic adenocarcinoma

Marianna Volpert¹, Duangporn Jamsai¹, Rebecca D'Sylva, John Pedersen², Gail Risbridger¹, Peter McIntyre³, Luc Furic¹, Moira O'Bryan¹

1. Monash University, Clayton, VIC, Australia

2. TissuPath, Mount Waverley, VIC, Australia

3. RMIT University, Bundoora, VIC

Introduction: One of the most challenging aspects of prostate cancer diagnosis is predicting whether cancer will remain indolent or progress to invasive, aggressive and potentially lethal disease. Current markers such as PSA are unreliable and tumours requiring treatment may remain undetected while others are over-treated. CRISP3 is a member of a poorly defined family of proteins that is highly up-regulated in human prostate cancer and controversially proposed as a prognostic marker. As a major focus of my PhD, we sought to define the role of CRISP3 in the molecular pathology of prostate cancer through the generation of a *Crisp3* knockout mouse line, which was crossed onto the *Hi-MYC* mouse model of prostatic adenocarcinoma.

Results: As in the healthy human prostate, CRISP3 was not expressed in the wild type mouse prostate, but was up-regulated 800-fold in *Hi-MYC* lateral prostate tumours from 5-7 months old males. Over-expression coincided with cancer invasion in 6 of 8 *Hi-MYC*⁺*Crisp3*^{+/+} animals. In contrast, *Crisp3* deletion completely prevented the progression from carcinoma *in situ* to invasive disease (n=9). Furthermore, CRISP3 production accelerated the transition from high-grade PIN to carcinoma *in situ*, and *Crisp3* knockout decreased tumour mass as measured by c-MYC immunohistochemistry (p=0.0228).

Conclusions: We show that CRISP3 expression was required for the transition from *in situ* to invasive carcinoma in the *Hi-MYC* mouse model. These findings demonstrate for the first time that CRISP3 is pro-tumorigenic by driving prostate cancer invasiveness, making CRISP3 a plausible biomarker and therapeutic target in human prostate cancer.

41

Characterisation of a novel primate-specific 11 β -hydroxysteroid dehydrogenase called 11 β HSD1L in the ovary

Timothy J Cole¹, Daniel A Bird¹, Kuan Liew¹, Gareth G Lavery²

1. Monash University, Clayton, Vic, Australia

2. CEDAM, University of Birmingham, Birmingham, UK

Endocrine steroid hormones including estrogens, androgens, glucocorticoids and mineralocorticoids play clinically important and specific regulatory roles in human development, growth, metabolism, reproduction and brain function. The 11- β hydroxysteroid dehydrogenase enzymes have key roles in the pre-receptor modulation of glucocorticoids, modifications that directly regulate blood pressure, fluid and electrolyte homeostasis, as well as modulating metabolic and brain function. A recent analysis of the human genome has located a novel largely uncharacterized 11 β HSD-like gene on human chromosome 19q13.3, a distinct gene from the very well characterized 11 β HSD1 (human chromosome 1q32-q41) and 11 β HSD2 (human chromosome 16q22) genes. Strikingly, a search in other mammalian genomes has revealed the complete absence of this third 11 β HSD gene from the mouse, rat and rabbit genomes. This human 11- β -hydroxysteroid dehydrogenase 1-like protein (HSD11 β 1L) gene and its encoded enzyme are completely uncharacterized for substrate specificity and detailed cellular expression pattern. The human HSD11 β 1L gene is encoded by 9 exons and analysis of EST library transcripts indicates the use of two alternate ATG start-sites in exons 2 & 3, and alternative RNA splicing in exon 9. HSD11 β 1L shares a 40% amino acid sequence homology with 11 β HSD1 and the strong conservation of the NAD⁺/NADP⁺ nucleotide binding and dehydrogenase/reductase catalytic site domains.. Preliminary data demonstrates high expression of this enzyme in two human

and non-human primate tissues, the ovary and brain. The endogenous substrate of this enzyme is unknown but we intriguingly show that it is unlikely to be cortisol or cortisone.

42

The role of 11 β -HSD1 in the regulation of the HPA axis in chronic inflammatory arthritis

Janko Sattler¹, Jinwen Tu¹, Shihani Stoner¹, Jingbao Li¹, Frank Buttgerit², Markus J Seibel¹, Hong Zhou¹, Mark S Cooper¹

1. ANZAC Research Institute, Concord, NSW, Australia

2. Charite University Hospital, Berlin

Reduced production of ACTH in response to chronic inflammation has been described in rheumatoid arthritis (RA) but the basis for this remains unclear. We have previously demonstrated that in RA extra-adrenal generation of cortisol is increased via upregulation of expression of 11 β -hydroxysteroid dehydrogenase type 1 (11 β -HSD1) in inflamed tissues. This enzyme converts inactive cortisone to active cortisol. 11 β -HSD1 is also expressed in the hypothalamus and pituitary where it regulates HPA axis function. We therefore hypothesised that increased central expression of 11 β -HSD1 during chronic inflammation could explain the decreased production of ACTH. This hypothesis was examined in the K/BxN model of chronic inflammatory arthritis.

K/BxN transgenic mice developed arthritis at 4-5 weeks of age and were sacrificed at 8 weeks. Wild Type (WT) non-arthritic littermates were used as controls. Hypothalamic and pituitary tissues were isolated along with other brain regions. Expression of 11 β -HSD1, GR α , MR, and POMC was examined by quantitative RT-PCR and immunohistochemistry.

11 β -HSD1, GR α and MR were expressed in the pituitary and hypothalamus. Mice with chronic inflammation showed a significantly lower expression of 11 β -HSD1 and GR α mRNA in pituitary (50.5 \pm 9.5% less than WT, $p=0.008$; 51.6 \pm 6.8%, $p=0.002$ respectively). By contrast there was no difference in 11 β -HSD1 and GR α expression within the hypothalamus by RT-PCR or immunohistochemistry. Levels of 11 β -HSD1, GR α and MR did not differ between arthritis mice and controls at any other brain region (hippocampus, cortex, cerebellum). Despite lower 11 β -HSD1 and GR α expression (and thus lower glucocorticoid negative feedback), pituitary POMC/ACTH mRNA levels were significantly lower in arthritic mice than WT (36.5 \pm 4.7%, $p=0.03$).

Rather than being increased, 11 β -HSD1 expression in the pituitary gland was suppressed. Despite this the expression of ACTH was low in keeping with reduced activity of the HPA axis. These data indicate that failure of HPA axis activation in chronic arthritis is not due to increased central 11 β -HSD1 expression.

43

The identification of novel mineralocorticoid receptor coregulators

Jun Yang¹, Peter J Fuller¹, Donald P McDonnell², James Morgan¹, Colin Clyne¹, Morag J Young¹

1. Prince Henry's Institute of Medical Research, Clayton, VIC, Australia

2. Pharmacology and Cancer Biology, Duke University Medical Centre, Durham, North Carolina, USA

The mineralocorticoid receptor (MR) is a nuclear receptor that plays a central role in salt and water homeostasis via the kidney; however, inappropriate activation of the MR in the heart can lead to cardiac fibrosis and failure. The molecular mechanisms for tissue-specific MR activation are poorly understood. Coregulators have been implicated as they are critical for nuclear receptor-mediated gene expression and are diverse in their structure, tissue distribution and function. Unfortunately, there is only a limited repertoire of MR coregulators described. To address this issue, we used phage display to screen for novel MR coregulators.

Our initial studies using M13 phage display identified a consensus motif amongst MR-interacting peptides, MPxLxxLL [1]. Gemin4-associated protein 4 (Gemin4) contains this motif. In assays performed in two different cell lines, Gemin4 repressed agonist-induced MR transactivation in a cell-specific manner. Furthermore, overexpression of Gemin4 significantly decreased, while knockdown of Gemin4 increased, the mRNA expression of specific endogenous MR target genes. A physical interaction between Gemin4 and MR is suggested by their nuclear co-localisation upon agonist treatment.

We then used T7 phage display to screen tissue-specific cDNA libraries and identified 30 MR binding peptides. Three were chosen for further characterization based on their nuclear localization, interaction with other MR-interacting proteins, and/or known status as a nuclear receptor coregulator. Eukaryotic elongation factor 1A1 (EEF1A1), structure-specific recognition protein 1 (SSRP1), and x-ray repair cross-complementing protein 6 (XRCC6) modulated MR-mediated transcription in a ligand-, cell- and/or promoter-specific manner, and co-localized with the MR upon agonist treatment when imaged using immunofluorescence microscopy.

These results highlight the utility of phage display for rapid and sensitive screening of MR binding proteins, and suggest that Gemin4, EEF1A1, SSRP1 and XRCC6 act as novel MR coregulators whose activity is dependent on ligand, cellular context and target gene promoter.

44

The role of androgens in cutaneous wound healing: impact of local drug delivery

Kenny Cheer¹, Francia Garces Suarez¹, Brian Lesmana¹, Ulla Simanainen¹, David Handelsman¹, Peter Maitz¹, Yiwei Wang¹

1. Anzac Research Institute, Concord, NSW, Australia

Androgens retard wound healing in males, but their role in female wound healing has not been established. To explore the AR-mediated androgen actions in male and female wound healing, we utilized the global, androgen insensitive AR knockout (ARKO) mouse model, with a mutated AR deleting the second zinc finger to disrupt DNA binding and transcriptional activation.

Cutaneous (excision) wounds of 4cm² in size were surgically created on the dorsal area of male and female wild type (WT) and ARKO mice. Wound healing rate was measured using Visitrak Wound Measurement Grid (Smith and Nephew, Australia) over 21 days and skin biopsies of the wound area were harvested by skin excision under anaesthesia on days 3, 5, 7, 14 and 21 for histological, immunohistochemical and molecular analysis. The results showed that AR inactivation significantly enhanced wound healing rate in male mice by increasing re-epithelialization and collagen deposition. The enhanced wound healing was not due to faster contraction (wound healing in mice) in ARKO males as demonstrated using a silicone splint to stop contraction. Increased wound healing in ARKO males was supported by significantly increased proliferation of ARKO compared to WT fibroblasts. In contrast, AR inactivation had no effect on wound healing rate in female mice that could be due to lower AR expression and/or endogenous androgen levels or greater role for estrogens. To exploit local anti-androgen effects in wound healing while minimizing off-target systemic effects, we developed a novel electrospun polycaprolactone (PCL) scaffold wound dressing materials for sustained local anti-androgen delivery. Using the anti-androgen hydroxyflutamide (HF) at 1, 5 and 10 mg/ml in PCL scaffolds with controlled HF delivery over 21 days significantly enhanced in vitro cell proliferation of human dermal fibroblasts (HDFs) and human keratinocytes (HKCs), and promoted in vivo wound healing in mice.

45

Neuronal androgen receptor regulation of muscle mass

Kesha Rana¹, Michele V Clarke¹, Rachel A Davey¹, Jeffrey D Zajac¹

1. Department of Medicine, University of Melbourne, Austin Health, Heidelberg, Victoria, Australia

We have previously shown that global deletion of the androgen receptor (AR) in mice results in a 15-22% decrease in hind-limb muscle mass compared to wildtype (WT), while the reduction in muscle mass in mice in which the AR is only deleted in muscle is much lower at 0-6%. These results suggest that there is another major target of androgen action in the regulation of muscle mass. To investigate the role of androgens acting via the AR in neurons on muscle mass and strength, we generated a neuron-specific AR knockout (KO) mouse model, in which exon 3 of the AR gene has been deleted from neurons only by breeding floxed AR mice with CamKII-Cre mice. Preliminary data shows that 6 week old neuron-specific ARKO male mice have a 15% decrease in gastrocnemius muscle mass compared to WT littermates (n≥5 mice/group, p<0.01). Total body mass of neuron-specific ARKO mice is decreased by 8% compared to WT (n≥5 mice/group, p<0.05). These data provide evidence for a role of androgens to increase muscle mass, at least in part, via neurons.

46

Postnatal germ cell development during minipuberty in the mouse does not require androgen: implications for managing cryptorchidism

Ruili Li^{1,2}, Amanda Vannitamby¹, Jorien Meijer³, Bridget R Southwell^{1,2}, John M Hutson^{1,4,2}

1.F. Douglas Stephens Surgical Research Laboratory, Murdoch Childrens Research Institute, Parkville,, Victoria, Australia

2. Department of Paediatrics, University of Melbourne, Parkville,, Victoria, Australia

3. Medical School, , University of Groningen, Groningen, The Netherlands

4. Urology Department, Royal Children's Hospital, Parkville,, Victoria, Australia

Background: Undescended testis (UDT) causes an increased risk of infertility and malignancy resulting from aberrant germ cell (GC) development. Androgens are proposed to control early GC development.

Objective: To assess the effect of androgen on perinatal GC development in mice.

Material and Methods: Testes from androgen receptor knockout (ARKO) mice and wildtype (WT) littermates (n=3/group) were collected at embryonic (E) day 17 (day of vaginal plug = E0), postnatal (P) days P0 (birth), P2, P4, P6, P8 and P10 for immunohistochemistry. Antibodies against mouse VASA homologue (MVH, GC marker), anti-Müllerian hormone (AMH, Sertoli cell marker), Ki-67 (proliferating cell marker), and DAPI (cell nuclei) were used and visualised by confocal microscopy. The numbers of GC/tubule, GC on the tubular basement membrane (GC/BM), Sertoli cells/tubule and the percentage of proliferating GC (Ki67+)/tubule and GC (Ki67+)/BM were counted. Data were analysed using t-test with software GraphPad Prism 5.02.

Results: In WT testes, GC/tubule decreased from E17 to P2, and then increased normally up to P10. Number of MVH + GC/tubule and GC on the BM were similar in ARKO and WT testes (p>0.05) at all time points. In addition, the percentages of proliferating GC (Ki-67+)/tubule and proliferating GC (Ki67+)/BM were similar at all time points (p>0.05) between ARKO and WT testes.

Conclusion: These results show that androgen does not control normal proliferation and migration of gonocytes from the centre of testicular tubules to BM, and putative transformation into type A spermatogonia, between birth and day 10 in mice. As this time interval spans normal 'minipuberty', which occurs between day 2 and day 6 in mice, it suggests that during murine minipuberty a novel, non-androgenic factor may stimulate early GC development. Identifying such a non-androgenic factor might be important for future medical therapy to improve fertility potential of boys with UDT and undergoing orchidopexy.

A new pheochromocytoma syndrome: extending the phenotype associated with MAX mutations

Gregory Hockings^{1,2}, Aideen McInerney-Leo³, Nicholas Hockings¹, Jason Hockings¹, Jessica Harris³, Sofia Velosa^{1,2}, Anthony Gill⁴, Rory Clifton-Bligh⁴, Emma Duncan^{2,3,5}

1. Endocrinology Unit, Greenslopes Private Hospital, Brisbane, Qld, Australia

2. School of Medicine, University of Queensland, Brisbane, Qld, Australia

3. The Diamantina Institute, University of Queensland, Brisbane, Qld, Australia

4. Royal North Shore Hospital, Sydney, NSW, Australia

5. Department of Endocrinology, Royal Brisbane & Women's Hospital, Brisbane, Qld, Australia

Pheochromocytomas (PCC) and paragangliomas (PGL) are neuroendocrine tumours derived from neural crest cells. PCC/PGL are extremely heritable: 30-40% of cases have a germline mutation in one of 13+ genes. Several of these genes are associated with syndromes (e.g. multiple endocrine neoplasia type 2).

We recruited a three-generation kindred with multiple cases of PCC. The father of the proband died suddenly. Of his five children (all males), the proband and two others were affected. One brother with metastatic PCC also has recurrent acromegaly 40 years after initial presentation, at which time acromegaly resolved following pituitary surgery performed shortly after adrenalectomies. Two sons of the other brother had paravertebral ganglioneuroma and abdominal neuroblastoma respectively. This brother showed brown fat uptake on MIBG.

Whole exome sequencing on DNA from peripheral blood monocytes from the proband identified a novel heterozygous mutation in *MAX* (MYC-associated factor X gene), segregating perfectly with disease in the family. PCC immunohistochemistry demonstrated completely negative MAX1 staining, supporting its pathogenic role. The other tumours showed: a) MAX1-negative staining in most neuroblastoma cells, supporting a pathogenic role of *MAX*; b) negative staining in ganglioneuroma ganglion cells but variable staining in Schwannian stromal cells. The resected pituitary tissue was unavailable.

This is the 4th family world-wide with PCC from germline *MAX* mutations, and the first with other neural crest tumours. *MAX* is a tumour suppressor gene affecting the MXD1 protein family which regulates cell proliferation and differentiation. Consistent with previous reports, we observed paternal transmission; however, no affected woman has had children. Whether acromegaly is from a pituitary lesion – and, if so, whether immunohistochemistry shows MAX1 deficiency – or GHRH co-secretion is currently unclear. However, if the former is true, this family has a novel MEN syndrome. Either way, this family extends the phenotype associated with germline *MAX* mutations.

Next generation sequencing in suspected familial pituitary tumour syndromes: pilot study results and clinical translation

Sunita MC De Sousa^{2,1}, Mark J McCabe^{1,3}, Mark J Cowley³, Jiang Tao³, Kerith-Rae Dias³, Tanya Thompson¹, Marcel E Dinger³, Ann I McCormack^{2,1}

1. Hormones and Cancer Group, Cancer Division, Garvan Institute of Medical Research, Sydney, NSW, Australia

2. Department of Endocrinology, St Vincent's Hospital, Darlinghurst, NSW, Australia

3. Kinghorn Centre for Clinical Genomics, Garvan Institute of Medical Research, Darlinghurst, NSW, Australia

Background: Familial pituitary tumour syndromes account for approximately 5% of all pituitary tumours. The recent discovery of new players in pituitary tumorigenesis such as *AIP* and the *SDHx* genes together with increasing clinical experience with next generation sequencing (NGS) may unveil greater prevalence and better inform patient management.

Methods: We developed a custom NGS panel (Roche/Nimblegen) containing 8 known familial pituitary tumour genes, 25 genes involved in embryonic pituitary development and 267 genes implicated in various oncogenic pathways. Subjects had pituitary tumours suspected to be familial due to presentation below the age of 40 years, another multiple endocrine neoplasia 1 (MEN1) tumour, or family history of MEN1-related neoplasia. DNA was extracted from peripheral blood leucocytes and sequenced using our 300-gene panel (Illumina HiSeq 2500 sequencing). Sanger sequencing was performed for validation. Raw data was analysed by a custom bioinformatic pipeline and variants with a population frequency <1% were considered for pathogenicity. Variants were further evaluated by *in silico* analysis, comparison with genetic databases, and wider literature reviews.

Results: Clinical and genetic data were collated for 28 subjects with qualifying conditions including prolactinomas, acromegaly, gigantism, Cushing's disease and non-functioning pituitary adenomas. NGS revealed potentially pathogenic germline mutations in seven patients, three with two rare variants, including *AIP* (p.F269F, p.A299V, p.R106C, p.R304*), *MEN1* (p.R176Q), *SDHA* (p.D38V), and *SDHB* (p.A2V).

Conclusions: NGS has a high yield of genetic variants with potential pathogenicity. Individual patients had multiple relevant variants that may interact through digenic inheritance which would have been unrecognised in single or staged gene analysis. NGS data on well-described variants can be fed back to patient and clinician to guide therapeutic decisions and family screening, whilst novel genetic findings may elucidate new contributors to pituitary tumorigenesis and lead to novel treatment options.

The natural history of non-functioning pituitary adenomas: a longitudinal volumetric evaluation

Nele Lenders¹, Anthony Russell^{1,2}, Ken Ho^{3,2}, John Prins^{1,4}, Warrick Inder^{1,2}

1. Diabetes and Endocrinology, Princess Alexandra Hospital, Woolloongabba, QLD, Australia

2. School of Medicine, University of Queensland, Brisbane, QLD, Australia

3. Centres for Health Research, Princess Alexandra Hospital, Woolloongabba, QLD, Australia

4. Mater Research Institute-University of Queensland, South Brisbane, QLD, Australia

Introduction:

Non-functioning pituitary adenomas may present without any symptomatic mass effect and minimal hormonal dysfunction. The majority of these lesions are managed conservatively with serial neuroimaging to detect those that might show significant expansion and therefore require surgery. Data on the optimal follow-up of these tumours are sparse.

Methods:

Non-functioning pituitary adenomas with serial MRIs over at least 6 months between 2003 and 2013 were identified. Patients with apoplexy, visual field defect, previous sellar surgery or radiation were excluded. Longitudinal data were collected for hormonal function and pituitary tumour volume, with measurements undertaken by a single viewer (NL).

Results:

53 non-functioning pituitary adenomas (24 macroadenomas and 29 microadenomas) were identified where the initial plan was for observation. Mean follow up was 35.2 months (range 6-73), and age was 49 years (range 17-85). Those with macroadenomas were older – 59.1 ± 3.9 vs 40.8 ± 2.7 years, $P < 0.001$. Overall, there was a significant increase in tumour volume over the follow up period ($P=0.026$), with the mean percent increase in size being $9.9 \pm 5.5\%$. A significant increase in size occurred in macroadenomas (1647 ± 221 to 1984 ± 336 mm³, $P = 0.026$) but not microadenomas (169 ± 25 to 178 ± 35 mm³, $P=0.75$). A $>20\%$ increase in size occurred in 6/24 macros compared with 2/29 micros, but this failed to reach significance. Hormonal dysfunction was present in 11/53 (21%) at baseline. New hormone axis deficiency developed in only 2 macroadenoma patients during follow-up. Seven patients (all macroadenomas) proceeded to surgery after a mean of 3.1 years (range 1-6).

Conclusions:

Non-functioning pituitary macroadenomas have a greater tendency to grow and require surgical intervention than microadenomas. Microadenomas rarely progress and could be safely reimaged at an interval of 3 years for the first follow-up scan.

Somatic mutations of FOXE1 in papillary thyroid cancer

Michael Mond¹, Martyn Bullock², Yizhou Yao¹, Roderick J Clifton-Bligh², Peter J Fuller¹, Chris Gilfillan³

1. MIMR-PHI Institute, Melbourne

2. Cancer Genetics Unit, Hormones and Cancer Group, Kolling Institute of Medical Research, Royal North Shore Hospital, Sydney

3. Eastern Clinical School and Eastern Clinical Research Unit, Monash University, Eastern Health, Box Hill

Context

The thyroid transcription factor Forkhead Box E1 (FOXE1) is part of a network of factors that help maintain thyroid differentiation via transcriptional regulation of thyroid specific genes including thyroglobulin and thyroid peroxidase (1). Germline inactivating mutations in the DNA-binding or forkhead domain (FHD) of FOXE1 result in Bamforth syndrome, characterised by thyroid agenesis, cleft palate and choanal atresia. Population-based studies have demonstrated an association of single nucleotide polymorphisms close to FOXE1 with thyroid cancer (2).

Objective

The objective of the study was to identify novel mutations in FOXE1 in papillary thyroid cancer (PTC) and to assess the effect of these mutations on protein expression and transcriptional function on FOXE1 responsive promoters.

Patients and Methods

The coding region of FOXE1 was sequenced in 120 patients with PTC and 110 patients with multinodular goitre (MNG). In vitro studies were performed to examine the protein expression and transcriptional function of wild-type and mutant FOXE1. A molecular model of the FHD of FOXE1 was generated using the SWISS-MODEL online server with the three-dimensional structure of FOXD3 as a template.

Results

Three somatic missense mutations in the FHD of FOXE1 were detected in PTC resulting in the following amino acid substitutions: P54Q, K95Q and L112F. One additional mutation was detected in MNG: G140R. Two of the PTC were clinically recurrent tumours also positive for BRAFV600E mutation while one was a BRAF mutation-negative microPTC. In vitro studies demonstrated significant impairment in transcriptional activation by all four FOXE1 mutants which was not due to differences in protein expression. Molecular modelling localised three of the mutations to highly conserved regions of the FHD.

Conclusions

We have identified novel somatic mutations of FOXE1 in PTC. Mutational inactivation of FOXE1 is an uncommon event in thyroid tumours but may contribute to thyroid carcinogenesis and dedifferentiation in concert with other oncogenic drivers.

Accuracy of pre-operative localisation of parathyroid adenoma with ultrasound and sestamibi scintigraphy in primary hyperparathyroidism – review of single centre experience.

Christopher Rowe¹, Shaun McGrath¹

1. John Hunter Hospital, Newcastle, NSW, Australia

Introduction: Accurate pre-operative localisation of parathyroid adenomas allows appropriate selection of patients for minimally invasive parathyroidectomy (MIP).

Methods: Retrospective review of patients with confirmed biochemical primary hyperparathyroidism who underwent both localisation ultrasound (performed by a single operator) and sestamibi scintigraphy (majority performed at a single practice with 99mTc-pertechnetate subtraction) over the period 2010 to 2013. Adenoma localisation was confirmed at parathyroidectomy. Conditions known to predispose to multigland hyperplasia were excluded. Results were compared to a previous audit of period 2005–2009.

Results: 139 patients were identified, with average age of 66 years. 78% were female. 62% had mild primary hyperparathyroidism (corrected calcium < 2.75mmol/L), while 8% had severe disease (calcium >3mmol/L). The sensitivity of ultrasound to detect any abnormality 'possibly consistent' with an enlarged parathyroid was 85%, with a positive predictive value (PPV) for adenoma at that location of 92%. When ultrasound imaging was considered 'highly likely' to show an adenoma, sensitivity was 70%, with a PPV of 98%. Sensitivity of scintigraphy to detect any abnormality 'possibly consistent' with parathyroid adenoma was 81%, with a positive predictive value of 97% at that site. Limiting scintigraphy results to those 'highly likely' to show parathyroid adenoma gave a sensitivity of 58%, but PPV of 100%. 92 cases had a concordant abnormality on both ultrasound and scintigraphy (sensitivity 69%) with a PPV for adenoma at that site of 100%. In this group, 69 patients underwent MIP with 67 cured. When compared to past audit data, sensitivity of both techniques improved from 67% to 85% for ultrasound and 74% to 81% for scintigraphy.

Conclusions: Parathyroid ultrasound and sestamibi scintigraphy are complementary techniques to localise parathyroid adenomas pre-operatively. Concordant abnormalities on both modalities improves confidence with patient selection for MIP. There was evidence of improvement in localisation technique over time.

Positron-Emission Tomographic (PET) imaging of progesterone receptors in breast cancer: developing a predictive biomarker for tumor responsiveness to endocrine therapies

John Katzenellenbogen¹, Ruby Szeman Chan², Amy Fowler³, Julie Allen², Dong Zhou², Carmen Dence², Terry Sharp², Nicole Fettig²

1. University of Illinois at Urbana-Champaign, Urbana, IL, United States

2. Washington University, St. Louis, MO, US

3. University of Wisconsin, Madison, WI, USA

Background/Purpose: Measurement of estrogen receptor (ER) and progesterone receptor (PR) in breast cancer by immunohistochemistry (IHC) is routinely used for prognosis and prediction of benefit from endocrine therapies. Both receptors can be assayed non-invasively by positron emission tomography (PET). ER-PET using 16 α -[¹⁸F]fluoroestradiol (FES) has been used to predict response to endocrine therapies and evaluate the pharmacodynamics of ER antagonists. Sequential PET imaging with 2-[¹⁸F]fluoro-2-deoxyglucose (FDG), before and after 1 week of tamoxifen or 1 day of estradiol, has proven predictive of patient response to endocrine therapies. Here, we investigate in murine models of endocrine-sensitive and resistant mammary cancer whether longitudinal functional PET imaging of PR with [¹⁸F]fluoro-furanyl-norprogesterone (FFNP) would provide a predictive measure of response to endocrine therapies that is more rapid and sensitive than ER-PET or sequential FDG-PET.

Methods: FDG, FES and FFNP uptake in murine mammary tumors was quantified serially using microPET imaging before or on days 3 and 4 after ovariectomy. Tumor PR levels were assayed independently by IHC.

Results: The levels of FES and FDG tumor uptake remained unchanged in endocrine-sensitive tumors after ovariectomy compared to those at pre-treatment. By contrast, estrogen deprivation therapy led to a reduction in PR expression (by IHC) and FFNP uptake in endocrine-sensitive tumors, but not in endocrine-resistant tumors, as early as 3 days post-treatment. Unlabeled PR ligand R5020 blocked FFNP tumor uptake, indicating that uptake was due to binding by PR.

Conclusion: Reduction in FFNP tumor uptake, measured conveniently and non-invasively by PET, predicts sensitivity to estrogen deprivation therapy and is more sensitive than FES-PET and FDG-PET. Therefore, longitudinal noninvasive PET imaging using FFNP should be evaluated as a robust and effective approach to predict tumor responsiveness of human breast tumors to endocrine treatments.

(Supported by NIH R01CA025836 and U01CA141541)

The effects of antenatal stress in the Spiny Mouse: a new animal model in which to study programming and protection?

Tracey Quinn^{1,2}, Udani Ratnayake³, Hayley Dickinson^{4,2}, David W Walker^{4,2}

1. Monash Institute of Medical Research, Clayton, VIC, Australia

2. The Ritchie Centre, MIMR-PHI Institute, Melbourne, VIC, Australia

3. The Florey Institute of Neuroscience and Mental Health, University of Melbourne, Melbourne, VIC, Australia

4. Department of Obstetrics & Gynaecology, Monash University, Melbourne, Victoria, Australia

Introduction: Epidemiological studies show a link between prenatal exposure to stress or infections and the subsequent development of behavioural pathologies such as schizophrenia. Antenatal stress results in elevation of maternal plasma glucocorticoids, disturbs the development of the fetal hypothalamic-pituitary-adrenal axis, and steroidogenic activity of the adrenal cortex. The long-term effects on adrenal steroidogenesis and ensuing function have not been elucidated. We recently reported fetal adrenal production of dehydroepiandrosterone (DHEA) in the spiny mouse (*Acomys cahirinus*)¹. We therefore determined the effect of brief maternal exposure to stress at mid-pregnancy on offspring brain, behavior and adrenal function. Methods: Pregnant spiny mice were treated with dexamethasone (DEX; 60 h; 125 µg/kg) or saline by osmotic minipump, or polyribinosonic-polyriboctidilic acid (Poly I:C; single injection; 0.5mg/kg) at day 20 of gestation (0.5 term). Expression of steroidogenic acute regulatory protein (StAR), 3β-hydroxysteroid dehydrogenase (3βHSD), 17-hydroxylase and 17-20lyase (p450c17), and cytochrome b5 (cytb5) were determined by immunohistochemistry (IHC) in adrenal glands at 100dPN (post natal age). DHEA, testosterone, and cortisol were measured by radioimmunoassay. Animals injected with Poly I:C, or saline at 20 days gestation were culled for fetal cytokine mRNA analysis (24h after exposure to Poly I:C) or delivered their offspring for behavioural assessment between 20 and 80 dPN before tissue collection at 100dPN. All brains were analysed using IHC for microglia activation (Iba1), neuronal migration (Reelin) and astrocytes (GFAP). Results: Male adult offspring from mothers treated with DEX at mid gestation showed significantly reduced expression of StAR, p450c17, and cytb5 in the adrenal zona reticularis. Plasma DHEA was significantly decreased in male offspring from DEX-treated dams; plasma cortisol was unaffected in either sex, so that the DHEA:cortisol ratio was significantly lower in males only. In contrast, plasma testosterone concentrations were significantly increased in male offspring from DEX-treated vs saline treated dams. Poly I:C treatment at mid-pregnancy did not affect plasma cortisol concentrations in adult offspring, but did result in decreased mRNA expression of inflammatory cytokines in the fetal brain, suggesting activation of the maternal/fetal HPA axis. Poly I:C treatment significantly impaired non-spatial memory, learning tasks, and spontaneous motor activity in adult offspring. Brain histology revealed significant decreases in reelin, increased GFAP expression, and increased numbers of activated microglia, specifically in the hippocampus. Conclusion: These results show that even a brief period of stress/infection at mid-gestation can result in long-term and pronounced endocrine, neurological and behavioural abnormalities in adult offspring, all considered relevant to psychiatric disease. These changes may occur in response to an interaction between the immune system and the HPA axis, quite possibly mediated by an increase in maternal glucocorticoids and alterations in the DHEA-to-cortisol ratio, suggesting a mechanism by which maternal insults contribute to the risk of neurodevelopmental disorders such as schizophrenia in humans.

1. Quinn et al, Endocrinology 154:1190-201

55

Manipulating placental vasculature to improve fetal health outcomes

Caitlin Wyrwoll¹

1. The University of Western Australia, Nedlands, WA, Australia

Fetal glucocorticoid exposure is a key mechanism involved in adverse programming outcomes in the adult. Impairment of fetal growth has predominantly been attributed to direct effects of glucocorticoids on the fetus, however glucocorticoid-mediated fetal growth retardation is likely also to relate to disturbances in placental growth and function. Regulation of fetal glucocorticoid exposure is achieved by the placental glucocorticoid barrier, which involves glucocorticoid inactivation within the labyrinth zone of the murine placenta by 11β-hydroxysteroid dehydrogenase type 2 (11β-HSD2). A global knockout of 11β-HSD2 in the mouse has a dramatic effect on the placenta with absence of 11β-HSD2 (11β-HSD2^{-/-}) altering placental nutrient transport (namely glucose and amino acids) in comparison to wildtype placentas. This altered placental function is associated with reduced capillary networks and accompanying declines in angiogenic factors. Furthermore, the compromised placental vascular development of 11β-HSD2^{-/-} fetuses is associated with compromised placental and umbilical cord haemodynamics, as assessed by high resolution ultrasound. In addition, measures of cardiac function by ultrasound revealed 11β-HSD2^{-/-} fetal heart function to be impaired. Interestingly, administration of pravastatin (which is known to result in marked restoration of placental vasculogenesis in mouse models of preeclampsia) throughout gestation increases placental weight and ameliorates the aberrant umbilical and placental cord flow of 11β-HSD2^{-/-} fetuses. Fetal weight and cardiac parameters of 11β-HSD2^{-/-} fetuses are also partially normalised due to pravastatin treatment. This work highlights the potential for the placenta to be viewed as a therapeutic target to improve fetal health outcomes. It also reinforces that adverse programming effects of glucocorticoids are not exclusively due to direct actions on the fetus but also a consequence of changes in placental development and function.

60

Metformin for the prevention of insulin resistance in obese women at midlife.

Roisin Worsley¹, Robin J Bell¹, Penelope Robinson¹, Fiona Jane¹, Susan R Davis¹

1. Women's Health Research Program, Monash University, Melbourne, VIC, Australia

Aim: Evidence to support the use of metformin to treat insulin resistance (IR) and prevent progression to type 2 diabetes mellitus (T2DM) in its preclinical phase is lacking. The aim of this study was to determine whether metformin would reduce IR, weight and waist circumference and improve lipids and lower sex hormone binding globulin (SHBG) in obese, but not morbidly obese, euglycaemic women. Methods: Obese women (body mass index (BMI) >30 and < 40 kg/m² and/or waist circumference >88cm), aged 35-65 were randomised (1:1) to metformin 850mg, or identical placebo, twice daily for 26 weeks. The primary study outcome was the change in IR determined by the homeostasis model of assessment (HOMA-IR). Secondary outcomes included fasting insulin, glucose, weight, waist circumference and BMI. The trial was registered on ACTRN12610000836033.

Results: 125 women were screened, 117 enrolled and 100 women, mean age 53 years, were included in the primary intention to treat analysis. Metformin treatment resulted in statistically significant between group difference in the change in HOMA-IR (mean change -0.38; 95% CI of mean -0.54 to -0.22, vs placebo -0.13; 95% CI -0.50 to 0.24, $p=0.018$) and BMI (mean change -1.00 kg/m²; 95% CI of mean -1.37 to -0.62 vs placebo 0.00; 95% CI -0.29 to 0.28, $p<0.001$). Statistically significant reductions in HbA1C ($p=0.008$) and fasting insulin ($p=0.03$) and a borderline increase in HDL-C ($p=0.07$) were also observed for metformin, compared with placebo. No effects were seen for waist circumference, fasting glucose, other lipids or SHBG.

Conclusion: Treatment of euglycemic obese middle-aged women with metformin 1700 mg/ day resulted in improved IR and weight loss compared with placebo. Our findings support the use of metformin in obese, but not morbidly obese, middle-aged women.

This study was supported by the Bupa Health Foundation, Australia.

Insulin sensitivity in women with Polycystic Ovary Syndrome: A systematic review and meta-analysis

Samantha Cassar^{1,2}, Marie L Misso³, Will G Hopkins², Christopher S Shaw², Nigel K Stepto^{1,2}, Helena J Teede^{4,3}

1. College of Sport and Exercise Science, Victoria University, Footscray, Victoria, Australia

2. Institute of Sport and Active Living, Victoria University, Footscray, Victoria, Australia

3. Monash Centre for Health Research and Implementation, School of Public Health and Preventive Medicine, Monash University, Melbourne, Victoria, Australia

4. Diabetes and Vascular Medicine Unit, Monash Health, Clayton, Victoria, Australia

Polycystic ovary syndrome (PCOS) is a common and complex condition underpinned by insulin resistance. Yet the aetiology of PCOS remain elusive and the interaction of insulin resistance with various intrinsic and extrinsic factors are not well understood. Therefore, we aimed to undertake a systematic review and meta-analysis to generate novel data addressing the question: is insulin resistance intrinsic to PCOS? Specifically, we aimed to investigate the effects of body mass index (BMI), age and diagnostic criteria on insulin sensitivity measured by the gold standard euglycaemic-hyperinsulinaemic clamp in women with and without PCOS. The systematic review was conducted according to the principles of the Cochrane Collaboration and a series of meta-analyses using mixed modelling and standardised magnitude based inferences was performed. The methodology used adheres to the PRISMA checklist. The search returned 4,371 articles; of these, 25 articles met the inclusion criteria and were included in the meta-analysis. Overall insulin sensitivity was lower in women with PCOS compared to controls (27%, large effect). This lower insulin sensitivity was independent of BMI but BMI also independently exacerbated insulin sensitivity in PCOS and had a greater impact than it did in controls. Age also adversely influenced insulin sensitivity and had a greater impact in women with PCOS, but the effect of age became negligible when adjusted for BMI and diagnostic criteria. PCOS diagnostic criteria had a small effect on insulin sensitivity, with women diagnosed with the original National Institute of Health criteria demonstrating lower insulin sensitivity compared to women diagnosed with the Rotterdam criteria. We extend prior knowledge by confirming that insulin resistance is intrinsic to PCOS and highlight the potential importance of targeted treatment, including exercise and insulin sensitising medication, to assist in the management of PCOS.

Early insulin signalling events in skeletal muscle from women with PCOS: impact of exercise

Nigel K Stepto¹, Danielle Hiam¹, Benedict J Canny², Samantha Cassar¹, Cherycer Harrison³, Anju Joham³, Rebecca Goldstein³, Samantha K Hutchison³, Juleen R Zierath⁴, Helena Teede³

1. Institute of Sport Exercise and Active Living, Victoria University, Melbourne, VIC, Australia

2. Department of Physiology, Monash University, Clayton, VIC

3. Monash Centre for Health Research Implementation, Monash University and Monash Health, Clayton, VIC, Australia

4. Karolinska Institutet, Stockholm, Sweden

Polycystic ovary syndrome (PCOS) is the most common endocrinopathy, affecting up to 1 in 5 young women. PCOS is a multifaceted disorder with metabolic and reproductive implications. Metabolic implications include obesity, insulin resistance, gestational diabetes, type 2 diabetes mellitus and risk factors for cardiovascular disease. Recently we have demonstrated that all women with PCOS have insulin resistance that cannot be explained by BMI or visceral fat alone (1). Furthermore, we have demonstrated that exercise training in PCOS enhances insulin sensitivity (2-3). While the mechanisms of insulin resistance in PCOS remain elusive, we hypothesised that the mechanisms responsible for the insulin resistance in PCOS may indeed be the early insulin signalling events in the skeletal muscle. Therefore, using euglycaemic hyperinsulinaemic clamp studies (1) and obtained muscle biopsies before and 40 minutes into the clamp to compare early insulin signalling events (immunoblotting) between lean and overweight women with and without PCOS ($n=60$), with a subset of the overweight women with and without PCOS ($n=16$) repeating the clamps and biopsies after 12 weeks of aerobic training. Here we show reduced responses in phosphorylation (normalised by prevailing insulin) of the insulin receptor ($P<0.001$), the p85 subunit of P-13K ($P<0.001$), and serine phosphorylation of IRS-1 ($P<0.001$) and Akt ($P<0.001$) in PCOS are mediated by obesity women, however these defects were not normalised by exercise in overweight women with PCOS. These data provide mechanistic evidence for the synergism of obesity and PCOS on insulin sensitivity and that is only enhanced by exercise. Furthermore, intrinsic insulin levels found in lean women with PCOS resistance do not impact early insulin signalling events.

1. Stepto NK, Cassar S, Joham AE, Hutchison SK, Harrison CL, Goldstein RF, et al. Women with polycystic ovary syndrome have intrinsic insulin resistance on euglycaemic-hyperinsulinaemic clamp. *Hum Reprod*. 2013 Mar;28(3):777-84.
2. Harrison CL, Stepto NK, Hutchison SK, Teede HJ. The impact of intensified exercise training on insulin resistance and fitness in overweight and obese women with and without polycystic ovary syndrome. *Clin Endocrinol (Oxf)*. 2012 Mar;76(3):351-7.

3. Hutchison SK, Stepto NK, Harrison CL, Moran LJ, Strauss BJ, Teede HJ. Effects of exercise on insulin resistance and body composition in overweight and obese women with and without polycystic ovary syndrome. *J Clin Endocrinol Metab.* 2011 Jan;96(1):E48-56.

Standardised cooling improves the detection of Brown Adipose Tissue by ¹⁸FDG-PET without significant seasonal variation

Moe Thuzar^{1,2}, **Phillip W Law**^{2,3}, **Christina Jang**^{1,2}, **Susanne Jeavons**^{2,3}, **Ken KY Ho**^{1,2}

1. Department of Endocrinology & Diabetes, Princess Alexandra Hospital, Brisbane, Queensland, Australia

2. School of Medicine, University of Queensland, Brisbane, Queensland, Australia

3. Department of Molecular Imaging, Princess Alexandra Hospital, Brisbane, Queensland, Australia

Background: Brown adipose tissue (BAT) is highly prevalent in adult humans. Its detection by ¹⁸FDG-PET-CT is low in non-temperate regions, being markedly affected by seasonal temperature.

Aim: To determine whether a standardised cooling protocol improves detection of BAT in humans.

Methods: 18 (12 men, 6 women) healthy subjects were placed in an air-conditioned room cooled to 19°C for 3 hours before undergoing ¹⁸FDG-PET-CT. 11 subjects were studied twice 2-3 weeks apart to ascertain reproducibility, giving a total of 29 scans. The ¹⁸FDG dose was 75MBq, four times lower than that for diagnostic scanning. The data were compared to 450 scans of patients who underwent diagnostic ¹⁸FDG-PET-CT for various medical indications at room temperature. BAT-positivity was defined by SUV_{max} ≥ 2 in supraclavicular and cervical areas localising to fat attenuation on CT. The rates were seasonally analysed when the mean daily temperatures for Brisbane were 24-26°C in summer, 18-20°C in spring and 15-16°C in winter respectively.

Results: Under standardised cooling, BAT was detected in 76% (22 of 29). Among those studied twice, the scans were concordant in 82%. In diagnostic scans, BAT was detected in 2% (9 of 450) and the prevalence was significantly greater (p=0.01) in winter (4.7%) than in summer (0.66%) or spring (0.66%). With standardised cooling, the seasonal differences were not significant (p=0.34) between winter (85.7% of 14), spring (80% of 5) and summer (60% of 10).

Summary: BAT prevalence under standardised cooling was 35 fold higher than the background prevalence despite employing a much lower FDG dose. Standardised cooling confers high reproducibility with detection rates that do not vary significantly between seasons.

Conclusion: A standardised cooling protocol markedly improves BAT detection without significant seasonal variation.

Acknowledgement: Supported by a Princess Alexandra Hospital Clinical Research Fellowship.

A prospective cohort study investigating relative hyperglycaemia as a determinant of mortality or Intensive Care Unit admission: Introducing the *stress hyperglycaemia ratio*

Gregory W Roberts^{2,1}, **Stephen J Quinn**², **Nyoli Valentine**³, **Tariq Alhawassi**¹, **Hazel O'Dea**¹, **Stephen N Stranks**^{4,2}, **Matthew P Doogue**^{4,2}, **Morton G Burt**^{4,2}

1. Pharmacy Department, Repatriation General Hospital, Adelaide, SA, Australia

2. Faculty of Health Science, Flinders University, Adelaide, SA, Australia

3. Sturt Fleurieu General Practice Education and Training, Adelaide, SA, Australia

4. Southern Adelaide Diabetes and Endocrine Services, Repatriation General Hospital, Adelaide, SA, Australia

Background: Hyperglycaemia on admission to hospital is associated with increased morbidity and mortality. This association is strongest in patients without known diabetes. We hypothesized that relative hyperglycaemia would be more strongly associated with mortality and morbidity than absolute hyperglycaemia.

Methods: Estimated average glucose concentration was calculated from glycosylated haemoglobin in 2290 patients acutely admitted to Flinders Medical Centre, Adelaide. Relative hyperglycaemia was defined by the *stress hyperglycaemia ratio* (SHR), calculated by dividing admission glucose by estimated average glucose. The odds ratios for death or Intensive Care Unit (ICU) admission per unit change in SHR and admission glucose concentration were compared in a multivariable logistic regression analysis.

Results: In univariable analyses, SHR (odds ratio = 1.23 per 0.1, p<0.001) and glucose (odds ratio = 1.18 per mmol/L, p<0.001) were positively associated with in-hospital death or ICU admission. However, in multivariable analysis, the association between in-hospital death or ICU admission and SHR was maintained (odds ratio = 1.20 per 0.1, p<0.001), but attenuated for glucose (odds ratio = 1.03 per mmol/L, p=0.31). In contrast to glucose (p=0.002), the interaction between diabetes and SHR was not significant (p=0.35), indicating that the association between SHR and outcome was not affected by diabetic status. In patients with glucose ≤10 mmol/L, the odds ratio for in-hospital death or ICU admission was 3.9 (95% confidence intervals 2.3-6.8) in the fifth quintile and 2.4 (1.4-4.2) in the fourth quintile relative to the lowest SHR quintile.

Conclusions: SHR is a better predictor of in-hospital death or ICU admission than admission glucose. SHR is associated with in-hospital death or ICU admission in patients with and without diabetes. SHR can identify patients with mild hyperglycaemia below the usual threshold for hypoglycaemic therapy at increased risk of adverse outcomes.

Funding: College of Pharmacy, King Saud University, Saudi Arabia; Novo Nordisk Australasia.

Obesity is associated with poorer survival in Australian women with hormone receptor positive breast cancer.

Susan R Davis¹, Penny J Robinson¹, Robin J Bell¹

1. Monash University, Melbourne, VIC, Australia

Objective: Whether obesity contributes to breast cancer recurrence and breast cancer mortality (BCM) remains uncertain. We investigated the association between moderate–severe obesity (BMI 30 to < 40 kg/m²) at diagnosis, and the combined outcome of breast cancer recurrence or BCM, in women with HR+, HER2– disease, taking into account age, tumour characteristics and treatment.

Design: The Bupa Health Foundation Health and Wellbeing after Breast Cancer Study is a prospective cohort study of 1684 women recruited within 12 months of their diagnosis of invasive breast cancer, June 2004 to December 2006, and followed for 5 years. This analysis included 1155 women, mean age, 58.4±11.6 years, with hormone receptor positive (HR+, HER2–) disease.

Results: 53.8% of the women had Stage–1 disease and 88.9% commenced oral adjuvant endocrine therapy (OAET) within 2 years of diagnosis. Moderate–severe obesity made a significant independent contribution to the likelihood of breast cancer recurrence or BCM (HR = 1.71, 95%CI, 1.12-2.62, p= 0.014).

The other factors independently associated with recurrence or BCM included disease beyond Stage–1 (HR = 2.87, 95% CI 1.73- 4.75, p<0.001), OAET (HR = 0.26, 95% CI 0.14-0.46, p<0.001), mastectomy (HR = 3.28, 95%CI 1.98-5.44, p<0.001) and radiotherapy (HR = 2.12, 95% CI 1.24-3.63, p<0.006). For Stage–1 disease, moderate to severe obesity (HR 3.23, 95% CI 1.48-7.03, p=0.003) and OAET (HR 0.41, 95%CI 0.17-0.98, p<0.046) were significantly independently associated with recurrence or BCM.

Conclusion: Moderate–severe obesity is associated with a poorer prognosis for women with HR+, HER2– disease; this also holds for women with Stage–1 disease, and is independent of age and treatment. As moderate–severe obesity persisted in this analysis, even when controlling for OAET use, our findings support the hypothesis that obesity-associated insulin resistance and /or other factors produced in fat underpin the link between obesity and a poorer breast cancer prognosis.

Continuous subcutaneous hydrocortisone infusion therapy in Addison's disease: a randomised, placebo-controlled clinical trial

Lucy Gagliardi^{1,2}, Marni A Nenko^{1,2}, Tilenka RJ Thynne¹, Jenny von der Borch³, Wayne A Rankin⁴, David E Henley^{5,6}, Jane Sorbello⁷, Warrick J Inder^{7,8}, David J Torpy^{1,2}

1. Endocrine and Metabolic Unit, Royal Adelaide Hospital, Adelaide, SA, Australia

2. School of Medicine, University of Adelaide, Adelaide, SA, Australia

3. Diabetes Centre, Royal Adelaide Hospital, Adelaide, SA, Australia

4. Department of Chemical Pathology, SA Pathology, Adelaide, SA, Australia

5. Department of Endocrinology and Diabetes, Sir Charles Gairdner Hospital, Perth, WA, Australia

6. School of Medicine and Pharmacology, University of Western Australia, Perth, WA, Australia

7. Department of Diabetes and Endocrinology, Princess Alexandra Hospital, Brisbane, Qld, Australia

8. School of Medicine, University of Queensland, Brisbane, Qld, Australia

Context

Patients with Addison's disease (AD) report impaired subjective health status (SHS).^{1,2} Since cortisol exhibits a robust circadian cycle which entrains other biological clocks, impaired SHS may be due to the non-circadian cortisol profile achieved with conventional glucocorticoid replacement. Continuous subcutaneous hydrocortisone infusion (CSHI) reproduces a circadian cortisol profile, but its effects on SHS have not been objectively evaluated.^{3,4}

Objective

To determine the effect of CSHI on SHS in AD.

Design

This was a multicentre, double-blind, placebo-controlled trial of CSHI versus oral glucocorticoid therapy. Participants received in random order four weeks of: CSHI and oral placebo, and subcutaneous placebo and oral hydrocortisone, separated by a two week washout period. SHS was assessed using: the Short-Form 36 (SF-36), General Health Questionnaire (GHQ-28), Fatigue Scale (FS), Gastrointestinal Symptom Rating Scale (GSRs); and Addison's Quality of Life Questionnaire (AddiQoL). Participants were asked their (blinded) treatment preference. Twenty-four hour urine free cortisol (UFC) and diurnal salivary cortisol collections compared cortisol exposure during each treatment.

Results

Ten participants completed the study. Baseline SHS scores (mean ± standard error) were consistent with mild impairment: SF-36 physical component summary 48.4 (±2.4), mental component summary 53.3 (±3.0); GHQ-28 18.1 (±3.3); GSRs 3.7 (±1.6) and AddiQoL 94.7 (±3.7). FS was similar to other AD cohorts 13.5 (±1.0) (p=0.82). UFC between treatments was not different (p=0.87). The 0800h salivary cortisol was higher during CSHI (p=0.03), but not at any other time-points measured. There was no difference between the treatments in the SHS assessments. Five participants preferred CSHI, four oral hydrocortisone and one was uncertain.

Conclusions

Biochemical measurements indicate similar cortisol exposure during each treatment period, although a more circadian pattern was evident during CSHI. CSHI does not improve SHS in AD with good baseline SHS. This casts some doubt on the potential benefit of circadian cortisol delivery on SHS.

1. Løvås K, Loge J, Husebye ES. Subjective health status in Norwegian patients with Addison's disease. *Clin Endocrinol (Oxf)* 2002; 56:581-8.
2. Hahner S, Loeffler M, Fassnacht M, Weismann D, Koschker AC, Quinkler M, Decker O, Arlt W, Allolio B. Impaired subjective health status in 256 patients with adrenal insufficiency on standard therapy based on cross-sectional analysis. *J Clin Endocrinol Metab* 2007; 92:3912-22.
3. Løvås K, Husebye ES. Continuous subcutaneous hydrocortisone infusion in Addison's disease. *Eur J Endocrinol* 2007; 157:109-12.
4. Øksnes M, Björnsdóttir S, Isaksson M, Methlie P, Carlsen S, Nilsen RM, Broman J, Triebner K, Kämpe O, Hulting A, Bensing S, Husebye ES, Løvås K. Continuous subcutaneous hydrocortisone infusion versus oral hydrocortisone replacement for treatment of Addison's disease: A randomised clinical trial. *J Clin Endocrinol Metab* 2014; Feb 11:jc20134253, epub ahead of print.

Effects of GH on anaerobic capacity in adults with growth hormone deficiency: a double blind placebo controlled trial

Viral Chikani^{1,2}, **Ross Cuneo**¹, **Ingrid Hickman**^{2,3}, **Ken Ho**^{1,2}

1. Department of Diabetes and Endocrinology, Princess Alexandra Hospital, Woolloongabba, QLD, Australia

2. University of Queensland, Brisbane, QLD, Australia

3. Department of Nutrition and Dietetics, Princess Alexandra Hospital and the Mater Medical Research Institute, Brisbane, QLD, Australia

Background GH-deficient (GHD) adults have reduced anaerobic exercise capacity(1), a performance measure dependent on energy derived from anaerobic glycolysis and on muscle strength. Short-term GH therapy improves anaerobic exercise capacity in recreational athletes without a change in muscle strength(2), an effect on energy metabolism rather than on muscle anabolism.

Aim To investigate whether short-term GH improves anaerobic capacity and physical function in GHD adults.

Method 17 hypopituitary adults, aged 47±2.4 years on conventional replacement therapy were randomized into a 2-month double-blind placebo-controlled GH replacement (0.5mg/day) study with a crossover at 1-month. Anaerobic capacity (watts) was assessed by the Wingate test and aerobic capacity by the VO₂max (L/min) test. Physical function was assessed by the stair-climb test, chair-stand test and 7-day pedometry. Lean body mass (LBM) was quantified by DEXA. Data were analyzed by repeated-measures ANOVA and tested for carry-over effects. Results are expressed as mean±SE.

Results

There were no statistically significant changes in body composition, anaerobic capacity, aerobic capacity and functional measures between placebo and GH treatments.

	Baseline	Placebo	GH
LBM (kg)	43.9±1.6	43.0±1.7	44.3±1.5
Anaerobic power (W/kg.LBM)	5.9±0.3	6.0±0.3	5.7±0.3
VO ₂ max (mL/kg.LBM/min)	36.8±5.4	38.7±6.9	37.6±5.5
Stair climb test (secs)	19.5±0.7	19.1±0.7	19.1±0.8
Chair stand test (number/30 sec)	19.1±1.0	21.7±1.1	21.4±0.9
Pedometry (Steps/day)	7029±567	6652±455	6594±566

Summary One month of GH replacement did not increase LBM, anaerobic power, VO₂max or measures of physical function.

Conclusion

Short-term GH replacement does not stimulate the anaerobic energy system. Longer term studies are required to ascertain whether GH improves anaerobic capacity in GHD adults.

1. Chikani V, et al. Annual Scientific Meeting of the Endocrine Society of Australia, Sydney 2013;Abstract 117
2. Meinhardt U, et al. *Ann Intern Med*.2010;152(9):568-77.

Ovarian sex cord stromal tumours

Dilys Leung¹, **Edwina Oliver**¹, **Maria Alexiadis**¹, **Peter Fuller**¹, **Simon Chu**¹

1.MIMR-PHI Institute, Clayton, VIC, Australia

Ovarian cancer is the most common fatal gynaecological malignancy. Tumours of the stroma and/or sex cords represent approximately 8% of ovarian tumours and develop from the connective tissue of the ovaries. Because these cells participate in ovarian hormonal function, most of the sex-cord stromal tumours are able to secrete hormones, which explains the hormonal dysfunctions associated with these cancers. By far the most common of these tumours are the granulosa cell tumours (GCT). Adult GCT are characterized by a mutation in the FOXL2 gene (C134W), which is absent in the less common juvenile form (which represent 5% of GCT). GCT exhibit many morphological, biochemical and hormonal features of proliferating normal pre-ovulatory granulosa cells, including both estrogen and inhibin biosynthesis; inhibin has proven to be a useful tumour marker. GCT are characterized by an indolent course, and a high rate of late recurrence. Most GCT are stage 1 and are cured surgically, however, ~80% of patients with aggressive or recurrent tumours die from their disease. Chemotherapy and hormonal therapy have proven to be of limited efficacy. In order to address the key questions of pathogenesis and targeted therapeutics,

our strategy has been to examine the role of: 1) nuclear receptors in the pathogenesis of GCT (in particular ER β and PPAR γ); 2) constitutive NF- κ B activity in the human GCT-derived cell lines COV434 and KGN; and 3) microarray analysis of adult GCT segregated by stage. The above studies have identified several potential, novel, GCT-specific therapeutic strategies which are the subject of ongoing investigations. As with other uncommon tumour types, insights from research on GCT may be prismatic, i.e. by clarifying mechanisms of normal ovarian function, and providing insights into other dysfunctions of the ovary such as other sex cord-stromal tumours, premature ovarian failure, polycystic ovarian syndrome and infertility.

82

Modern approaches to the management of acromegaly

Ken K.Y. Ho¹

1. Centres for Health Research and Department of Endocrinology, Princess Alexandra Hospital, Brisbane, QLD, Australia

The last decades have seen important advances in the fields of neuroendocrinology, cell biology, clinical chemistry, drug development, imaging, neurosurgery and radiotherapy, all of which have brought benefits to the management of acromegaly. The merits of GH and insulin-like growth factor (IGF)-I measurements in the diagnosis and in the assessment of therapeutic outcomes of acromegaly have been intensively studied. The biochemical targets that for treatment are a normal, age-adjusted IGF-I and a random GH <1 ng/mL using sensitive specific two site assays. Three classes of drugs offer therapeutic options for acromegaly: dopamine agonists, somatostatin analogues and GH receptor antagonist. Dopamine agonists have a limited adjunctive role in disease control. Somatostatin analogues, octreotide and lanreotide have gained a firm place in drug therapy, controlling hypersecretion and tumour growth in over 50-60% of patients. A new generation somatostatin analogue (pasireotide) that targets a wider spectrum of somatostatin receptor subtypes holds potential of greater efficacy for acromegaly. Pegvisomant, a GH receptor antagonist normalizes IGF-1 in nearly all patients but does not control tumour growth. Surgery remains primary therapy for small resectable tumours. where the chance of cure is high. For large or invasive tumours where the prospect of surgical cure is remote, first-line therapy is somatostatin analogue treatment with debulking surgery having an adjunctive role to achieve tight control or to alleviate compression of the optic chiasm. Radiotherapy remains important adjuvant treatment where other modes are contraindicated or have failed. Compared to conventional external beam therapy, stereotactic radiosurgery reduces treatment time and the risk of radiation damage. Acromegaly remains a challenging disease to manage. However the expanding range of therapeutic options has brought better outcomes for patients and offers the potential to tailor therapy based on a patient's individual requirements

89

Estrogen receptor alpha drives proliferation in PTEN-deficient prostate carcinoma by stimulating survival signalling

Mitchell Lawrence¹, Itsuhiro Takizawa¹, Preetika Balanathan¹, Richard Rebello¹, Helen Pearson², John Pedersen¹, Normand Pouliot³, Patrick Humbert², Gail Risbridger¹, Luc Furic¹

1. Monash University, Clayton, Vic, Australia

2. Peter MacCallum Cancer Centre, Melbourne

3. Peter MacCallum Cancer Centre, Melbourne, Vic, Australia

While high doses of estrogen, in combination with androgens, can initiate prostate neoplasia via activation of the estrogen receptor α (ER α), the role of ER α in prostate cancer cells within established tumors is largely unknown. Here we show that expression of ER α is increased in high grade human prostate cancer. Similarly, ER α is elevated in mouse models of aggressive prostate cancer driven by the overexpression of the proto-oncogene MYC or the conditional deletion of the tumor suppressor PTEN. Furthermore, within the prostate of PTEN-deficient mice, there is a progressive pattern of ER α expression: low in benign glands, moderate in tumors within the dorsal, lateral and ventral lobes, and high in tumors within the anterior prostate. This expression significantly correlates with the levels of the proliferation marker Ki67 and *in vitro* knockdown of ER α in cells derived from PTEN-deficient tumors causes a significant and sustained decrease in proliferation. Depletion of ER α also reduces the levels of the MYC protein. Finally, ER α knockdown reduces the activity of the PI3K and MAPK pathways, which are both downstream targets of non-genomic ER α action. Collectively, these results demonstrate that ER α orchestrates cell proliferation and is a key driver of the neoplastic growth of prostate cancer cells.

90

The Kallikrein-related serine peptidase, KLK4, regulates the TGF β 1 pathway in the tumour-stroma microenvironment in prostate cancer.

Ruth Fuhrman-Luck^{1,2}, Scott Stansfield^{1,2}, Marcus Hastie³, Thomas Stoll³, Carson Stephens^{1,2}, Daniela Loessner⁴, Melanie Lehman^{1,2}, Colleen Nelson^{1,2}, Jeffrey Gorman³, Judith Clements^{1,2}

1. Australian Prostate Cancer Research Centre, QLD, Australia

2. Australian Prostate Cancer Research Centre-Queensland and Institute of Health and Biomedical Innovation, Queensland University of Technology, Translational Research Institute-QUT, Brisbane, QLD, Australia

3. QIMR Berghofer Medical Research Institute, Herston, QLD

4. Institute of Health and Biomedical Innovation, QLD, Australia

Prostate cancer cells reside in a complex stromal microenvironment often referred to as "reactive" stroma which is a critical component of prostate cancer initiation and progression. The mounting evidence for its critical nature has led to increased interest in this niche as a target for new therapeutic approaches. Cancer associated fibroblasts (CAFs) play a key role in this

niche regulating the tumour microenvironment. Factors secreted by prostate cancer cells can 'activate' non-malignant associated fibroblasts to become CAFs. KLK4 is over-expressed in both localised and bone metastatic prostate cancer and so has the capacity to act as a paracrine factor on the surrounding stroma. The Aim of this study was to elucidate the role of KLK4 in tumour-stroma cross-talk by identifying its substrates in the prostate cancer lines, LNCaP and PC3 (also derived from a bone metastasis) and in the prostate (stromal) fibroblast line WPMY-1. This was accomplished at the protein level utilising the 'PROtein TOpography Migration Analysis Platform' (Dix et al., Cell, 2008). Gene expression changes following KLK4 treatment were also assessed by gene microarray analysis. We identified 50 putative novel KLK4 protein substrates, 11 of which directly interact with the growth factor TGF β 1. Strikingly, the most enriched pathway (based on DAVID analysis, $p < 0.01$) following transcriptome analysis of the KLK4-treated cells was the TGF β 1 pathway. KLK4-treated fibroblasts also expressed elevated levels of a number of genes consistent with a CAF genotype. These findings suggest that KLK4 is a critical regulator of the reactive stromal niche, via the TGF β 1 pathway, and a potential novel therapeutic target for prostate cancer.

Fibroblast and mast cell interactions in the human prostate cancer microenvironment

Kohei Hashimoto¹, Stuart J Ellem¹, Natalie Lister¹, Birunthi Niranjan¹, John Pedersen¹, Mark Frydenberg¹, Elena M De Juan-Pardo², Dietmar W Hutmacher², Gail P Risbridger¹

1. Monash University, Clayton, VIC, Australia

2. Queensland University of Technology, Brisbane, QLD, Australia

Prostate cancer development and progression is associated with the stromal microenvironment which is comprised of various cell populations such as cancer-associated fibroblasts (CAFs) and immune cells with the latter including mast cells. Mast cells play a key role in the inflammatory process. When activated, a mast cell rapidly releases its various chemical mediators into the interstitium. However, little is known about their role in cancer tissue. The aim of this study is to clarify the multiple cellular interactions between human tumour stromal fibroblasts and mast cells on epithelial cell morphology and motility.

The multi-cellular interaction in the prostate microenvironment was examined using a novel 3D cellularised matrix co-culture model. Patient-matched CAFs and non-malignant prostatic fibroblasts (NPFs) isolated and validated from prostatectomy specimens were seeded and stimulated for extracellular matrix deposition, before labelled benign epithelia (BPH-1) was added and co-cultured further. Human mast cells (HMC-1) were co-cultured with CAFs or NPFs and benign epithelia to determine their specific impact on epithelial transformation. Motility (migration speed and displacement) was determined using time-lapse videomicroscopy. Following culture, cells were fixed, stained, and quantitative cell morphometric analyses of epithelial cell shape factor, spread area and orientation was determined using Metamorph software.

After 2 days of co-culture, CAFs, but not NPFs, altered BPH-1 epithelial morphology in a novel *in vitro* co-culture model. When BPH-1 cell morphology on NPFs or CAFs co-cultured with HMC-1 mast cells and supernatant of HMC-1 cell were compared, mast cells potentiated CAF effects on the epithelium, (shape factor, spread area, migration speed and displacement).

In summary, using a novel quantitative co-culture method *in vitro*, this study demonstrates mast cell-fibroblast interactions in prostate cancer microenvironment, with mast cell's potentiating CAF effects on the epithelium.

Patient-derived xenografts reveal that intraductal carcinoma of the prostate is a prominent pathology in BRCA2 mutation carriers with prostate cancer and correlates with poor prognosis

Renea Taylor¹, David Clouston², Ania Sliwinski³, Heather Thorne³, Sally Hunter³, Jason Li³, k ConFab³, Gillian Mitchell³, Declan Murphy³, Mark Frydenberg¹, David Pook¹, John Pedersen², Roxanne Toivanen¹, Hong Wang¹, Melissa Papargiris¹, Damien Bolton⁴, Gail Risbridger¹

1. Monash University, Clayton, VIC, Australia

2. TissuPath, Mt Waverly

3. Peter MacCallum Cancer Center, Melbourne

4. Department of Urology, Austin Hospital, Melbourne

Intraductal carcinoma of the prostate (IDC-P) is a distinct clinic-pathologic entity associated with aggressive prostate cancer. Prostate cancer patients carrying a BRCA2 germline mutation also exhibit highly aggressive tumours with poor prognosis. In this study, we investigated the presence and implications of IDC-P in men with a strong family history of prostate cancer, including those with a pathogenic BRCA2 mutation. Patient-derived xenografts (PDXs) were generated from three germline BRCA2 mutation-carriers. Specimens were examined for histologic evidence of IDC-P. Whole Genome Copy Number Analysis (WG-CNA) was performed IDC-P from primary and matched PDX specimens to determine genetic integrity. Clinical data for BRCA2 patients were analysed to determine the incidence of IDC-P and association with overall survival using Kaplan-Meier analysis. PDX from BRCA2 tumours showed increased incidence of IDC-P compared to sporadic prostate cancer ($p = 0.015$). WG-CNA analysis of IDC-P from matched (primary and PDX) BRCA2 tumours had highly similar genetic profiles. IDC-P was more common in BRCA2 carriers (42%; $n = 33$) compared to sporadic prostate cancer cases (9%; $n = 32$). Survival outcomes demonstrated BRCA2 carriers patients with IDC-P had significantly worse prognosis than BRCA2 carriers without IDC-P (HR: 16.9, $p = 0.0064$). These novel data using PDXs revealed IDC-P in patients with familial prostate cancer possess an aggressive tumour phenotype. This phenotype (ICDP) correlated with poor survival, even when the stage and grade of cancer at diagnosis was similar. This study highlights the utility of laboratory-based models (PDX) to identify novel tumour biology with clinical implications.

Co-targeting RNA Pol I and PIM kinase activity suppresses MYC-driven tumorigenesis in the prostate.

Richard J Rebello¹, Donald Cameron², Gail P Risbridger¹, Richard B Pearson², Ross D Hannan², Luc Furic¹

1. Monash University, Melbourne, VIC, Australia

2. Peter MacCallum Cancer Centre, Melbourne, VIC, Australia

Publish consent withheld

1. Bywater, MJ., Pearson, RB., McArthur, G., Hannan, R. Dysregulation of the basal RNA polymerase transcription apparatus in cancer. 2013. Nat Rev Cancer.
2. Wang, J., Kim, J., Roh, M., Franco, OE., Hayward, SW., Willis, ML., Abdulkadir, SL. Pim1 kinase synergizes with c-MYC to induce advanced prostate carcinoma. 2010. Oncogene.
3. Wang, J., Anderson, PD., Luo, W., Gius, D., Roh, M., Abdulkadir, SL. Pim1 kinase is required to maintain tumorigenicity in MYC-expressing prostate cancer cells. 2012. Oncogene.
4. Bywater, MJ., Poortinga, G., Sanij, G., Hein, N., Peck, A., Cullinane, C., Wall, M., Cluse, L., Drygin, D., Anderes, K., Huser, N., Proffitt, C., Bliesath, j., Haddach, M., Shwaebe, MK., Ryckman, DM., Rice, WG., Shmidt, C., Lowe, SW., Johnstone, RW., Pearson, RB., McArthur, GA., Hannan, RD. Inhibition of RNA polymerase I as a therapeutic strategy to promote cancer-specific activation of p53. 2012. Cancer Cell.

Characterisation of isoform-specific progesterone receptor DNA binding patterns in normal and malignant breast

Dinny Graham¹, Audrey Silvestri¹, Tram B Doan¹, Britta M Jacobsen², Kathryn B Horwitz^{2,3}, Christine L Clarke¹

1. Westmead Institute for Cancer Research, Sydney Medical School - Westmead, University of Sydney at Westmead Millennium Institute, Westmead, NSW, Australia

2. Department of Pathology, University of Colorado Denver, Aurora, Colorado, USA

3. Department of Medicine, University of Colorado Denver, Aurora, Colorado, USA

Progesterone is essential for normal development and function in the female breast. It is also implicated in breast cancer development since women exposed to progesterone analogues in hormone replacement therapy are at increased risk of developing the disease. Progesterone exerts its effects via its two nuclear receptors PRA and PRB. In the presence of ligand PR dimerises and binds DNA to regulate transcription of gene targets. PR forms both homodimers and heterodimers and all three dimer species are transcriptionally active. PRA and PRB have distinct transcriptional activities in vitro and play different tissue-specific roles. They are equivalently expressed in normal epithelial cells; however over-expression of one isoform, most often PRA, is common in breast cancer, suggesting that altered isoform expression may underlie an aberrant transcriptional response to progestins in malignancy. We previously reported in cells expressing both PR isoforms that transcriptional partners FOXA1, AP-1 and NF1, co-operate with PR to determine cell type specific genomic binding. We used PR ChIP-seq, in breast cancer cells expressing just one PR isoform, to define the factors influencing PR homodimer interactions. Both homodimers recognized a conserved progesterone response element (PRE), similar to the element bound by the heterodimer. PRB bound with higher frequency and specificity to these sites than PRA. Transcriptional cofactor motifs were detected in some binding sites, including weak enrichment of FOXA1 motifs with both homodimers, but with much lower significance than PREs, suggesting that homodimer binding is less dependent on cofactor availability in breast cancer cells. Our data suggest that in breast cancers, when PR homodimers become predominant, the specificity of progesterone regulation may be lost or reduced, resulting in inappropriate activation of deleterious signalling pathways.

Autoimmune thyroid disease incidence varies by race/ethnicity

Don McLeod¹, Patrizio Caturegli, David Cooper, Peter Matos, Susan Hutfless

1. Royal Brisbane & Women's Hospital, Herston, QLD, Australia

Importance: Little is known about the effect of race/ethnicity on the incidences of Graves' disease and Hashimoto's thyroiditis.

Methods: We assessed autoimmune thyroid disease incidence in U.S. active duty service personnel aged 20-54 years from 1997-2011 (20,270,688 person years), calculating the direct age-standardized incidence and incidence rate ratios (IRR) for women and men by self-reported race/ethnicity.

Results: For Graves' disease, the incidence was almost two times greater in African American women (IRR=1.92 [1.56-2.37]) and Asian/Pacific Islanders (IRR=1.78 [1.20-2.66]) than in Caucasian women. Similarly, the incidence was over two times greater in African American men (IRR=2.53 [2.01-3.18]) and Asian/Pacific Islanders (IRR=3.36 [2.57-4.40]) than in Caucasian men. For Hashimoto's thyroiditis, on the contrary, Caucasians had the highest incidence in both women (for African Americans, IRR=0.43 [0.29-0.63], and 0.42 [0.20-0.90] for Asian/Pacific Islanders) and men (for African Americans, IRR=0.22 [0.11-0.47], and 0.23 [0.07-0.72] for Asian/Pacific Islanders). Women were 4.98 (4.31-5.74) and 7.86 (6.44-9.59) times more likely than men to have Graves' disease and Hashimoto thyroiditis, respectively. The incidence of both diseases increased with age in women and men ($P \leq 0.032$).

Conclusions and significance: The incidence of Graves' disease and Hashimoto's thyroiditis varies substantially by race/ethnicity. This presentation will also discuss follow-on work examining whether these patterns are seen in the wider U.S. population.

Recognizing racial differences in autoimmune thyroid disease is key to understanding why it occurs. We don't yet know whether the differences seen are due to genetics, environmental exposures, or a combination of both. Finding the root causes of thyroid autoimmunity has the potential to lead to prevention of thyroid disorders, and may also lead to crucial insights into other autoimmune disease.

Depletion of high affinity corticosteroid-binding globulin (CBG) corresponds to illness severity in sepsis and septic shock; clinical implications.

Marni A Nenke¹, John G Lewis², Wayne Rankin³, Natalie E Stevens⁴, Marianne J Chapman⁵, David J Torpy¹

1. Endocrine and Metabolic Unit, Royal Adelaide Hospital, Adelaide, SA, Australia

2. Steroid and Immunobiology Laboratory, Canterbury Health Laboratories, Christchurch, New Zealand

3. Chemical Pathology Directorate, SA Pathology, Adelaide, SA, Australia

4. Experimental Therapeutics Laboratory, Hanson Institute, Adelaide, SA, Australia

5. Intensive Care Unit, Royal Adelaide Hospital, Adelaide, SA, Australia

Background: Sepsis and septic shock produce marked hypercortisolaemia [1]. Cortisol maintains vascular tone and cardiac contractility and has potent anti-inflammatory effects crucial to survival. Circulating CBG transports 80% of cortisol. Cleavage of high cortisol-binding affinity CBG (haCBG) reduces CBG:cortisol binding affinity 10-fold, producing high and low cortisol-binding affinity CBG (laCBG) and elevating free cortisol levels. We propose that prolonged inflammation may lead to depletion of haCBG, limiting cortisol distribution to inflammatory sites and perpetuating chronic inflammation. We measured haCBG and laCBG in sepsis and septic shock.

Hypothesis: That sepsis causes marked depletion in haCBG in accordance with illness severity, comparing septic shock to sepsis.

Methods: A prospective, observational cohort study was performed in an adult tertiary level intensive care unit in Adelaide, Australia, between May and October 2013. Twice-daily blood samples were collected for up to five days from patients with initial diagnoses of sepsis (S) or septic shock (SS). Total and haCBG were assayed in parallel with specific monoclonal antibodies using our novel in-house method [2]. Free and total cortisol were also measured.

Results: 103 samples from 29 patients were analysed. These were categorised into S, SS or SS with death (SS-D). haCBG decreased in accordance with illness severity category ($p = 0.0003$). haCBG levels fell significantly from (mean \pm SEM) 411.7 \pm 13.0 to 318.3 \pm 22.4 to 201.7 \pm 30.9 and 151.2 \pm 22.2 nmol/L, in control, S, SS and SS-D groups respectively. Patients dying with septic shock had the lowest proportion of haCBG to total CBG of all groups at 54.3 (6.1) %.

Conclusion: haCBG, which may have a crucial role in cortisol transport to inflammatory sites, bore a close relationship to illness severity. We suggest that depletion of available haCBG may impair optimal tissue delivery of cortisol in critical illness.

This project was undertaken whilst holding a Royal Adelaide Hospital AR Clarkson Scholarship and 2014 Clinical Project Grant

1. Ho JT, Al-Musalhi H, Chapman MJ, Quach T, Thomas PD, Bagley CJ, Lewis JG, Torpy DJ: Septic shock and sepsis: a comparison of total and free plasma cortisol levels. *J Clin Endocrinol Metab* 2006, 91(1):105-114.
2. Lewis JG, Elder PA: Intact or "active" corticosteroid-binding globulin (CBG) and total CBG in plasma: determination by parallel ELISAs using monoclonal antibodies. *Clin Chim Acta* 2013, 416:26-30

Effect of therapeutic glucocorticoids on insulin sensitivity, cardiovascular risk and energy metabolism in patients with inflammatory arthritis

Anjana Radhakutty^{1,2}, Brenda L Mangelsdorf¹, Sophie M Drake¹, Dorit Samocha-Bonet³, Arthur B Jenkins³, Leonie K Heilbronn⁴, Malcolm D Smith^{2,5}, Campbell H Thompson^{2,4}, Morton G Burt^{1,2}

1. Southern Adelaide Diabetes and Endocrine Services, Repatriation General Hospital, Adelaide, SA, Australia

2. Faculty of Health Sciences, Flinders University, Adelaide, SA, Australia

3. Diabetes and Obesity research program, Garvan Institute of Medical Research, Sydney, NSW, Australia

4. Discipline of Medicine, The University of Adelaide, Adelaide, SA, Australia

5. Department of Rheumatology, Repatriation General Hospital, Adelaide, SA, Australia

Insulin resistance can increase arterial stiffness acutely by reducing endothelial function and chronically by stimulating atherogenesis. Postprandial glucose is more strongly associated with vascular dysfunction than fasting glucose concentration. Low dose prednisolone causes insulin resistance and postprandial hyperglycaemia. We investigated whether prednisolone-induced insulin resistance is associated with postprandial vascular dysfunction. Our secondary aim was to investigate the effect of prednisolone on postprandial fat oxidation.

Eighteen subjects with inflammatory arthritis (6 males, age 63.9 \pm 7.3 years, BMI 28.1 \pm 5.2 kg/m²) who had not taken oral glucocorticoids for \geq 6 months were studied before and after prednisolone 6 mg/day for 7 days to determine the acute effect of prednisolone. Pre-prednisolone data were also compared to 18 subjects (6 males, age 66.2 \pm 6.8 years, BMI 27.9 \pm 6.1 kg/m²) taking long-term (>6 months) prednisolone (6.5 \pm 1.8 mg/day) to determine the chronic effect of prednisolone. Arterial stiffness (augmentation index measured by applanation tonometry), endothelial function (reactive hyperaemia index by peripheral artery tonometry) and fat oxidation (by indirect calorimetry) were measured before and after a mixed meal (10 kcal/kg, 45% carbohydrate, 15% protein, 40% fat). Insulin sensitivity was estimated using the Matsuda index.

Insulin sensitivity was reduced by acute (p=0.01) and chronic (p=0.04) prednisolone (Table). Postprandial augmentation index was lower after acute prednisolone (p ≤0.001) indicating reduced arterial stiffness, but not during chronic prednisolone use (Table). The postprandial reduction in reactive hyperaemia index did not change with acute prednisolone, but tended to be lesser in patients on chronic prednisolone, suggesting increased postprandial endothelial function (p=0.09) (Table). Both acute (p=0.01) and chronic (p=0.01) prednisolone attenuated postprandial suppression of fat oxidation (Table).

In conclusion, acute and chronic low dose prednisolone reduced insulin sensitivity. However, this was not associated with adverse changes in vascular function. Fat oxidation did not suppress postprandially in subjects on prednisolone, which may be secondary to but also exacerbate insulin resistance.

Table

	Before prednisolone	Acute prednisolone	Chronic prednisolone
Matsuda index	3.59±1.10	2.03±0.97*	1.86±0.95*
Augmentation index (%*min)	2962±865	2552±837*	2690±1152
Δ Reactive hyperaemia index	-0.75±0.73	-0.49±0.64	-0.36±0.59
Δ Fat oxidation (mg/min)	-16.33 ± 20.17	-2.14 ± 26.13*	-1.44 ± 12.03*

***P<0.05**

Novel insights into the renal-bone axis in thalassemia major

Phillip Wong^{2,3,1}, Frances Milat^{2,4,1}, Peter J Fuller^{2,3,1,5}, Matthew T Gillespie⁴, Danielle Oh⁶, Vicky Kartsogiannis⁴, James Doery⁷, Donald Bowden⁵, Sant Rayn Pasricha^{6,8}, Ken Lau^{2,9}

1. Endocrinology, Monash Health, Melbourne, Victoria, Australia

2. Medicine, Monash University, Melbourne, Australia

3. Endocrinology, PHI-MIMR Institute of Medical Research, Melbourne, Victoria, Australia

4. Endocrinology, PHI-MIMR Institute of Medical Research, Melbourne, Victoria, Australia

5. Biochemistry and Molecular Biology, Monash University, Melbourne, Victoria, Australia

6. Thalassemia Unit, Monash Medical Centre, Melbourne, Australia

7. Pathology, Monash Health, Melbourne, Victoria, Australia

8. MRC Human Immunology Unit, MRC Weatherall Institute of Molecular Medicine, Oxford University, Oxford, United Kingdom

9. Radiology, Monash Health, Melbourne, Victoria, Australia

β-thalassemia major is a disorder of red blood cell production requiring chronic transfusion and iron chelation to prevent iron toxicity and multi-organ disease. Bone disease is common with marrow expansion, iron toxicity and endocrinopathies contributing to low bone mineral density (BMD) and fractures. Recently, reports of renal tubulopathy and hypercalciuria have raised concerns of a renal role in accelerated bone loss in this cohort. In a retrospective study, we reported that 18.1% of patients with β-thalassemia major had symptomatic renal tract calculi and identified an association between urolithiasis and low BMD. To determine the true prevalence and chemical composition of urolithiasis and its association to BMD in patients with β-thalassemia major, we investigated 27 subjects presently asymptomatic for stone disease. All subjects underwent an initial single energy CT of the renal tract, and if a calculus was detected, dual-energy data was acquired, enabling derivation of its chemical composition from a standardised atomic number plot. Synchronous serum and urine biochemistry were measured and BMD determined. Urolithiasis was present in 16/27 (59%). Affected patients generally had multiple stones, often of varying composition, with struvite (33.3%), calcium oxalate (31.3%) and cysteine (21.6%) stones being the most prevalent. Hypercalciuria was present in 77.8% of subjects, and those with calcium-containing urolithiasis had dramatically reduced

femoral neck BMD compared to non-calcium stone formers (z score -2.40 vs -0.2, $P=0.04$). The unusually high prevalence of cysteine stones and its association with renal tubulopathy warrants further investigation. This study confirms the prevalence of urolithiasis in β -thalassaemia major to be 10 fold that of the general population. It raises questions about the pathophysiology of urolithiasis and highlights the importance of the renal-bone axis in the management of bone disease in this condition.

Hyperostosis – a new phenotypic feature of renal cysts and diabetes syndrome (RCAD)

Yvonne Chow¹, Christine Rodda¹

1. Western Health, St Albans, VIC, Australia

We report the case of a 16 year old female with congenital glomerulocystic kidney disease. Given a strong family history of renal disease, a molecular karyotype was performed. This revealed **17q12 del**, with a 1.4 megabase deletion on the long arm of chromosome 17. Microdeletions in this region, encoding the hepatocyte nuclear factor-1 beta (HNF1B), cause renal cysts and diabetes syndrome (RCAD).

Phenotypic features of RCAD that were subsequently identified in our patient were maturity-onset diabetes of the young 5 (MODY5) and the recently identified hypomagnesaemia with elevated urinary magnesium. No genital tract abnormalities were detected on ultrasonography, although this has been widely documented in the literature.

Here we describe a possible new phenotypic feature of RCAD. Our patient exhibits hyperostosis of her skull bones. Furthermore, despite a concurrent eating disorder requiring inpatient management, our patient has surprisingly preserved bone mineral density. To our knowledge, bone hypertrophy as a feature of RCAD is yet to be described in the literature.

Thyroiditis related to cancer biological therapy: CTLA-4 and PD-1 blockade

Teresa Lam¹, Richard Kefford², David Chipps¹

1. Department of Diabetes and Endocrinology, Westmead Hospital, Sydney, NSW, Australia

2. Westmead Hospital and Melanoma Institute Australia, University of Sydney, Sydney, NSW, Australia

Introduction:

New immunomodulatory therapies for malignancies such as melanoma have transformed their management with significantly enhanced survival outcomes¹. Antibodies against CTLA-4 (ipilimumab) and the programmed death-1 (PD-1) molecule increase the cytotoxic function of T-cells with excellent tumour response rates^{1,2}. However, these therapies may also result in immune-related adverse effects. We describe 4 patients who developed thyroiditis due to CTLA-4 and PD-1 blockade.

Case Series:

Patient 1 had a background of metastatic melanoma and received ipilimumab. Following 3 cycles of ipilimumab, he developed hyperthyroidism which progressed to hypothyroidism 4 weeks later (table 1). Findings on ultrasound were consistent with thyroiditis. Thyroid antibodies were present and levothyroxine replacement was also required.

Discussion:

Three patients received anti-PD-1 therapy with pembrolizumab (formerly MK3475) as part of the KEYNOTE-001 study, 2 of whom had metastatic melanoma and 1 non-small cell lung cancer. Two patients presented with hypothyroidism 9 – 12 months after commencing pembrolizumab (table 1), preceded by subclinical hyperthyroidism 4 months prior to presentation. The third patient received pembrolizumab at a dose of 10mg/kg and presented with hyperthyroidism after 1 cycle, progressing to hypothyroidism after 4 weeks. In all 3 patients, thyroid antibodies were not detected, but ultrasound findings were consistent with thyroiditis. One patient had a thyroid nodule and underwent fine needle aspiration. Cytology demonstrated benign follicular cells with several multinucleated giant cells. Two patients remain on levothyroxine replacement.

Thyroiditis is a known side effect of both CTLA-4 and PD-1 blockade. CTLA-4 gene polymorphisms are associated with autoimmune thyroid diseases³. The exact mechanisms of anti-PD-1 induced thyroiditis remain unclear, but may be due to a switching of the immune system to an effector T-cell response, resulting in macrophage activation by interferon gamma, and cell-mediated thyroid damage⁴. Monitoring of thyroid function tests are required with use of these therapies.

Table 1: Progression of thyroid function tests in ipilimumab and anti-PD1 induced thyroiditis

	<u>Ipilimumab</u>		<u>Anti-PD1 agent</u>					
	<u>Patient 1</u>		<u>Patient 2</u>		<u>Patient 3</u>		<u>Patient 4</u>	
Age:	50		57		71		52	
Cycle (3 weekly)*:	3		10		18		1	
Dose:	3 mg/kg		2 mg/kg		2 mg/kg			
TFTs**:	1***	2****	1	2	1	2	1	2
TSH (mIU/L) (0.40 – 5.50)	0.02	50.1	0.17	22.73	<0.04	34.70	<0.04	39.77
T4 (pmol/L) (10.3 – 23.2)	22.0	<5.1	15.4	10.3	20.8	6.4	77.2	9.0
T3 (nmol/L) (0.9 – 2.8)	8.4	<1.5	1.6	1.2	3.0	1.1	9.2	0.8
Thyroid antibodies								
anti-TPO (0 – 120 IU/mL)	548		<20		<10		<10	
anti-Tg (0 – 80 IU/mL)	>3000		<10		<20		41	
TRAb (< 1.0 IU/L)	<1.0		-		-		<1.0	
Ultrasound	<u>thyroiditis</u>		<u>thyroiditis</u>		<u>thyroiditis</u>		<u>thyroiditis</u>	

* number of cycles at presentation

** all patients were euthyroid prior to commencing biological therapy

*** hyperthyroid phase

**** hypothyroid phase

1. Hamid, O et al. Safety and tumor responses with lambrolizumab (anti-PD-1) in melanoma. The New England Journal of Medicine. 2013;369:134-144
2. McDermott, DF et al. PD-1 as a potential target in cancer therapy. Cancer Medicine. 2013;2(5):662-673
3. Min, L et al. Thyroid autoimmunity and ophthalmopathy related to melanoma biological therapy. European Journal of Endocrinology. 2011;164:303-307
4. Tomer, Y et al. Interferon induced thyroiditis. Best practice and research clinical endocrinology and metabolism. 2009;23:703-712

Denosumab for control of hypercalcaemia in Primary hyperparathyroidism

Jasna Aleksova¹, Howard J Zeimer¹, Richard J MacIsaac^{1,2}

1. St Vincents Hospital, Fitzroy, VIC, Australia

2. University of Melbourne, Melbourne

We present a case series of three patients with primary hyperparathyroidism (PPH) who achieved sustained normocalcaemia following denosumab therapy, and subsequently outline the potential use of denosumab in the medical treatment of PPH in patients otherwise unsuitable for surgical cure. Case one, an 80 year old male presented with functional decline and was noted to have PPH and severe hypercalcaemia amongst multiple medical co-morbidities. He declined surgery given poor functional condition. A single dose of 60mg denosumab was administered following a new diagnosis of osteoporosis based on DEXA scanning. His serum calcium normalised from 3.06mmol/L to 2.32mmol/L within two weeks of treatment, and remained normal three months post dose. Case two, a 70 year old female presented with a recurrence of PPH following previous left inferior gland parathyroidectomy. She had co-existing osteoporosis and previous 10 years of bisphosphonate therapy. Her calcium levels had remained elevated despite bisphosphonate therapy and the patient was reluctant for further surgical intervention. Denosumab for her osteoporosis was initiated 60mg 6 monthly after deteriorating bone mineral density (BMD). Her calcium levels normalised within 6 months and 2 years later she remains normocalcaemic and has improved BMD. Case three, an 80 year old female with osteoporosis presents with an unstable C2 fracture following a fall. During her inpatient stay was noted to have PPH and hypercalcaemia and other clinical symptoms resulting from hypercalcaemia. Given the unstable C2 fracture surgical intervention for her PPH could not be undertaken due to unacceptable anaesthetic risks associated with neck manipulation. She received denosumab 60mg for treatment of her osteoporosis and her calcium levels normalised from 2.85mmol/L to 2.52mmol/L within one week. These cases highlight a potential role for denosumab in controlling hypercalcaemia in patients with PPH who are otherwise unsuitable for surgery.

Prevalence and predictors of diabetes after lung transplantation; A prospective, longitudinal study

Kathryn Hackman^{1,2}, Gregory Snell^{1,2}, Leon Bach^{1,2}

1. Alfred Hospital, Prahran, VIC, Australia

2. Medicine, Monash University, Melbourne

Diabetes mellitus (DM) is common following lung transplant (LTx) and is an independent risk factor for mortality. No studies to date have prospectively determined the incidence or prevalence of DM using the oral glucose tolerance test (OGTT) pre and post LTx. Further, changes in metabolic parameters following LTx and risk factors for persistent DM following LTx have not been comprehensively studied.

Methods

Prospective, longitudinal study comparing DM status before and after LTx, using the OGTT. DM prevalence and changes in metabolic control over time were determined. Risk factors for persistent new onset DM after transplant (NODAT) and survival differences by DM status were assessed.

Results

Between 1/8/2010 – 1/12/2012, 156 patients underwent LTx. Baseline DM prevalence was 25%, increasing to 47%, 44% and 40% at 3, 12 and 24 months respectively. Impaired glucose tolerance &/or impaired fasting glucose was present in a further 15% at baseline and 20%, 11% and 7% at 3, 12 and 24 m. Incidence of NODAT was 31%, 29% and 17% at 3, 12 and 24 m.

Non-fasting insulin levels fell 3 months after Tx but returned to baseline by 2 years.

PreTx DM was the strongest predictor of persistent DM post Tx. The only risk factors for NODAT were 1 and 2 h glucose levels on preTx OGTT (OR 1.73 (95% CI 1.19–2.50), $p=0.004$ and 1.84 (1.22–2.77), $p=0.004$ respectively).

Survival was reduced in patients with DM at study end vs those without (estimated mean 979 (888-1071) vs 1140 (1070–1210) d, $p=0.023$).

Conclusion

Most patients had dysglycemia during the first year after LTx and 32% developed NODAT. Only preTx OGTT glucose levels predicted persistent NODAT. As DM was common and associated with reduced survival, early detection and management of DM in LTx recipients is warranted.

Low Vitamin D diet and the outcome in male C57Bl/6 mice

Kuan Minn Cha¹, Christian Girgis¹, Rebecca Stokes¹, Jenny E Gunton¹

1. Garvan Institute of Medical Research, Darlinghurst, NSW, Australia

BACKGROUND: Vitamin D deficiency is particularly common in winter, when humans tend to gain weight. Vitamin D is also predominantly stored in adipose tissue. Precise effects of vitamin D in adipose tissue are unclear. Low vitamin D due to low diet intake and sun exposure leads to low serum levels of 25-hydroxyvitamin D₃ (25D) which is in turn the substrate for formation of the active 1,25-dihydroxyvitamin D₃ (1,25D). Adipose tissues express VDR and respond to 1,25D.

AIM: To investigate effects of vitamin D deficiency on the activity of male C57Bl/6 mice, their oxidative metabolism and adipose tissue.

METHODS: C57Bl/6 mice were fed low-D or control diet for 48 weeks. This diet contains increased calcium and phosphorus to prevent low calcium and phosphate in the vitamin D deficient state. OxyMax metabolic cage studies were performed. Subcutaneous, visceral and inguinal fat depots were isolated. Immunohistochemistry and gene expression studies were performed.

RESULTS: Vitamin D deficiency mice had higher vO_2 and vCO_2 compared to control mice ($n=4$). These mice also tended to have less visceral fat (0.87 ± 0.10 vs. 1.13 ± 0.11 g; $p=0.085$). In white adipose tissue (WAT), there were 20-fold ($p=0.026$) and 9-fold ($p<0.000001$) increases in UCP1 and CIDEA expression which are markers for brown/beige fat. There were also 7-fold ($p=0.00075$) and 4-fold ($p=0.00015$) increases in TBX and TMEM26 expression which are associated with beige fat.

CONCLUSION: Vitamin D deficiency induces higher metabolic activity in C57Bl/6 male mice and induces 'browning' in WAT. This may be consistent with a physiological response to the vitamin D deficiency which would evolutionarily have been associated with winter and cold exposure.

Identification of SOX9 enhancers disrupted in isolated disorders of sex development

Rajini Sreenivasan^{2,1}, Sabina Benko³, Chris Gordon³, Stefan Bagheri-Fam¹, Stanislas Lyonnet³, Vincent Harley¹

1. MIMR-PHI Institute of Medical Research, Clayton, VIC, Australia

2. Department of Anatomy and Neuroscience, University of Melbourne, Parkville, VIC, Australia

3. INSERM U-781, Hôpital Necker-Enfants Malades, Paris, France

Disorders of sex development (DSDs) are congenital conditions resulting in atypical chromosomal, gonadal or anatomic sex. Around 80% of 46,XY DSD cases still remain unexplained genetically. Phenotypes include gonadal dysgenesis, male-to-female sex reversal and hypospadias, where the urethra is abnormally positioned along the penis. Mutations in SOX9, a gene essential for testicular development, have been implicated in DSDs, but its tissue-specific regulation is not fully understood. SOX9 tissue-specific enhancer mutations can cause isolated clinical phenotypes. Through genome wide mapping, mutations

around SOX9 have been identified in isolated DSD patients. All patients had gonadal defects and hypospadias. We hypothesised that a 78 kb region encompassing these mutations contains a novel gonadal enhancer that we aimed to identify. Comparative genomic analysis identified seven highly conserved sub-regions within TES2. Unexpectedly, transgenic mouse analysis revealed that the most highly conserved sub-region (SR4) was expressed in the genital tubercle (GT; penis primordium) instead of the gonad. Immunofluorescence analysis on mouse GT sections confirmed a novel domain of SOX9 expression within the urethral plate epithelium. These data suggest that loss of SOX9 expression due to SR4 mutations may have contributed to the hypospadias phenotype. To investigate whether SOX9 plays a direct role in hypospadias, we conditionally ablated Sox9 in the GT using mice transgenic for Shh-Cre. Immunofluorescence analysis confirmed loss of SOX9 expression in the urethra of Shh-Cre/+;Sox9^{lox/lox} mice. Abnormal tail and limb development were observed, consistent with the role of Sox9 in bone development. However, preliminary analysis at stages before masculinisation revealed no abnormalities in the GT. GT development in these mice is currently being analysed at later stages. This study may reveal a novel cause of hypospadias. In conclusion, we have identified putative SOX9 enhancers that may be required for human testicular and GT development, the disruption of which cause DSDs.

Circulating IGF1 and IGF2 and SNP genotypes in pregnant and non-pregnant women and men.

Kathy L Gattford¹, Gary K Heinemann¹, Steven D Thompson¹, Jamie V Zhang¹, Julielie A Owens¹, Gustaaf A Dekker¹, Claire T Roberts¹

1. Robinson Research Institute and School of Paediatrics & Reproductive Health, University of Adelaide, Adelaide, SA, Australia
Circulating IGFs are important regulators of postnatal growth and metabolism and of maternal adaptations, fetal and placental growth and function in pregnancy¹. In adults, circulating IGF1 is slightly higher in men than women and IGF2 is similar between sexes, whilst circulating IGF1 but not IGF2 decreases with increasing age. Variable effects of pregnancy on circulating IGFs have been reported, particularly before the third trimester. Single nucleotide polymorphisms (SNPs) in IGF genes or genes that regulate methylation of the IGF2-H19 gene locus also associate with circulating abundance of IGF1 and IGF2 in non-pregnant adults and children²⁻⁵, but whether this occurs in pregnancy is unknown. We therefore investigated associations of circulating IGF1 and IGF2 with age and genotype at these candidate SNPs in men (n=134), non-pregnant women (n=74), and women at 15 weeks' gestation (n=98). Circulating IGF1 decreased ($P < 0.001$) with age, and IGF1 and IGF2 were lower in pregnant than non-pregnant women or men (each $P < 0.001$). SNP genotypes in the IGF2-H19 locus were associated with plasma IGF1 (IGF2 rs680, IGF2 rs1004446 and IGF2 rs3741204; overall regression $P < 0.001$). In single SNP models, associations with IGF2 rs680 were similar in all groups, with higher plasma IGF1 in individuals with the GG than GA ($P = 0.016$) or grouped GA+AA genotypes ($P = 0.003$). SNP genotypes in the IGF2-H19 locus were also associated with plasma IGF2 (IGF2 rs1004446, IGF2 rs3741204 and H19 rs217727; overall regression $P = 0.001$). SNPs in the IGF2 gene associated with IGF1 or IGF2 were in linkage disequilibrium, so these associations could reflect other genotype variation and/or methylation changes within this region. Associations between genotypes in the IGF2-H19 locus and circulating IGF1 and IGF2 concentrations require confirmation in additional independent populations, and do not appear to be affected by pregnancy, which decreases circulating IGFs.

1. Sferuzzi-Perri AN, Owens JA, Pringle KG & Roberts CT (2011) J Physiol 589:7-20
2. Vella A, Bouatia-Naji N, Heude B, Cooper J, Lowe C, Petry C, Ring S, Dunger D, Todd J & Ong K (2008) Diabetologia 51:811-815
3. Albani D, Batelli S, Polito L, Vittori A, Pesaresi M, Gajo G, De Angeli S, Zanardo A, Gallucci M & Forloni G (2009) BMC Geriatrics 9:19
4. O'Dell SD, Miller GJ, Cooper JA, Hindmarsh PC, Pringle PJ, Ford H, Humphries SE & Day INM (1997). Int J Obes Rel Metab Dis 21:822-825
5. Petry C, Ong K, Barratt B, Wingate D, Cordell H, Ring S, Pembrey M, Team TAS, Reik W, Todd J, & Dunger D (2005) BMC Genetics 6:22

Growth restriction reduces offspring plasma leptin concentrations in the absence of changes to amniotic fluid and maternal plasma leptin

Deanne H Hryciw¹, Jessica F Briffa¹, Lisa R Jedwab¹, Tania Romano², Mary E Wlodek¹

1. University of Melbourne, Parkville, VIC, Australia

2. La Trobe University, Bundoora, Victoria

As the adipokine leptin regulates development, we investigated if growth restriction due to uteroplacental insufficiency alters leptin concentrations in maternal and offspring plasma, and amniotic fluid. As leptin can increase urinary albumin/protein and plasma concentrations of pro-fibrotic cytokine TGFb1, we characterised these in maternal urine and plasma. Our hypothesis was that in response to growth restriction, plasma leptin concentrations in offspring born small would be reduced compared to controls. Further that maternal plasma leptin, TGFb1, and urinary protein and albumin would be increased in growth restricted pregnancies.

Female WKY rats were mated and at day 18 of pregnancy (E18) underwent sham surgery or bilateral ligation of the uterine vessels to induce uteroplacental insufficiency. At E20, offspring were sacrificed and maternal urine and plasma and offspring plasma and amniotic fluid collected. Plasma leptin and TGFb1 concentrations were quantified using a leptin and TGFb1 ELISAs, and urinary protein and albumin determined using a BCA assay, and rat albumin ELISA, respectively. In restricted males and females, there was a significant reduction in fetal body weight at E20 compared to controls. In mothers with a restricted pregnancy, there was no change in plasma concentrations of leptin or TGFb1, and no change in total urinary protein. However, there was a significant increase in urinary albumin in mothers with a restricted pregnancy compared to control, which is indicative of early renal dysfunction. Amniotic fluid leptin concentrations were not significantly different in

restricted offspring compared to control, however plasma leptin concentrations were significantly reduced in restricted male and female fetuses compared to controls. Thus, we have demonstrated that growth restriction induced by uteroplacental insufficiency reduces fetal leptin concentrations, which may delay or impair organogenesis. Further, increased maternal albuminuria suggests that compromised placental function in the restricted pregnancy may increase circulating factors essential for normal renal function.

172

Differential effects of insulin-like growth factor binding protein-6 (IGFBP-6) on migration of two ovarian cancer cell lines

Zhiyong Yang¹, Leon Bach^{2,1}

1. Medicine (Alfred), Monash University, Melbourne

2. The Alfred, Melbourne, VIC, Australia

Introduction: We have previously shown that IGFBP-6 inhibits angiogenesis as well as proliferation and survival of rhabdomyosarcoma cells. However, it promotes migration, and binding to prohibitin-2 is involved in this IGF-independent action. The IGF system is implicated in ovarian cancer, so we studied the effects of IGFBP-6 in ovarian cancer cells.

Methods: We defined the effects of IGFBP-6 (both wild type (wt) and a non-IGF-binding mutant (m)) on migration of HEY and SKOV-3 ovarian cancer cells, which respectively represent aggressive and transitional cancers, using a microchemotaxis chamber. Erk and Jnk phosphorylation were measured by Western blotting.

Results: IGF-II, wt- and mIGFBP-6 each promoted SKOV3 cell migration by 77-98% ($p < 0.005$). In contrast, IGF-II increased HEY cell migration to $155 \pm 29\%$ of control ($p < 0.001$), while wtIGFBP-6 and mIGFBP-6 decreased migration to $62 \pm 5\%$ and $66 \pm 3\%$ respectively ($p < 0.001$). In these cells, coincubation with IGF-II significantly increased migration in the presence of wt but not mIGFBP-6.

We have previously shown that MAP kinase pathways are involved in IGFBP-6-induced rhabdomyosarcoma cell migration, so we compared activation of these pathways in HEY and SKOV3 cells. Wt and mIGFBP-6 increased Erk phosphorylation by 62-100% in both cell lines ($p < 0.05$). WtIGFBP-6 also increased Jnk phosphorylation by 138-153% in both cell lines ($p < 0.05$), but the effect of mIGFBP-6 was less clear. Erk and Jnk pathways inhibitors partially reversed IGFBP-6-induced effects on migration.

Conclusions: IGFBP-6 has opposing effects on migration of HEY and SKOV3 ovarian cancer cells, but activates MAP kinase pathways in both. Delineating the pathways underlying the differential effects on migration will increase our understanding of ovarian cancer metastasis and shed new light on the IGF-independent effects of IGFBP-6, which may in turn lead to the development of an optimized IGFBP-6-based therapeutic that is antitumorigenic and not promigratory.

173

Assessment of ovarian cancer spheroid invasion of mesothelial cells in real time: profiling the molecular signature of the invasive interface.

Kaye L Stenvers¹, Adam Rainczuk¹, Andrew Stephens¹, Nicole Fairweather¹, Thomas Jobling², Maree Bilandzic¹

1. MIMR-PHI Institute of Medical Research, Clayton, VIC, Australia

2. Gynaecological Oncology, Monash Health, Moorabbin, VIC, Australia

Background: Ovarian cancer is the most common cause of death from gynaecological cancer worldwide (1). Unlike other solid cancers, ovarian cancer cells rarely spread via the vasculature, instead disseminating within the peritoneal fluid or ascites (2). Invading ovarian cancer cells interact with mesothelial cells lining the peritoneum, attach to, and invade the basement membrane to establish secondary lesions (3). The molecular events at this 'invasive interface' have been poorly studied. Therefore, we aimed to: *i*) develop an innovative method to co-culture ascites-derived ovarian cancer cells and measure invasion through peritoneal mesothelial cell layers in real time (4); *ii*) identify the unique protein expression profile at the ovarian spheroid-peritoneal interface during early invasion using proteomics.

Methods: Real Time Cell Analysis technology was adapted to establish a three-dimensional co-culture model of the tumor microenvironment of the peritoneum (4). Multicellular spheroids were generated from primary ovarian cancer lines or benign ascites derived cells cultured under non-adherent conditions. Real time measurements were conducted to determine the precise period when invasion commenced. Parallel cultures were histologically preserved at invasion initiation and processed for assessment by *Matrix-Assisted Laser Desorption/Ionization (MALDI) imaging*.

Results: Continuous real time measurements revealed that individual ovarian cancer samples exhibited differences in the timing of the onset of invasion. High-grade serous carcinoma samples initiated invasion rapidly after addition, some in under 30 min. MALDI imaging identified peptides expressed at the tumor-mesothelial interface during early invasion. These molecules represent novel molecules involved in the initiation of the metastatic process and are the subject of further characterisation.

Conclusion: This method represents a high-throughput quantitative analysis of ovarian cancer spheroid invasion of mesothelial and ECM barriers. The study has provided an unprecedented insight into the molecular mechanisms involved in the initiation of ovarian cancer invasion of the mesothelium, identifying new therapeutic targets.

1. Marsha Rivkin Centre for Ovarian Cancer Research, Facts and Figures, 2014.
2. Ahmed N et al., *Front Oncol.* 2013;3(256).
3. Kenny HA et al., *Int J Cancer.* 2007 Oct, 1;121(7):1463-72.
4. Bilandzic M and Stenvers K., *Journal of Visual Experimentation.* 2014 20/05/2014 (87).

The Mineralocorticoid Receptor plays a role in Mammary Tissue Development

Ann E Drummond¹, Morag J Young¹, Kyren Lazarus¹, John W Funder¹, Evan R Simpson¹, Colin Clyne¹, Peter J Leedman², Wayne D Tilley³, George E Muscat⁴, Christine L Clarke⁵, Peter J Fuller¹

1. MIMR-PHI Research Institute / Monash University, Clayton, Victoria, Australia

2. Harry Perkins Institute of Medical research, Nedlands, WA, Australia

3. University of Adelaide/Hanson Institute, Adelaide, SA, Australia

4. Institute for Molecular Biosciences, Brisbane, Queensland, Australia

5. Westmead Millennium Institute, Westmead, NSW, Australia

The role of the mineralocorticoid receptor (MR) in salt and water balance is well established. What remains less clear is its role in non classical tissues. Recently, we identified the MR as a discriminator between normal human breast, ER positive (ER+) and ER negative (ER-) breast cancers; their loss in breast cancer argues for a role of the MR as a "tumour suppressor". To investigate the hypothesis that the MR plays a central role in breast biology, perhaps as a receptor for progesterone, we established a colony of mammary tissue-specific MR-null mice.

A mammary tissue-specific MR-null mouse was generated by crossing MMTVcre mice (provided by Prof Jane Visvador, WEHI) with our MR floxed mice. Breeding proceeded normally and gave rise to litters of healthy pups with the expected Mendelian ratios. Mammary tissue (4th inguinal glands) was collected from null mice and littermate controls at 8 weeks of age for histological analyses. Mammary tissue was fixed with Carnoy's for whole mount analysis and formalin for MR immunohistochemistry. Formal confirmation of the knockout will be provided by MR immunohistochemistry using an MR-specific mouse monoclonal antibody. These studies will be the first to localise MR protein to cells within the mammary tissue of mice; we are currently optimising the protocol. At 8 weeks of age the knockout mammary tissue was poorly developed relative to controls as indicated by reduced branching and overall length, supporting a role for the MR in mammary development.

Studies to investigate additional developmental time points and the role of the MR in mammary tissue during pregnancy and lactation are ongoing. Data collected from these studies may provide the basis for the development of novel treatments/therapies for breast cancer.

Paternal transmission of metabolic and cardio-renal dysfunction to offspring born to a growth restricted father

Mary E Wlodek¹, Tina N Hosseini¹, Andrew J Jefferies¹, Yasmin Asif², Paul Soeding³, Karen M Moritz⁴

1. Physiology, University of Melbourne, Parkville, VIC, Australia

2. Centre for Physical Activity and Nutrition Research, School of Exercise and Nutrition Sciences, Deakin University, Burwood, VIC, Australia

3. Pharmacology, University of Melbourne, Parkville, VIC, Australia

4. School of Biomedical Sciences, University of Queensland, St Lucia, QLD, Australia

Being born small increases cardio-renal and metabolic disease risk which are not limited to the first generation (F1) but can be transmitted to the next generation (F2) with limited evidence of paternal line transmission. We characterised cardio-renal and metabolic phenotype of F2 offspring born to normally grown and growth restricted (F1) fathers.

Late gestation rat uteroplacental insufficiency was induced (Restricted) or sham (Control) surgery in F0. F1 males were mated with normal females. F2 offspring body weight was not different at birth. Males, but not females, from Restricted fathers had altered glucose control following an IPGTT at 6 months (higher area under glucose curve; reduced first phase insulin secretion). Creatinine clearance was reduced in Restricted males at 6 months. Restricted F2 males had evidence of increased left ventricular wall thickness (+10%), left ventricular hypertrophy (+10% at post mortem) and concentric remodelling (echocardiography) which emerged at 16 months in the absence of altered heart contractility. Tail cuff blood pressure was not different at 6, 9, 12 and 16 months of age. Systolic and mean arterial blood pressure (telemetry) at 16 months, was increased during both 12h light and 12h dark periods and was elevated in response to restraint stress (at 30 minutes) and sustained into the early recovery period.

F2 offspring, born to F1 growth restricted fathers are not programmed to be born of low birth weight but developed altered glucose control in the absence of obesity. Male offspring developed concentric remodelling, left ventricular hypertrophy and high blood pressure at 16 months. Our findings provide novel evidence of transmission of metabolic effects as well as signs of an adverse cardiovascular phenotype with aging in F2 males via the paternal line in an uteroplacental insufficiency model of growth restriction. Females were protected from these programmed disease risks.

Influence of maternal stress during pregnancy in low birth weight females on F2 male bone outcomes

Kristina Anevska^{2,1}, Jean N Cheong², Andrew J Jefferies², John D Wark³, Karen M Moritz⁴, Brian L Grills¹, Tania Romano¹, Mary E Wlodek²

1. Department of Human Biosciences, La Trobe University, Melbourne, VIC, Australia

2. Department of Physiology, University of Melbourne, Melbourne, VIC, Australia

3. Department of Medicine, The University of Melbourne and Bone and Mineral Medicine, Royal Melbourne Hospital, Melbourne, VIC, Australia

Males of low birth weight have programmed adult bone deficits. Disease development due to low birth weight is not limited to the first directly exposed generation (F1) but has the potential to transmit to subsequent generations. We examined bone health from postnatal life to late adulthood in F2 male rats born to normal birth weight or growth restricted mothers (F1) and assessed the effects of maternal stress during pregnancy.

During late gestation in the female rat, uteroplacental insufficiency was induced by bilateral uterine vessel ligation (Restricted) or sham (Control) surgery in the F0 generation. F1 females were mated and randomly allocated to an Unstressed or Stressed (24 h metabolic cage, tail-cuff blood pressure, glucose tolerance test) pregnancy groups.

F2 offspring born to mothers who experienced stress during their pregnancy were lighter at birth (4-6%). Compared to F2 Control Unstressed males, low maternal birth weight (Restricted Unstressed) as well as maternal stress in pregnancy (Control and Restricted Stressed) led to the development of deficits at day 35 in cortical content (-15-18%), cortical density (-4-6%) and Y-axis stress strain index (-22-25%) in males. At 6 months of age, these deficits in content and density were ameliorated. Maternal stress, regardless of maternal birth weight, programmed decreased trabecular density (-6%) at 6 months, while periosteal circumference and Y-axis stress strain index were increased (3-7%) in Restricted male offspring independent of maternal stress. No deficits were apparent at 12 months. Maternal stress, independent of maternal birth weight, programmed deficits in endosteal and periosteal circumferences (-5-13%) and decreased X-axis stress strain index (-5%) at 16 months.

Maternal low birth weight, programs postnatal bone deficits in the next generation. Stress during pregnancy, programmed males to develop adult bone deficits, independent of maternal birth weight.

Pre-weaning growth hormone treatment reverses programming effects in offspring following maternal undernutrition

Minglan Li^{1,2}, Clare Reynolds^{1,2}, Clint Gray^{1,2}, Mark Vickers^{1,2}

1. Liggins Institute, University of Auckland, Auckland, New Zealand

2. Gravidia: National Centre for Growth and Development, Auckland, New Zealand

Background

Dysregulation in the growth hormone/insulin-like growth factor-1 (GH-IGF-1) axis may play an important role in the developmental programming of metabolic disorders in adult offspring following maternal undernutrition (UN). We investigated whether pre-weaning GH treatment can reverse or ameliorate the programming effects in offspring following maternal undernutrition.

Methods

Female Sprague Dawley rats were fed either a chow diet ad-libitum (C) or 50% of ad-libitum (UN) throughout pregnancy. Litters were adjusted to 8 pups and all mothers fed chow ad-libitum after birth. From postnatal day 3, C and UN pups received either saline (CS and UNS) or GH (2.5ug/g/day, CGH and UNGH) daily throughout lactation. After weaning, 4 offspring (2 male and 2 female) were randomly selected from each litter and fed the chow diet for the remainder of the study (150 days). Body weights were recorded regularly. Plasma and liver tissue were collected from adult offspring for cytokine and gene expression analysis.

Results

Pre-weaning GH treatment significantly reduced catch-up growth observed in male and female UN animals. Hepatic growth hormone receptor (GHR) expression was significantly increased in UNS offspring and normalised in male and female UNGH offspring. Hepatic IGFBP2 gene expression was significantly decreased in male and female UNS offspring and normalised by GH treatment in both sexes. Plasma IGF-1:IGFBP3 ratio was significantly increased in male and female UNS offspring compared to controls and was reduced in UNGH offspring. Plasma leptin levels were significantly elevated in female UNS offspring, reflective of an increased fat mass, and were normalised in UNGH offspring.

Conclusions

Our findings suggest that GH treatment during a critical developmental window might prevent maternal UN-induced catch-up growth and later adiposity and provides evidence that manipulation of the GH-IGF1 axis in early development may be a promising strategy to prevent adverse developmental programming effects in later life.

GLP-1 receptor agonist Exendin-4 ameliorates oxidative stress and inflammation in offspring's kidneys induced by maternal obesity

Sarah Glastras¹, Hui Chen², Sonia Saad¹, Carol Pollock¹

1. Kolling Institute, RNSH, St Leonards, NSW, Australia

2. University of Technology, Sydney, NSW, Australia

Maternal obesity increases the risk of chronic disease in the offspring, including diabetes, hypertension and cardiovascular disease. Developmental programming may also affect offspring's risk of chronic kidney disease. GLP-1 receptor agonists, such as Exendin-4 are effective blood glucose lowering agents and achieve modest weight loss in the setting of type 2 diabetes. They may also have beneficial effects on the kidney. We hypothesized that administration of Exendin 4 (Exd-4) may reduce inflammation and oxidative stress in the kidneys of offspring of obese mothers.

Method: Female rats were fed either normal or high-fat diet (HFD) for 6 weeks prior to pregnancy, during pregnancy and lactation and their offspring were weaned to normal or HFD. The offspring were randomised to Exd-4 or placebo at weaning and their kidneys harvested in early adulthood.

Results: Offspring of obese mothers fed HFD had increased weight and reduced glucose tolerance. Exd-4 significantly ameliorated these effects. The kidneys of offspring of obese mothers, regardless of postnatal diet, had increased markers of inflammation and oxidative stress. By RT-PCR, mRNA expression of inflammatory markers, monocyte chemoattractant protein -1 (MCP-1) and transforming growth factor was significantly increased in offspring of obese mothers regardless of postnatal

diet. Increased MCP-1 mRNA expression in offspring of obese mothers fed HFD was ameliorated by Exd-4. Inducible nitric oxide synthase mRNA, a measure of oxidative stress, was increased by maternal obesity with or without HFD consumption in postnatal life and ameliorated by Exd-4 therapy. Superoxide dismutase (SOD) are enzymes with important anti-oxidant and anti-inflammatory effects. Exd-4 increased SOD activity significantly in the offspring of obese mothers fed normal diet.

Conclusion: We conclude that maternal obesity affects inflammatory and oxidative stress pathways within offspring's kidneys. Exd-4 appears to have a novel protective role against the deleterious renal effects of *in utero* exposure to maternal obesity.

188

Influence of uteroplacental insufficiency on blood pressure and arterial wall stiffness in first and second generation aged male rats.

Jean N Cheong¹, Maria Jelinic², Andrew J Jefferies¹, Antonio Pre¹, Laura J Parry², Karen M Moritz³, Mary E Wlodek¹

1. Department of Physiology, The University of Melbourne, Parkville, Victoria, Australia

2. Department of Zoology, The University of Melbourne, Parkville, Victoria, Australia

3. School of Biomedical Sciences, University of Queensland, St. Lucia, Queensland, Australia

Intrauterine growth restriction increases the risk of cardiovascular disease, with males exhibiting a more severe phenotype than females. These disease risks in the first, directly exposed generation (F1) may be transmitted to the next generation (F2). Maternal stress during pregnancy impacts fetal development, however, its effect on mothers who were born small is not understood. We characterised the cardiovascular phenotype of F1 growth restricted males and F2 males born to growth restricted F1 mothers. We also determined whether F1 maternal stress during late pregnancy exacerbates the F2 phenotype.

Late gestation uteroplacental insufficiency was induced on E18 of pregnancy by bilateral uterine vessel ligation (Restricted) or sham (Control) surgery in F0 females to generate F1 males. F1 female offspring (Control, Restricted) were mated with a male rat and allocated to Unstressed or Stressed groups. Physiological stressors (24h metabolic cage, tail cuff blood pressure, glucose tolerance test) were introduced during late pregnancy in the Stressed group. Body weights were measured from birth and tail cuff blood pressure measured to 16 months (mo). At 14-16mo arterial stiffness of small renal and mesenteric arteries was assessed using pressure myography.

Restricted F1 males had reduced birth weight (-18%) with no differences in blood pressure. F2 males born to Control or Restricted F1 mothers exposed to maternal stress had reduced birth weight (-4-6%). Restricted Unstressed males had higher blood pressure (6,12mo) compared to Control Unstressed. Control Stressed male offspring had elevated blood pressure (6,9,12mo) compared to Control Unstressed. However, arterial wall stiffness did not differ in both F1 and F2 males.

F1 growth restricted males had normal blood pressure and arterial wall stiffness although they were born of a lower birth weight. F2 males were born small if their mothers experienced maternal stress. The second hit of maternal stress programmed hypertension without influencing arterial wall stiffness.

192

Food, microbes and you – what you can learn from your poo

Andrew Holmes¹

1. School of Molecular Bioscience & Charles Perkins Centre, University of Sydney, NSW, Australia

Our gut houses the microbiological equivalent of a large biodynamic vegetable patch that has a profound effect on our health. The old adage "You are what you eat", could perhaps be, "You are what you grow in your gut garden". Our *gut microbiome*, is the 1000 or so species of microbe that are normally present for most of our life. Our microbiome is a bit like our genome in that each of us has a unique microbiome and it encodes basic properties that influence our health and well-being. A key difference is that we acquire our genome more or less instantaneously at conception and are stuck with it for life. In contrast we acquire our microbiome over a far more protracted period and it is more malleable – for good or for bad. Studies comparing the microbiome of healthy and sick people have revealed a wide range of metabolic, immunological and even neuropsychiatric conditions where a dysfunctional microbiome is part of the underlying problem. We are exploring forces that shape host-microbiome interaction in mouse and human models with a view to developing intervention strategies across a range of such dysbioses. A systematic exploration of nutrient intake in mice has shown that feeding behaviour and diet composition interact to alter microbial community composition in a predictable fashion. Our model is that the nutritional landscape sets a framework in which host-microbe interactions that lead to pathophysiological outcomes including visceral inflammation and metabolic dysfunction occur. This gives rise to two basic, and synergistic, opportunities for improving healthcare in diseases involving dysbiosis: Microbiome profiling to provide diagnoses that inform personalized intervention strategies, and; Modulation of host-microbiome interaction to improve health.

193

How the central melanocortin neurons control peripheral blood glucose.

Stephanie Simonds¹, Michael E Cowley¹

1. Monash University, Clayton, Vic, Australia

Diabetes rates are continuing to increase globally, and there remains an unmet need for new therapies. We also have an incomplete understanding of how blood glucose levels are regulated. In particular it has recently emerged that the brain can have a significant effect on blood glucose. Both peripheral and central mechanisms control the production of blood glucose from the liver and the uptake of glucose by muscles and other organs. The central melanocortin system has been implicated in the regulation of blood glucose, but the exact mechanism by which these neurons regulate glucose levels is not yet known. In research presented here we use engineered pharmacological selective chimeric ion channels, activating and inhibiting

populations of key hypothalamic arcuate neurons, including POMC, AgRP and NPY neurons in mice and examine the impact of these electrical changes on blood glucose. We have established that these neurons are differentially important in the control of blood glucose in the feed and fasted state. Activating POMC neurons causes an improved response to a glucose challenge during a glucose tolerance test ($p < 0.05$, $n = 5-8$). Activation of AgRP neurons causes a reduced glucose tolerant response following a glucose challenge ($p < 0.05$, $n = 5-8$). In fasted mice, simply activating the AgRP neurons or inhibiting the POMC neurons can increase basal blood glucose ($p < 0.05$, $n = 6$). We have also established that PYY can directly regulate glucose homeostasis. These actions of PYY are at least partially through the melanocortin neurons, particularly AgRP. The ability of these hypothalamic neurons to control blood glucose is altered in obesity, with differences existing between lean and obese mice. This research provides new insight into how the melanocortin system regulates blood glucose, and may provide new targets for therapies to control blood glucose.

194

Acute inhibition of casein kinase 1 δ/ϵ rapidly resets central and peripheral clock gene rhythms

Michael J Boden¹, Tamara J Varcoe¹, Athena Voultsios¹, Mark D Salkeld¹, Leewen Rattanatr¹, David J Kennaway¹

1. Robinson Research Institute, University of Adelaide, Adelaide, SA, Australia

Circadian rhythms regulate changes in energy metabolism and behaviour that occur across 24 hours. These rhythms are generated through interlocked transcription/translation feedback loops involving clock genes and their protein products and disruption of these rhythms leads to impaired metabolic function. Key to maintaining this 24 hour cycle is the phosphorylation of the Period proteins by casein kinase 1 δ/ϵ . The effects of the casein kinase inhibitor PF-670462 (50mg/kg) on the rhythmic expression of clock and other genes in the liver, pancreas and the suprachiasmatic nucleus of the brain were assessed in rats (5wks, $n = 5$ per group/time point) and compared to the responses to a 4-hour extension of the light phase. The changes in plasma corticosterone, melatonin and running behaviour were also evaluated.

PF-670462 acutely phase delayed the rhythmic transcription of *Bmal1*, *Per1*, *Per2* and *Nr1d1* in both liver and pancreas by 4.5 ± 1.3 hours and 4.5 ± 1.2 hours respectively 1 day after administration. In the suprachiasmatic nucleus, the rhythm of *Nr1d1* and *Dbp* mRNA expression was delayed by 4.2 and 4 hours respectively. Liver expression of *Pfkfb2* and *Pck1* mRNA was delayed by 1.9 and 0.9 hours respectively, coinciding with a 2.1 hour delay in peak corticosterone secretion. Peak melatonin secretion was unchanged, while the onset of wheel running activity was delayed by 1.1 hours. These changes are in contrast to the effects of a 4-hour extension of the light phase, which delayed the peak expression of the clock genes by less than 1 hour, with no change in the corticosterone rhythm. The ability to drive large phase shifts in major metabolic tissues through inhibition of casein kinase 1 δ/ϵ highlights a pathway to rapidly adjust circadian rhythms. By developing new drugs targeting these kinases, it may be possible to alleviate the metabolic disruption induced by shift work.

195

Differential roles of central and peripheral α -melanocyte stimulating hormone in transient hyperglycemic mice

Weiyi Chen¹, Pablo J Enrriori¹, Michael A Cowley¹

1. Monash University, Clayton, VIC, Australia

Type 1 diabetes represents 10 – 15 % of all cases of diabetes in Australia and it remains a management challenge partly because insulin is lipogenic. Over the years, a number of studies have shown the physiology role of peripheral melanocortin peptides, in particular α -melanocyte stimulating hormone (α -MSH) in lipid metabolism. However, the role of systemic α -MSH in glucose homeostasis has not been evaluated. Here, we explore the central and peripheral effects of α -MSH in transient hyperglycemic mice *in vivo*.

We were able to induce hyperglycemia (21.9 ± 2.5 mmol/l) in lean mice after 1 day of insulin receptor antagonist (20nmol/kg of S961; NovoNordisk, Denmark) delivery via subcutaneous osmotic (7 days, 0.5 μ l/h) pumps. Hyperglycemia was further increased and maintained at 27.1 ± 2.7 mmol/l in these mice after 4 days of S961 (20nmol/kg). Interestingly, constant intravenous infusion of α -MSH (1 μ g/h) for 2h was able to improve the hyperglycemic condition from 28.4mmol/l to 22.3 mmol/l relative to the control group (29.2mmol/l to 26.7mmol/l), albeit the blood glucose remained elevated. To bolster this finding, systemic α -MSH (1 μ g/h) delivery during a 2h hyperinsulinemic-euglycemic clamp in lean mice showed a significant increase in glucose infusion rate (Control: 57.3 \pm 6.7 mg/kg/min, α -MSH: 70.3 \pm 4.7 mg/kg/min, $p < 0.01$) and whole body glucose turnover (Control: 54.2 \pm 4.2 mg/kg/min, α -MSH: 63.9 \pm 5.2 mg/kg/min, $p < 0.05$). Notably, insulin-mediated glucose disposal rate was not altered showing the additive effect of α -MSH in mediating glucose disposal in skeletal muscle.

A single intracerebroventricular (icv) injection of α -MSH did not alter the glucose tolerance tests in lean mice. Furthermore, hyperglycemia remains unaltered when α -MSH was delivered centrally in S961-treated mice. Collectively, these findings support the notion that peripheral α -MSH is involved in whole body glucose homeostasis independent of insulin. In addition, this study unveils a key role of α -MSH to improve insulin deficiency associated with type 1 diabetes.

196

Loss of the peripheral molecular clock blunts the cardiac response to mineralocorticoid induced cardiovascular disease

Elizabeth K Fletcher^{1,2}, James Morgan¹, Lea M Delbridge², Morag J Young¹

1. Cardiovascular Endocrinology Laboratory, MIMR-PHI Institute of Medical Research, Clayton, Vic, Australia

2. Cardiac Phenomics Laboratory, Department of Physiology, University of Melbourne, Melbourne, Vic, Australia

Clinical and experimental studies demonstrate that activation of the mineralocorticoid receptor (MR) in the heart leads to increased inflammation, fibrosis and endothelial dysfunction. These effects can be abrogated by MR antagonists. MR antagonists however, have limited use due to negative side effects. Consequently the identification of cell-specific MR signalling mechanisms may allow for the development of more specific cardiac MR antagonists. One potential mechanism downstream of MR is the peripheral molecular clock (PMC). The molecular clock is a transcriptional translational feedback loop comprising of core "clock genes" which bind to and regulate numerous downstream cardiac genes. Dysregulation of the peripheral molecular clock genes in the heart leads to altered transcription of cardiac target genes, contributing to many aspects of cardiovascular disease. We hypothesize that activation of cardiomyocyte MR leads to dysregulation of the peripheral molecular clock resulting in cardiac inflammation, fibrosis and dysfunction.

Uninephrectomised 8wk old male wild type and Clock Δ 19^{me/+} (CLK) mice were maintained on 0.9% saline without (VEH) or with deoxycorticosterone (DOC) 7mg/week pellet (n=8-11). Systolic blood pressure (SBP) was recorded at eight weeks. Heart tissue was analyzed for inflammation: macrophage and CD3+ T-cell recruitment, and fibrosis. Quantitative RT PCR was used to assess expression of PMC genes and cardiac markers of fibrosis and inflammation in the whole heart.

Results showed that inflammation and fibrosis are elevated in CLK-VEH mice compared to WT-VEH (macrophages 34%, and tissue collagen 35%), while WT-DOC was blunted when compared to CLK-DOC due to an elevated CLK-VEH baseline. SBP was blunted in CLK-DOC mice by decreased activated renal macrophages, while regulation of PMC genes in response to DOC/salt was lost in CLK mice.

Loss of the peripheral molecular clock increases inflammation and fibrosis, but blunts the response to DOC/salt. While SBP is normal in CLK mice, the pressor response to DOC/salt is lost.

197

Central stimulation of GH secretion by testosterone in men is mediated by aromatisation to oestrogen

Vita Birzniece^{1, 2, 3}, **Ken Ho**^{1, 4}

1. Garvan Institute of Medical Research, Darlinghurst, NSW, Australia

2. UNSW, Sydney, NSW, Australia

3. University of Western Sydney, Penrith, NSW, Australia

4. Centres for Health Research, Princess Alexandra Hospital, Brisbane, Qld, Australia

Some testosterone effects are regulated at a local tissue level by aromatisation to oestrogen. Testosterone stimulates GH secretion in men, an effect attenuated by tamoxifen (a SERM with central oestrogen receptor antagonistic and peripheral agonistic effect). It is unclear whether the blunting of testosterone-induced GH secretion by tamoxifen stems from oestrogen receptor modulation or blockade from aromatised oestrogens.

Objective: To investigate whether aromatase inhibition blunts the GH-IGF-I axis in healthy men. Design: We compared the effects of letrozole, an aromatase inhibitor, and tamoxifen in an open-label cross-over study. Eight healthy men (BMI 25.5 kg/m², age 59±1 y) received 2-week sequential treatments with tamoxifen (20 mg/d) and letrozole (2.5 mg/d) with a 4-week intervening washout period.

Outcome Measures: The GH response to arginine stimulation, and circulating levels of IGF-I, LH, testosterone. Results: Letrozole significantly (p<0.05) reduced the peak GH response to arginine by 49±18%. Tamoxifen induced a small non-statistically significant reduction of peak GH response by 19±26% (p=0.1). The reduction in GH was significantly greater with letrozole. Both treatments significantly reduced mean circulating IGF-I levels, with tamoxifen having a significantly greater effect (Δ -34±3 vs -23±4%; p<0.05). Both drugs significantly increased LH and testosterone concentrations. The mean increases in testosterone (102% vs 32%; p<0.01) and LH (188% vs 37%; p<0.001) were significantly greater with letrozole than with tamoxifen treatment.

Summary and Conclusion: At the doses used, letrozole but not tamoxifen significantly reduced GH secretion, however tamoxifen reduced IGF-I to a greater degree. Both drugs stimulated the gonadal axis. We conclude that stimulation of the GH-IGF-I axis by testosterone is mediated centrally by oestrogens from aromatisation, as is the suppression of the gonadal axis. As oestrogens inhibit hepatic IGF-I production, the reduction of IGF-I by tamoxifen is mediated by an oestrogen effect on the liver.

Supported by the Princess Alexandra Hospital Research Support Scheme and NHMRC.

198

Electrophysiological and pharmacological profile of Gonadotropin Inhibitory Hormone-expressing neurons in the rat.

Jack T Pryor¹, **Ishwar S Parhar**², **David C Spanswick**^{1, 3}, **Iain J Clarke**³

1. University of Warwick, Clayton, VIC, Australia

2. Brain Research Institute, School of Medicine and Health Sciences, Monash University Sunway Campus, Selangor, Malaysia

3. Department of Physiology, Monash Obesity and Diabetes Institute, Monash University, Melbourne, Australia

Gonadotropin Inhibitory Hormone (GnIH) expressing neurons, through projections and interactions with gonadotropin releasing hormone (GnRH)-expressing and POMC-expressing neurons in the arcuate nucleus of the hypothalamus are suggested to serve as a fulcrum for neuroendocrine regulation of reproduction and appetite. Relatively little is known of the intrinsic membrane and extrinsic synaptic mechanisms regulating activity of GnIH neurons. Here, using the whole-cell patch clamp technique, the electrophysiological and pharmacological profile of GFP-labelled GnIH neurons has been investigated in rats *in vitro*.

Whole-cell recordings were obtained from 35 GnIH-GFP expressing neurons of the rat dorsomedial hypothalamus (DMH). Passive membrane properties included a mean resting membrane potential, firing rate and input resistance of 39.3 ± 0.7 mV, 0.94 ± 0.18 Hz and 1489 ± 98 m Ω , respectively. DMH GnIH neurons expressed: a 4-AP-sensitive transient outward rectification

in 91% neurons; a Cs⁺-sensitive hyperpolarisation activated conductance in 57% of neurons; a Ni²⁺ sensitive T-type calcium conductance found in 74% of GnIH neurons. The AMPA receptor antagonist NBQX (10mM; n=5) and the GABA receptor antagonist bicuculline (20mM; n=5) revealed both GABAergic and glutamatergic synaptic connections to GnIH neurons.

Thyrotropin-releasing hormone (TRH; 400nM) induced depolarisation in all neurons tested (n=7) associated with a decrease in input resistance and reversal potential around 0mV, indicating activation of a non-selective cation conductance. Conversely, 5-HT (50mM) induced membrane hyperpolarisation 9 of 14 neurons, associated with a decrease in input resistance and reversal potential around -90mV consistent with activation of one or more K⁺ conductances. 5-HT-induced depolarisation in 5 neurons was associated with an increase in input resistance and reversal potential around -90 mV, suggesting block of one or more K⁺ conductances.

These data provide the first description of the intrinsic membrane properties and extrinsic synaptic/neuromodulatory mechanisms regulating excitability of GnIH neurons.

Sex steroid levels in chronic kidney disease, dialysis and kidney transplant recipients

Mathis Grossmann¹, **Rudolf Hoermann**², **Mark Ng Tang Fui**², **Jeffrey Zajac**², **Francesco Ierino**³, **Matthew Roberts**⁴

1.University of Melbourne, Austin Health, Heidelberg, VIC, Australia

2.University of Melbourne Austin Health, Heidelberg, VIC, Australia

3.Renal Unit, Austin Health, Heidelberg, VIC

4.Renal Medicine, Eastern Health Clinical School, Monash University, Box Hill, VIC

Background: We hypothesized that levels of circulating sex steroids *i)* change with stages of chronic kidney disease (CKD) and *ii)* are associated with clinical outcomes.

Methods: We conducted a prospective observational study. 221 patients (143 males, 78 females) with CKD comprising 49 patients with CKD III-IV, 102 dialysis patients, and 70 kidney transplant recipients (KTR) were followed at a tertiary referral centre to death or kidney transplant. Baseline serum sex steroid levels were repeatedly measured by liquid chromatography/tandem mass spectrometry.

Results: In males, but not in females, both testosterone (p=0.003) as well as estradiol (p<0.02) levels were lowest in dialysis patients and highest in KTR. Over a median follow up of 8.5 years (interquartile range 3.8-9.2), 52 men (36%) died, and 24 (17%) received a kidney transplant. In multivariate analyses using Cox proportional hazard models up to 9.6 years, testosterone predicted mortality independent of baseline age, body mass index, and renal disease status (p=0.02), and circulating levels of brain natriuretic peptides or cardiac troponin T (p<0.05). An increase in testosterone by 1 nmol/L was associated with a 9.8% (95% confidence interval 3.1-16.3%) decrease in mortality. By contrast, sex steroid levels were not associated with mortality in females.

Conclusions: Low testosterone levels predict mortality in males, independent of established and novel predictors of mortality in CKD.

Higher bone remodelling rates are associated with reduced diabetes risk and lower estradiol concentrations in older men.

Bu B Yeap^{1,2}, **Helman Alfonso**³, **Paul Chubb**⁴, **Richard Gauci**², **Elizabeth Byrnes**⁵, **John P Beilby**⁶, **David J Handelsman**⁷, **Peter R Ebeling**⁸, **Leon Flicker**^{9,1}, **Paul E Norman**¹⁰

1.School of Medicine and Pharmacology, University of Western Australia, Perth, WA, Australia

2.Department of Endocrinology and Diabetes, Fremantle and Fiona Stanley Hospitals, Perth, WA, Australia

3.School of Public Health, Curtin University, Perth, WA, Australia

4.PathWest Laboratory Medicine, Fremantle and Royal Perth Hospitals, Perth, WA, Australia

5.PathWest Laboratory Medicine, Sir Charles Gairdner Hospital, Perth, WA, Australia

6.PathWest Laboratory Medicine, Sir Charles Gairdner Hospital, Perth, WA, Australia

7.ANZAC Research Institute, University of Sydney, Sydney, NSW, Australia

8.Department of Medicine, Monash University, Melbourne, Victoria, Australia

9.WA Centre for Health and Ageing, University of Western Australia, Perth, WA, Australia

10. School of Surgery, University of Western Australia, Perth, WA, Australia

Context

Osteocalcin (OC) is an osteoblast-derived peptide circulating in undercarboxylated and γ -carboxylated forms. In mice undercarboxylated osteocalcin (ucOC) modulates insulin secretion and sensitivity, and increases testosterone (T) secretion from Leydig cells. Its relevance to humans is unclear.

Objective

We examined cross-sectional associations of ucOC, total OC and other bone turnover markers with diabetes and sex hormones.

Participants

Community-dwelling men aged 70-89 years resident in Perth, Western Australia.

Outcome measures

Serum total OC, N-terminal propeptide of type I collagen (P1NP) and collagen type I C-terminal cross-linked telopeptide (CTX) were measured by immunoassay, and uOC by hydroxyapatite binding. T and estradiol (E2) were assayed by mass spectrometry in early morning samples.

Results

There were 2,966 men in the analysis after excluding men with osteoporosis, on bisphosphonates, glucocorticoids or warfarin, and conditions or medications affecting sex hormones. After adjusting for age, smoking, BMI, waist-hip ratio, hypertension, dyslipidemia, creatinine, vitamin D and medical comorbidities, higher uOC was associated with reduced prevalence of diabetes (odds ratio [OR]=0.55, 95% confidence interval [CI]=0.47-0.64, $p<0.001$ per 1 SD increase uOC). Similar results were seen for total OC (OR=0.60, 95% CI=0.50-0.72, $p<0.001$), P1NP (0.64, 0.54-0.76, $p<0.001$) and CTX (0.60, 0.52-0.69, $p<0.001$) but not uOC/total OC. E2 was inversely associated with uOC (coefficient -0.04, $p=0.031$), total OC (-0.05, $p=0.001$) and CTX (-0.04, $p=0.016$); and positively with uOC/total OC (0.05, $p=0.002$). T was not associated with uOC, total OC, P1NP, CTX or uOC/total OC (all $p>0.05$).

Conclusions

Higher bone remodelling rates are associated with reduced diabetes risk in older men. Although higher uOC is associated with reduced diabetes risk, it acts as a marker of increased bone remodelling rate, rather than possessing a specific effect. E2, but not T, is inversely associated with bone turnover markers. We found no evidence uOC, or uOC/total OC modulates circulating T in men.

201

Serum Activin A, B and follistatin levels provide novel markers of Chronic Fatigue Syndrome (CFS) patients.

David de Kretser¹, Susan Hayward¹, Adnan Sali¹, Brett A Lidbury², Don P Lewis³, Badia Kita⁴, Mark P Hedger¹

1. Monash University, Clayton, Vic, Australia

2. Genome Biology, The John Curtin School of Medical Research, Australian National University, Canberra, ACT, Australia

3. CFS Discovery, Melbourne, Victoria, Australia

4. Paranta Biosciences, Melbourne, Victoria

Patients with symptoms of Chronic Fatigue Syndrome (CFS) create a diagnostic dilemma as no definitive tests have established its pathophysiological basis. While progress in defining and measuring the degree of the fatigue are available, biochemical tests have been unhelpful determining their cause. In some patients, the onset of their symptoms may be linked to an earlier inflammatory illness, but supportive biochemical data are unavailable. Activin A and B, TGF β family members, have been identified as proinflammatory cytokines and are regulated by Follistatin (Fst), a high affinity binding protein and all can be measured by specific assays. In mice, serum activin A, B and Fst increase following a lipopolysaccharide injection and are elevated in many patients in intensive care^{1,2,3}. In contrast, in the CFS cohort diagnosed by accepted clinical measures ($n=47$), serum activin A was not increased (97.5 ± 10.1 pg/ml) but serum activin B was increased (117 ± 13.4 pg/ml, $p<0.05$) and lower Fst levels (7.92 ± 0.85 ng/ml $p<0.05$) were found compared to normal subjects (serum activin A 107.9 ± 6.8 pg/ml; activin B 70.4 ± 4.6 pg/ml & FST 10.1 ± 0.5 ng/ml). The higher activin B:Fst and the activin A:Fst ratios indicate an increase in activin bioactivity. While the actions of activin B require further definition, the increased activin A bioactivity can cause apoptosis of hepatocytes and B lymphocytes as well as cachexia and muscle wasting^{4,5}. Longitudinal studies of CFS patients are required to confirm the pathophysiological consequences of these changes. Elevated Activin B and decreased Fst may be a biological signature for the diagnosis of CFS. Further studies are required to define the actions of the elevated serum activin B levels. (95%CI=mean \pm 2SE)

202

Ipilimumab-induced hypophysitis in patients with metastatic melanoma: A novel form of autoimmune pituitary disease

Arianne Sweeting¹, Teresa Lam², Richard Klifford³, Catriona O'Neil^{4,5}, David Chipps^{2,5}, Elizabeth Chua^{1,5}

1. Department of Endocrinology, Royal Prince Alfred Hospital, Sydney, Australia

2. Department of Endocrinology, Westmead Hospital, Sydney, Australia

3. Crown Princess Mary Cancer Centre, Westmead Hospital, Sydney, Australia

4. Chris O'Brien Lifehouse Cancer Centre, Sydney, Australia

5. Sydney Medical School, University of Sydney, Sydney, Australia

Introduction: The novel fully human monoclonal antibody Ipilimumab (Yervoy; Bristol-Myers Squibb) is an anti-cytotoxic T-lymphocyte antigen-4 (CTLA-4) therapy which disrupts immune tolerance to antigens located on tumour cells. Ipilimumab confers significant survival benefit & prolonged stable disease in metastatic melanoma however is associated with several endocrinopathies, presumed autoimmune, including thyroid dysfunction & adrenal insufficiency (primary & secondary). Hypophysitis, a previously rare disease, appears to be the most common Ipilimumab associated endocrinopathy, with reported incidence of 0-17%¹.

Methods: All patients were evaluated at the Chris O'Brien Lifehouse Cancer Centre & Department of Endocrinology, Royal Prince Alfred Hospital or Crown Princess Mary Cancer Centre & Department of Endocrinology, Westmead Hospital between 2012-2014. Relevant data was extracted by review of medical records.

Results: Patient characteristics, biochemical & radiological findings & treatment course pertaining to Ipilimumab-induced hypophysitis are summarised in Table 1. Secondary hypoadrenalism was confirmed via baseline early morning ACTH and cortisol levels with dynamic testing if indicated. Our case series of 8 patients demonstrated variable onset of hypophysitis 2-24 weeks post-initiation of Ipilimumab therapy. Clinical presentation was generally non-specific, with only 4 patients presenting with headache. Diagnosis was confounded by concurrent glucocorticoid therapy in 1 patient. Panhypopituitarism occurred in 2

patients. In contrast to previous reports², hypophysitis was not generally associated with disease responsiveness during Ipilimumab therapy.

Conclusion: In our case series of 8 patients with metastatic melanoma, hypophysitis occurred as early as 2 weeks & as late as 6 months post-initiation of Ipilimumab therapy. All continue on maintenance glucocorticoid replacement with no evidence of reversibility. These results highlight the importance of baseline hormonal screening & continued surveillance, as a high index of clinical suspicion is essential to prevent delayed diagnosis & associated morbidity.

Table 1: Patient characteristics, biochemical and radiological findings and disease course of Ipilimumab-induced hypophysitis

Characteristics:	Patient 1	Patient 2	Patient 3	Patient 4	Patient 5	Patient 6	Patient 7	Patient 8
Age (years)	60	53	69	61	50	70	48	53
Sex	Female	Male	Male	Male	Male	Male	Male	Male
Symptoms at presentation	Shortness of breath Lethargy Nausea	Headache Fatigue Anorexia	Lethargy Nausea Dizziness	Lethargy Cold intolerance	Lethargy Fatigue	Headache Fatigue Unsteady gait	Headache Lethargy Nausea Anorexia	Headache Fatigue Shortness of breath
Mass Effect Symptoms*	No	Yes (headache)	No	No	No	Yes (headache)	Yes (headache)	Yes (headache)
Onset of Symptoms post -Ipilimumab (weeks)	11	12	10	6	24	7	2	12
Diagnosis (weeks)	11	12	10	6	24	7	2	12
MRI	Normal	Enlarged pituitary	Normal	Normal	Normal	Enlarged pituitary	CT Normal	Normal
ACTH (pmol/L)			<1.1	2.9	3.5	3.8	<1.1	1.1
Cortisol (nmol/L)	48	53	<28	50	125	<28	50	<28
Other Pituitary Hormonal Dysfunction	No	No	Inappropriately normal TSH, ↓FT4, LH, IGF-1	No	No	↓TSH, ↓LH/FSH/T, ↓GH	No	No

Serum testosterone and dihydrotestosterone concentrations are associated with lung function in men from the Busselton Health Study.

Bu B. Yeap^{1,2}, Mark L. Divitini³, Shalini Mohan², Alan L. James^{1,4}, David Handelsman⁵, Arthur W. Musk^{1,4}, Matthew W. Knuiman³

1. School of Medicine and Pharmacology, University of Western Australia, Perth, WA
2. Department of Endocrinology and Diabetes, Fremantle and Fiona Stanley Hospitals, Perth, WA
3. School of Population Health, University of Western Australia, Perth, WA
4. Department of Pulmonary Physiology and Sleep Medicine, Sir Charles Gairdner Hospital, Perth, WA
5. ANZAC Research Institute, University of Sydney, Sydney, NSW

Context:

Androgens regulate male development, virilisation and body composition, and are biomarkers for metabolic and cardiovascular health-related outcomes. Their influence on lung function is unclear. We tested the hypothesis that circulating testosterone (T) and its metabolites dihydrotestosterone (DHT) and estradiol (E2) are differentially associated with lung function in community-dwelling men.

Design, participants **and** measurements: We conducted a cross-sectional analysis of 1,768 men from the Busselton Health Survey in Western Australia. Early morning serum concentrations of T, DHT and E2 were assayed using liquid chromatography-tandem mass spectrometry. Sex hormone-binding globulin (SHBG) and luteinising hormone (LH) were measured by immunoassay. Forced expiratory volume (1 second) was measured, and expressed as percent predicted value (PPFEV1).

Results:

Men were aged (mean±SD) 50.1±16.8 years. 15.9% were current smokers, 14.1% reported a history of asthma, 2.7% chronic obstructive pulmonary disease (COPD) and 17% cardiovascular disease (CVD). Current smokers had higher T concentrations compared with never smokers (14.5 vs 13.5 nmol/L, p=0.002), comparable DHT (1.84 vs 1.74 nmol/L, p=0.057) and higher E2 (65.3 vs 60.1 pmol/L, p=0.017). Mean PPFEV1 increased across deciles of T and DHT, and decreased across deciles of LH with no trends apparent for E2 or SHBG. In regression analyses adjusted for age, smoking, asthma, bronchitis, recent wheeze, cough, COPD, exercise, BMI and cardiovascular risk factors, T was associated with PPFEV1 (1.4% increase per 1 SD increase in hormone concentration, p<0.001) as was DHT (1.9%, p<0.001). E2 was not associated with PPFEV1 (0.04%, p=0.92).

Conclusions:

Both T and DHT were independently associated with PPFEV1 in predominantly middle-aged community-dwelling men, while E2 was not associated. Androgens may contribute to, or be biomarkers for, better lung function in men distinct from the influences of smoking or COPD. Further research is needed to clarify whether androgens play a role in preserving lung function in ageing men.

204

Metreleptin improves metabolic and hepatic endpoints in the treatment of non-HAART associated lipodystrophy syndromes: a meta-analysis into the effects of leptin replacement therapy.

Alexander J Rodriguez¹, Teresa Neeman², Aaron G Giles¹, Claudio A Mastronardi¹, Gilberto Paz-Filho¹

1. Translational Medicine Group, Australian National University, Canberra, ACT, Australia

2. Statistical Consulting Unit, Australian National University, Canberra, ACT, Australia

Introduction: Lipodystrophy syndromes (LS) are characterized by generalized/partial absence of subcutaneous adipose tissue, in which clinical manifestations consist of hypoleptinemia, hyperglycemia, elevated insulin resistance, dyslipidemia and hepatic steatosis. Leptin replacement therapy (LRT) is effective at improving glycemic control and liver injury, as well as restoring a normal lipid profile. Currently, no data exists that comprehensively and succinctly compiles the evidence from the literature, and demonstrates the effect of LRT on metabolic and hepatic parameters in LS patients.

Methods: A systematic review of the MEDLINE and Cochrane Library databases was conducted to identify studies assessing the effect of LRT on metabolic and hepatic endpoints. Standardized mean differences (SMD) and 95% confidence intervals of pooled results were calculated for overall changes in glucose homeostasis (fasting glycemia, insulin, HbA1c), plasma lipid profile (triglycerides, total cholesterol, HDL-cholesterol, LDL-cholesterol), and hepatic morphology/function (liver volume/fat, albumin, ALT and AST), using an inverse-variance random-effects model.

Results: After screening, 14 studies were included for review, out of 270 studies eligible for inclusion. Meta-analysis of results from clinical studies in 243 patients showed that LRT decreased fasting glucose [0.76 SMD units (range 0.40-1.12), $p < 0.0001$], HbA1c [0.55 (0.23-0.86), $p = 0.0006$], triglycerides [1.12 (0.81-1.43), $p < 0.00001$], total cholesterol [0.62 (0.21-1.02), $p = 0.003$], liver volume [0.98 (0.52-1.43), $p < 0.0001$], liver fat [0.67 (0.44-0.89), $p < 0.0001$], ALT [0.44 (0.07-0.80), $p = 0.02$] and AST [0.45 (0.17-0.73) $p = 0.002$].

Conclusion: In patients with LS, LRT using metreleptin improves the outcome of several metabolic and hepatic parameters. Studies were limited by small populations and therefore large prospective trials are needed to validate these findings.

206

Cord blood microRNAs that regulate TLR pathways are differentially expressed depending on gestational age.

Natalie Aboustate¹, Nicolette Hodyl¹, Michael Stark¹, Vicki Clifton¹

1. University of Adelaide, Adelaide, SA, Australia

Background: Infants born preterm are at increased risk of developing inflammatory conditions in the neonatal period. This may be due to functional differences in innate inflammatory responses between preterm and term neonates. We have previously demonstrated that stimulation of cord blood from preterm neonates with toll-like receptor (TLR) 2, TLR3 and TLR4 agonists produce higher levels of interleukin-6 (IL-6) compared to term neonates. This suggests there are gestational age differences in regulation of the innate immune response, potentially mediated by differential microRNA (miR) expression. The expression of miRs in cord blood from preterm and term neonates has not been characterised.

Methods: Cord blood from preterm and term neonates was collected at delivery and RNA extracted using the TRIzol method. The relative expression of *TLR2*, *TLR3* and *TLR4* mRNA, as well as miRs known to regulate TLR pathways (*let7e*, miR155, miR146a and miR146b) was determined using qPCR. Data were analysed according to gestational age and antenatal betamethasone exposure.

Results: *TLR4* mRNA expression was increased in preterm cord blood compared to term ($p < 0.05$), while no differences in *TLR2* or *TLR3* mRNA were observed. Expression of *let7e* was significantly reduced in preterm cord blood compared to term ($p < 0.05$), while a trend towards increased *miR155* expression was observed. Expression of *miR146a* and *miR146b* was not affected by preterm birth. Betamethasone exposure had no effect on miR expression.

Conclusions: The parallel decrease in the expression of the microRNA *let7e* with increased *TLR4* expression supports previous observations of this miR's regulatory role in the TLR4 pathway. These preliminary findings indicate that inflammatory pathways in preterm neonates may be mediated by differential miR expression compared to terms.

207

Preliminary study on work stress levels using α -Amylase and cortisol compared to subjective perception of stress

Suresh Kumar Athiappan Palanisamy¹, James R McFarlane¹, Jonathon W Clay²

1. Collaborative Network Research, Mental Health and Well-being in Rural and Regional Communities, School of Science and Technology, University of New England, Armidale, NSW, Australia

2. Molecular and Cellular Biology, University of New England, Armidale, NSW, Australia

The working environment can at times be very stressful, and this can affect the quality of life, contributing to overall mental and physical health. The current subjective measures of psychological stress have their limitations and may result in over or under estimation of the levels of stress. There are various biological markers, which could be used to measure the stress levels. If reliable biomarkers can be found in saliva then this is perhaps the least invasive of the biological samples and thus may provide an objective measure of stress. Salivary cortisol and α -amylase are potential stress biomarkers, as they reflect hypothalamic-pituitary-adrenal and sympathoadrenal medullary activity respectively.

In this study we investigated the stress levels of university technical staff on two different days, one on a regular working day and the other during a demanding intensive school period. The aim was to measure the change in salivary cortisol and α -amylase levels from a normal working day to that of a high intensity working day. This was carried out by collecting the saliva sample at three times of the day (9 am, 1 pm and 5 pm) along with a subjective stress assessment questionnaire, to correlate perceived stress and the salivary cortisol and α -amylase data.

Our preliminary results show that there was no significant difference in cortisol concentrations between the two groups at any time point despite the questionnaire showing elevated stress levels on the high intensity work day. Salivary α -amylase was significantly elevated on the morning of the high intensity day but not at the other time points. The consistent variation between individuals at any time point was high suggesting that gene (α -amylase) copy number could be an important factor. In summary it would appear that perceived stress is not reflected by the biological markers and further study is required.

Genetic analysis of Reelin (*RELN*) SNP rs362719 has no association with either depression or resilience in a rural Australian population

Suresh Kumar Athiappan Palanisamy^{1,2}, James McFarlane^{1,2}, Christopher F Sharpley¹

1. Collaborative Network Research, Mental Health and Well-being in Rural and Regional Communities, School of Science and Technology, University of New England, Armidale, NSW, Australia

2. Centre for Bioactive Discovery in Health and Ageing, School of Science and Technology, University of New England, Armidale, NSW, Australia

The Reelin (*RELN*) gene encoding an extracellular matrix glycoprotein is an important protein for brain development and synaptic plasticity. Reelin protein has been found in various tissues and body fluids including brain, blood, spinal cord, and liver. A number of genome wide association studies and SNP analysis have shown a strong association of this SNP with schizophrenia, bipolar disorder, depression, Alzheimer's disease and other mental health issues. Studies carried out on post-mortem samples have shown reduced or lower levels of reelin in brains of bipolar disorder and schizophrenia patients. There are thousands SNPs present on chromosome 7q22 where the *RELN* gene spans 517.7 kb and in an upstream region there is a CpG island which can also be hyper / hypo methylated which could contribute to the lower expression of reelin in brain.

The heterozygous reeler mouse studies have shown reelin's involvement in psychotic disorders. Although there were no physical abnormalities there was behavioural changes such as delayed pre-pulse inhibition, attenuated methamphetamine-induced hyper-locomotion which are some of the signs observed in patients with psychotic disorders. In mice, over expression of reelin acts as an anti-depressant and the over-expressing strain was more resilient to stressful environments compared to wild types. In this study we collected DNA samples and analysed clinical depression and resilience scores from 141 subjects. The DNA samples were analysed for *RELN* SNP rs362719 using the qPCR-HRM method and validated by using restriction digested and sequence confirmed samples as controls (wild type, heterozygous mutant and homozygous mutant). In this preliminary study we were not able to show an association between SNP rs362719 with either depression or resilience, however further analysis on a larger samples size is required to allow a greater number of variables to be included.

Estrogen receptor β as drug target for the treatment of castrate resistant prostate cancer

Preetika Balanathan¹, Shelley L Hedwards¹, Michelle Richards¹, Renea A Taylor¹, David Pook¹, Luc Furic¹, Gail P Risbridger¹

1. Monash University, Clayton, VIC, Australia

Several new therapies have recently become available for the treatment of castration-resistant prostate cancer (CRPC), however the disease remains incurable and demands novel therapeutic approaches. Selective estrogen receptor (ER) modulators are a class of drugs with mixed estrogen agonistic/antagonistic activity that holds promise in fulfilling this need. Although the expression and action of ER β during PC progression has been unclear, we previously reported ER β 1 expression in human PC cell lines as well as in Gleason Grade 7 human specimens (1). Our data also showed the clinical significance of ER β -induced action via specific agonist, 8 β -VE2, by an increase in PC3-DsRed tumour doubling time (~2 fold) following 8 β -VE2 treatment. We therefore hypothesized that ER β agonists have therapeutic potential to prevent PC development and progression to CRPC.

This study initially characterized the expression of ER β 1 in CRPC TURP specimens (n=8). Nuclear ER β staining was detected in 7/8 specimens and there was no difference in the staining in benign and cancer regions within the tissue. We further tested the therapeutic potential of ER β activation by combining *in vitro* assays and *in vivo* imaging approaches; we analyzed the effects of 8 β -VE2 on PC proliferation, apoptosis, and tumour growth using mcherry labelled PC cell lines. *In vitro*, ER β agonists reduced proliferation and increased caspase 3 activity in androgen-dependent LNCaP cell line as well as in CR C4-2B cell line. Preliminary analyses of *in vivo* LNCaP and C4-2B tumour models show the potential of 8 β -VE2 to slow PC development and progression using.

These data provide the evidence of ER β expression in CRPC as well as functional data supporting the rationale for the potential use of ER β agonist as new options for the treatment of CRPC.

1. (1) McPherson et al., PNAS 2010; 107:3123

The role of nuclear factor kappa b on estrogen receptor β -mediated signalling in ovarian granulosa cell tumours

Wenxin Chen^{2,1}, **Ann Drummond**², **Peter Fuller**², **Simon Chu**²

1. Department of Biochemistry and Molecular Biology, Monash University, Clayton, VIC, Australia

2. MIMR-PHI Institute, Clayton, VIC, Australia

Background: Ovarian granulosa cell tumours (GCT) are hormonally-active neoplasms characterised by endocrine manifestation, an indolent course and late relapse. Chemotherapy and hormonal therapy have proved not to be effective. Nuclear receptors (NR) play a central pathogenic role in endocrine malignancy and are potential targets for therapeutic intervention. Estrogen receptor β (ER β) is the predominant ER in GCT. Evidence suggests that ER β is an anti-proliferative and pro-differentiative transcription factor. Our lab has reported that estrogen (E₂)-mediated ER β signalling is transrepressed by constitutive activation of nuclear factor kappa B (NF κ B) signalling in GCT¹. NF κ B constitutive activities often a feature of many tumour types. The mechanisms involved in NF κ B transrepression of ER β are unknown. We hypothesise that constitutive NF κ B signalling in GCT prevents the anti-proliferative effects of ER β activation.

Methods: Two GCT-derived cell lines, COV434 and KGN were used to perform ligand-dependent transactivation assays and proliferation assays. Cells were transfected with an estrogen responsive reporter, and treated with either E₂, or the ER β -selective agonist diarylpropionitrile (DPN), in the absence or presence of an NF κ B inhibitor (BAY11-7082).

Results: NF κ B transrepression of E₂-mediated ER β signalling was confirmed as previously reported¹. Surprisingly, we observed that DPN-mediated ER β transactivation is not transrepressed by NF κ B, as a 2-fold induction of the reporter was observed in the absence of NF κ B inhibition. However, when cells were treated with either E₂ or DPN, no significant change in proliferation for either ligand was observed.

Conclusion: The lack of NF κ B transrepression of DPN-bound ER β suggests that DPN and E₂ induce different conformational changes in ER β upon ligand binding. We are performing co-immunoprecipitation studies to investigate if these different conformational changes are responsible for whether ER β is transrepressed by NF κ B or not. Additionally, given that DPN had no effect on proliferation, targeting ER β is unlikely to be a therapeutic option for GCT treatment.

1. Chu et al. 2004

Influence of maternal stress during pregnancy in female rats born small on second generation male metabolic and pancreatic outcomes.

Jean N Cheong¹, **Andrew J Jefferies**¹, **Kristina Anevska**¹, **Karen M Moritz**², **Mary E Wlodek**¹

1. Department of Physiology, The University of Melbourne, Parkville, Victoria, Australia

2. School of Biomedical Sciences, University of Queensland, St. Lucia, Queensland, Australia

Intrauterine growth restriction increases the risk of adult metabolic diseases, with males exhibiting more severe phenotypes than females. These disease risks are not limited to the first, directly exposed generation (F1) but may be transmitted to the next generation (F2). Stress during pregnancy adversely impacts fetal development, however, its effect on mothers born small is not understood. We characterised the metabolic phenotype of F2 males born to growth restricted F1 mothers and determined if maternal stress during late pregnancy exacerbated the phenotype.

Late gestation uteroplacental insufficiency was induced on E18 by bilateral uterine vessel ligation (Restricted) or sham (Control) surgery in F0 females. F1 females (Control, Restricted) were mated with a male rat and allocated to Unstressed or Stressed groups. Physiological stressors (24h metabolic cage, tail cuff blood pressure, glucose tolerance test) were introduced during late pregnancy in the Stressed group. F2 body weights were measured, metabolic function characterised (fasting glucose tolerance test and insulin challenge) and pancreatic β -cell and islet mass quantified.

F2 males from mothers exposed to maternal stress had reduced birth weight (-4-6%). At 6 months (mo), Control and Restricted F2 males from Stressed mothers developed impaired glucose tolerance compared with offspring from Unstressed mothers which normalised by 12mo. Insulin sensitivity and secretion were not altered at both ages. Compared to Control counterparts, Unstressed Restricted males had decreased β -cell and islet mass (-17-21%) at 6mo with these deficits exacerbated in Stressed Restricted males (-40-42%). Pancreatic deficits restored to normal by 12mo.

Mothers exposed to modest stress during late pregnancy, independent of maternal birth weight, reduced F2 birth weight and programmed metabolic dysfunction. Maternal low birth weight programmed pancreatic deficits in F2 males that were subsequently normalised, demonstrating β -cell plasticity. These offspring may be predisposed to differential responses when challenged with second-hits including unhealthy diets and sedentary lifestyles.

Clonal selection of castrate-tolerant stem cells leads to regeneration of phenotypically similar prostate cancer tumours

Ashlee Clark¹, **Michelle Richards**¹, **Mitchell Lawrence**¹, **Roxanne Toivanen**¹, **Mark Frydenberg**¹, **John Pedersen**², **Renea Taylor**¹, **Gail Risbridger**¹

1. Monash University, Clayton, Vic, Australia

2. TissuPath, Clayton

Prostate cancer is a heterogeneous disease and it is proposed that the sub-population of cancer cells that survive androgen deprivation possess a lethal phenotype. Identifying the unique biological characteristics of these cells is essential to determine their role in tumour progression and susceptibility to novel therapeutic agents. Using patient-derived xenografts (PDX) we can identify a population of castrate-tolerant cancer cells that 'pre-exist' in localised tumours. We hypothesise that the castrate-tolerant cells represent a select clone that evades treatment without the need to evolve under this selective pressure. To test this, we established PDX of human primary specimens from 3 men with localised prostate cancer that underwent castration and testosterone replacement. Our data analysis includes DNA copy number and protein expression to identify biomarker and molecular profiles of castrate-tolerant prostate cancer cells. Using immunohistochemistry, we showed that localisation and expression of PTEN, FoxA1, FGFR1 and p21 were similar in T-restored grafts compared to intact controls. Whole genome copy number analysis revealed genomic amplifications and deletions were similar between intact and T restored PDX tumours, and that these aberrations were consistent with the original specimen. Whilst these data do not preclude the possibility that the castrate-tolerant cells may attain further alterations after prolonged or additional therapies, they do indicate that new targeted therapies that eliminate them earlier in disease progression may prevent or delay the onset of advanced disease.

Induction of cytochrome P450 (CYP) 1A/1B mRNA expression by 7,12-dimethylbenz(a)anthracene (DMBA) is not dependent on AR mediated androgen actions in male or female mice

Francia Garces Suarez¹, Yan Ru Gao¹, David Handelsman¹, Ulla Simanainen¹

¹.Anzac Research Institute, Concord , NSW, Australia

7,12-Dimethylbenz(a)anthracene (DMBA) is a model polycyclic aromatic hydrocarbon (PAH), compounds that are highly toxic, mutagenic and/or carcinogenic in the environment. DMBA is a widely used carcinogen in experimental breast cancer studies with most PAH effects mediated via the aryl hydrocarbon receptor (AHR). Ligand activated AHR induces the transcription of multiple target genes including cytochrome P450 (CYP) 1A/1B required for enzymatic activation of DMBA. Androgen action mediated via the androgen receptor (AR) is suggested to determine the sex dependent xenobiotic-inducible expression of CYP1 enzymes [1]. As we demonstrated AR dependent induction of DMBA-induced experimental mammary tumors in mice [2], we examined the AR-dependent regulation of *Ahr* and AHR nuclear translocator (*Arnt*) as well as DMBA-induced expression of *Cyp1A* and *Cyp1B* mRNA in mouse liver and mammary gland by comparing gene expression in androgen insensitive, AR knockout (ARKO) and wild-type (WT) control mice. Mature (8-10 weeks of age) male and female WT and ARKO mice were treated with a single dose of DMBA (1 mg) or sesame oil vehicle (by gastric gavage) and tissues collected either 24 or 72 hours after treatment. In the liver, *Cyp1A1* and *Cyp1A2* mRNA expression was significantly induced by 24h after DMBA treatment in male and female mice independent of the genotype but gene expression returned to baseline by 72 hours after DMBA treatment. By contrast in female mammary tissue, *Cyp1A1*, but not *Cyp1B1*, expression was significantly induced at 72 hr after DMBA exposure. Expression of *Ahr* and *Arnt* genes were not affected by DMBA treatment, genotype or gender. These findings show that AR mediated androgen action does not significantly regulate murine *Ahr* or *Arnt* or PAH induced *Cyp1* enzyme mRNA expression.

1. Kojima M, Sekimoto M, Degawa M: Androgen-mediated down-regulation of CYP1A subfamily genes in the pig liver. *J Endocrinol* 2010, 207(2):203-211.
2. Simanainen U, Gao YR, Walters KA, Watson G, Desai R, Jimenez M, Handelsman DJ: Androgen resistance in female mice increases susceptibility to DMBA-induced mammary tumors. *Hormones & cancer* 2012, 3(3):113-124.

The tumour-promoting receptor tyrosine kinase, EphB4, regulates expression of integrin $\beta 8$ in prostate cancer cells

Adrian Herington¹, Inga Mertens-Walker², Bruno Fernandini³, Anja Rockstroh², Colleen Nelson², Sally Stephenson³

¹.Australian Prostate Cancer Research Centre, Institute of Health and Biomedical Innovation, , Queensland University of Technology, Brisbane, Australia

².Australian Prostate Cancer Research Centre, Institute of Health and Biomedical Innovation, , Queensland University of Technology, Brisbane, Australia

³.Australian Prostate Cancer Research Centre, Institute of Health and Biomedical Innovation, , Queensland University of Technology, Brisbane, Australia

EphB4 is a receptor tyrosine kinase that is over-expressed in 66% of prostate cancers (PCa) and can regulate cell migration and invasion. It is recognized as a potentially important therapeutic target. The pathways by which EphB4 promotes tumour progression are poorly understood. To examine the molecular networks that EphB4 influences in PCa, we transiently knocked down EphB4 or over-expressed EphB4 in LNCaP cells, followed by cDNA microarray/bioinformatic analysis. Quantitative real-time PCR and western immunoblotting of selected target genes/proteins validated their differential, EphB4-mediated expression. Microarray analysis identified 260 up-regulated genes and 300 down-regulated genes when EphB4 was knocked down (by 70 %) in LNCaP PCa cells. Gene ontology analysis showed the process of cell adhesion as being most significantly influenced. Several integrins appeared to be deregulated, but Integrin $\beta 8$ (ITGB8) was the top hit with a 29-fold down-regulation in EphB4 siRNA treated cells, compared to control cells (treated with a scrambled, control siRNA). Over-expression of EphB4 led to a simultaneous increase in ITGB8 expression. Integrins play an essential role in the communication between cells and the extracellular matrix, influencing adhesion, migration and invasion of cancer cells. Whilst several members of the integrin family have been a focus in PCa, nothing is known about the role of ITGB8 in this disease. Analysis using the Oncomine clinical cohort database revealed that ITGB8 and EphB4 are both highly expressed in prostatic intraepithelial neoplasms (PIN) with decreasing expression in prostate carcinomas and basal expression in metastases, suggesting roles in the early stages of PCa

progression. In conclusion, we have discovered that EphB4 regulates ITGB8 expression, that they are concomitantly expressed in PCa and that both are highly expressed in PIN. This suggests that EphB4 and ITGB8 could be involved in the onset of PCa and targeting these two proteins synergistically may impact on PCa progression.

215

The generation of long-acting activin analogues

Katharine E Johnson^{2,1}, Kelly L Walton¹, Sara L Al-Musawi¹, Peter A Barton², Craig A Harrison^{3,1}

1.MIMR-PHI Institute for Medical Research, Clayton, Victoria, Australia

2.Faculty of Science, Engineering and Technology, Swinburne University of Technology, Hawthorn, Victoria, Australia

3.Department of Biochemistry and Molecular Biology, Monash University, Clayton, Victoria, Australia

The therapeutic application of transforming growth factor- β (TGF- β) ligands, despite having potential in numerous human diseases, is currently restricted by their short half-lives. All TGF- β ligands are made as large precursor proteins, with N-terminal prodomains and C-terminal mature domains. During ligand biosynthesis, the prodomains are enzymatically removed but appear to remain non-covalently associated with the mature dimer. The mature ligands mediate receptor contacts, and are solely responsible for activity. Currently, all commercially available forms of TGF- β ligands comprise only mature active dimer. These preparations have half-lives of only minutes and are unsuitable for therapeutic treatment in humans. The pro:mature non-covalent complex, in which the mature active ligand is shielded by its prodomains, is predicted to have greater *in vivo* stability than the mature ligands. To address, we firstly generated the pro:mature activin A complex. To favour the production of pro:mature activin A, we enhanced the native furin cleavage site. This modification increased the processing of the activin A precursor, as evidence by increased levels of mature activin A, and reduction in activin precursor. Pro:mature activin A complexes were successfully isolated from stable HEK-293E cell lines by immunoaffinity using an antibody targeted to the prodomain. Importantly, the purified activin A complex had bioactivity comparable to the commercially available mature preparations, supporting that the presence of the prodomains does not hinder bioactivity. An analysis of the activin-induced SMAD-signalling pathway in LbT2 cells suggested that the activin complex may have an extended signaling capacity *in vitro* relative to the mature form. These studies reveal a new means to generate bioactive TGF- β ligands, with anticipated improved stability *in vitro*.

216

The effects of ethanol on trophoblast cell differentiation in culture

Jacinta I Kalisch-Smith¹, Sarah E Steane¹, Marie Pantaleon¹, Karen M Moritz¹, David G Simmons¹

1.School of Biomedical Science, University of Queensland, Brisbane, QLD, Australia

Alcohol consumption is widespread among pregnant women in Australia, particularly prior to pregnancy recognition. We have recently shown in an *in vivo* rodent model of peri-conceptual ethanol [EtOH] exposure, that early exposure results in sex-specific changes to placental morphology in late gestation. Since the EtOH exposure occurs prior to implantation, we hypothesised that EtOH may directly alter the differentiation of trophoblast stem (TS) cells, derived from the trophectoderm, and the allocation of placental lineages, important for the formation of the definitive placenta.

In the current study, male mouse TS cells (RS26) were differentiated for 6 days in the presence of 0% (control), 0.2%, or 1% EtOH (n=3/treatment), and assayed for the expression of lineage-restricted trophoblast subtype markers. RNA was extracted for q-PCR and the expression of genes specific to the labyrinth (*Ctsq*, *Syna*, *Slc16a1*, *Slc16a3*) and junctional zones (*Tpppa*, *Prl7a2*, *Prl7b1*, *Prl2c1*, *Prl3d1*) were analysed.

EtOH treatment caused reductions in the expression of *Syna* (syncytiotrophoblast layer 1 [SynT-I], $P < 0.05$), *Prl7b1* (spiral-artery associated trophoblast giant cells [SpA-TGCs] and glycogen cells [GlyT], $P < 0.05$), and *Prl7a2* (spongiotrophoblast [SpT] cells, $P < 0.001$). No alterations were found for the remaining markers.

The observed reductions in gene expression suggest EtOH exposure can either delay TS cell differentiation or alter cell allocation to specific lineages. A reduction in the differentiation of labyrinthine cells (SynT-I) *in vivo* would lead to a reduced surface area for nutrient transport, while a reduction in the differentiation of junctional zone-derived subtypes (SpA-TGC, SpT, GlyT) would decrease trophoblast invasion and/or endocrine activity. Perturbations in all of these trophoblast subtypes have previously been implicated in foetal growth restriction.

We have shown that direct EtOH exposure results in alterations to placental cell types present within differentiating male TS cell cultures. Future analysis of female TS cells will determine if these changes are sexually dimorphic.

217

Selenium supplementation increases mitochondrial number in trophoblast cells

Alisha Khera¹, Anthony Perkins²

1.Griffith University, Gold Coast Campus, Southport, Gold Coast, QLD, Australia

2.Griffith University Gold Coast Campus, QLD, Australia, SOUTHPORT, GOLD COAST, QLD, Australia

Introduction:

Mitochondria are the major site of reactive oxygen species (ROS) and excessive ROS causes cellular damage and has been associated with complication of pregnancy such as preeclampsia. In previous studies(1) we have shown Selenium has been shown to protect and scavenge the trophoblast cells through the antioxidant enzymes Gpx and Thx-Red, when they induce free radicals (Khera *et al*; 2013). The present study is conducted to demonstrate how selenium increases mitochondrial function of the trophoblast cells and activates mitochondrial biogenesis through various pathways which further activates transcription factors

such as nuclear respiratory factor-1 (NRF1) and peroxisome proliferator-activated receptor coactivator -1alpha (PGC-1 α) (Mehta *et al*;2012).

Methods:

Trophoblast cells (BeWo, JEG-3 and Swan-71) were treated with Na Selenite (100nM) for 24 hours. Cellular respiration was then measured from an Oxygraph-2k Oroboros high respirometry chamber operated at 37°C. The qPCR experiment and citrate synthase experiment were done to demonstrate that selenium treated cells have higher mitochondrial number.

Results:

The study conducted on trophoblast cells exposed to selenium supplementation revealed that selenium treatment (100 nM) for 24 hours effectively increases the mitochondrial number and biogenesis. The oxygen consumption was higher in the cells treated with NaSe as compared to the non-treated cells. The mitochondrial respiration indicated that oxygen flow was significantly increased in selenium supplemented cells. qPCR data revealed that mitochondrial ratio was also higher in the cells treated with selenium.

Discussion:

These data suggest that selenium increases mitochondrial biogenesis. The benefit side of selenium is mediated through lowering ROS production and thus protecting mitochondrial function. This gives the special importance of maintaining adequate selenium during pregnancy and especially in pregnancies complicated by conditions such as preeclampsia.

218

Protective role of glycodelin-A on sperm motility during co-culture with macrophage

Cheuk-Lun Lee¹, William S.B. Yeung¹, Philip C.N. Chiu¹

1.Department of Obstetrics and Gynaecology, The University of Hong Kong, Hong Kong

Spermatozoa are regarded as immunologically foreign cells in the female body. Macrophages are one of the predominant leukocytes that involve in the immunoprotection of the female reproductive tract wherein the spermatozoa have to go across for fertilization. The mechanism of the immunoprotection of sperm is not well known. Glycodelin-A and glycodelin-S are uterus- and seminal plasma-derived immunomodulatory glycoproteins, respectively. The two isoforms of glycodelin share the same protein core but differ in N-glycosylation. The aim of this study is to determine the biological activity of glycodelin-A and -S on human macrophages and its correlation with sperm fertilizing ability in terms of motility. Co-culture of spermatozoa with macrophages reduced sperm motility, but this effect was not observed when macrophages were pre-treated with glycodelin-A. The latter observation was due to reduction of TNF- α secretion from the macrophages. Removal of sialic acid from glycodelin-A eliminated its protective effect on sperm motility, indicating that the protective action of glycodelin-A depends on the present of sialic acid. Consistently, no protective activity was observed with glycodelin-S that lacks terminal sialic acid residues. To conclude, the results from this study provide the first evidence that glycodelin-A diminished the adverse effect of macrophage co-culture on sperm motility. The described action of glycodelin-A may play a role in the mechanisms by which maternal immune attack on spermatozoa is suppressed in the female reproductive tract.

219

Targeting DOHH and eIF5A to inhibit prostate cancer cell growth

Michael R Epis¹, Keith M Giles¹, Michael B Mathews², Hartmut M Hanauske-Abel², Peter J Leedman^{3,1,4}

1.Laboratory for Cancer Medicine, Harry Perkins Institute of Medical Research, Nedlands, Western Australia, Australia

2.Department of Biochemistry and Molecular Biology, New Jersey Medical School, Rutgers University, Newark, New Jersey, USA

3.School of Medicine and Pharmacology, University of Western Australia, Perth, WA, Australia

4.Centre for Medical Research, University of Western Australia, Nedlands, Western Australia, Australia

Understanding the molecular mechanisms producing androgen-independent castrate-resistant prostate cancer (CRPC) is an important objective in prostate cancer (PCa). We have substantial evidence for specific tumor suppressor miRNAs (miR-331-3p and miRNA-642-5p, hereafter referred to as miR-331 and miR-642, respectively) in PCa. Both miR-331 and miR-642 function, in part, in PCa via inhibition of expression of Deoxyhypusine Hydroxylase (DOHH), the enzyme that catalyzes the activation of eukaryotic translation initiation factor 5A (eIF5A), a protein essential for cell growth¹. An inverse relationship exists between expression of miR-331/miR-642 and DOHH in PCa tissues¹. There is increasing interest in identifying eIF5A inhibitors for cancer. Ciclopirox olamine (CPX) is an established topical antifungal drug that is being evaluated in clinical trials as a repositioned anti-cancer agent. Interestingly, CPX inhibits DOHH, and as a consequence hypusination of eIF5A. CPX has significant anti-tumor activity in breast cancer (MDA-231) and in a Phase I trial in AML patients, CPX was well tolerated. We aimed to investigate CPX on DOHH and eIF5A in PCa cells and its on PCa cell growth. We found that siRNA to DOHH mimicked the effects of each of miR-331/642 on DU-145 PCa cell growth, and inhibited production of hypusinated eIF5A. CPX effectively abrogated DOHH expression and eIF5A activation in DU-145 PCa cells. Further, CPX inhibited DU-145 and PC3 cell proliferation with an IC₅₀ ~20 fold lower than for "normal" RWPE-1 prostate cells. Taken together these data suggest that CPX has significant activity to inhibit DOHH, and as a consequence activated eIF5A in PCa, which results in growth inhibition. Further, as the effects of CPX appear greater in cancer versus normal cells, this agent may have therapeutic potential in PCa treatment.

1. Epis MR, et al. J Biol Chem, 2012: 287, 35251-35259.

Estrogen mediates the expression of δ FOSB and cart in hypothalamic kiss1 neurons induced by hypertonic salt load in transgenic mice.

Lisandra Margatho¹, José Antunes-Rodrigues¹, Carol Elias²

1.School of Medicine of Ribeirao Preto, Ribeirao Preto, SP, Brazil

2. *Molecular & Integrative Physiology, University of Michigan, Ann Arbor, Michigan, USA*

In this work we used Kiss1-GFP transgenic mice containing the regulatory sequence of the Kiss1 gene linked to a reporter gene (green fluorescent protein, GFP) in the anteroventral periventricular nucleus (AVPV), anterodorsal preoptic nucleus (ADP) and arcuate nucleus (Arc). The objective of this study was to analyze the neuronal Δ FosB activation and cocaine- and the amphetamine-regulated transcript (CART) expression in the AVPV, ADP and in two rostro-to-caudal levels of the Arc in ovariectomized estrogen-primed (OVX+E) Kiss1-GFP mice and control (OVX+OIL) induced by hypertonic salt loading (SL). During 4 days, these groups (n=6, 25 g) had access to burettes containing 0.3M NaCl solution or water. Completed this period, the mice were anesthetized and perfused transcardially. Dual label immunohistochemistry was performed to determine co-expression of GFP immunoreactivity with Δ FosB or CART in the brain structures. Sections were incubated primary antisera against Δ FosB or CART, overnight at room temperature, followed by incubation with secondary antibodies anti-rabbit IgG biotin conjugated (immunoperoxidase) or AlexaFluor-594 (immunofluorescence). The results were expressed as the percentage of neurons with co-localization of Δ FosB-GFP or CART-GFP in relation to the number of Kiss1-GFP neurons. Significance levels were considered at $p < 0.05$. The OVX+OIL group showed an increase in dual label Δ FosB-GFP in the ADP (20%); AVPV (15%); rostral ARC (46%) and caudal Arc (58%) compared to OVX+E group (13%; 6.5%; 32% and 28%, respectively) in response to salt loading. In addition, SL induced an increase in CART-GFP neurons of the rostral ARC (18%) and caudal Arc (27%) in comparison to OVX+E group (6.3%; 12.4%, respectively). Our findings reveal that Kiss1 neurons and CART expression may be involved in a neural network subserving the regulatory response to changes in plasma osmolality. The results also provide strong evidence that estradiol should be the primary modulator of this response to achieve body fluid homeostasis.

FOXP1 in triple negative breast cancers and its association with androgen metabolism.

Keely McNamara¹, Shota Nakamura², Tomomi Yoda², Niramol Chanplakorn², Hironobu Sasano

1.Tohoku University, Sendai-Shi, Miyagi-Ken, Japan

2. *Tohoku University School of Graduate Medicine, Sendai-Shi, Miyagi-Ken, Japan*

FOXP1 is a member of the FOX family of transcription factors whose gene is located in a region harbouring frequent mutations in breast carcinoma cells. Therefore, FOXP1 has been postulated as a potential tumour suppressor. Its expression has been considered to be regulated by sex steroids and the status of FOXP1 has been reported to be associated with better clinical outcome of ER positive patients. However, its status in ER negative patients has not been explored. In addition, to this FOXA1, an established marker of molecular apocrine breast cancer in tandem with FOXP1 were suggested to form a regulatory loop with androgens in prostate carcinoma hence it has become important to evaluate the potential correlation of FOXP1 expression with FOXA1, AR and androgen synthesising enzymes in triple negative breast cancer patients considering the importance of androgen actions in these tumours. We first immunolocalized FOXP1 in a series of 105 triple negative breast cancers from Ramathibodi Hospital Thailand. The status of FOXA1, AR and the androgen metabolizing enzymes, 5 α R1 and 17 β HSD5 has already been reported in this cohort. In this cohort nuclear FOXP1 expression was present in 44% (47/58) samples. In this analysis FOXP1 status was not associated with FOXA1, AR or 17 β HSD expression but significantly with 5 α R1 positivity ($p=0.03$) and tended to be associated with AR/5 α R1/17 β HSD triple positive cases ($p=0.06$). Further analysis of publically available microarray series of triple negative breast cancers revealed that FOXA1 expression was specific to the LAR subtype but FOXP1 was elevated in all AR expressing samples. These findings all suggest a potential role of FOXP1 in the coordination of androgen intracrinology with androgen action in triple negative breast cancer patients.

Modelling the prostate cancer microenvironment *in vitro* using melt-electrospun scaffolds

Brooke A Pereira¹, Natalie L Lister¹, Elena M De-Juan-Pardo², Stuart J Ellem¹, Dietmar W Hutmacher², Gail P Risbridger¹

1.Prostate Cancer Research Group, Monash University, Clayton, VIC, Australia

2. *Institute of Health & Biomedical Innovation, Queensland University of Technology, Kelvin Grove, QLD, Australia*

The prostate is highly prone to malignant disease. In Australia, approximately 20,000 men are diagnosed and over 3,000 die from prostate cancer (PCa) each year [1]. For decades, human PCa cell lines such as LNCaP and PC3 have been used for the pre-clinical evaluation of new cancer therapies. Mostly, these simple two-dimensional (2D) models have been unsuccessful.

Our fundamental hypothesis is that 2D models do not reflect the complexity of PCa or take into account patient variability. Although prostatic tumours are epithelial in origin, it is well established that the prostate microenvironment (stroma, extracellular matrix, vasculature, immune cells and hormones) plays an integral role in tumourigenicity. However, currently most therapies are targeted towards the malignant epithelium, with the stroma and other components often overlooked.

There is an immediate need to develop multicellular 3D *in vitro* models of PCa to accurately mimic the *in vivo* architecture of the prostate. Whilst xenograft models provide a valuable platform, these are complex, costly and technically challenging. To this end, we aim to develop a novel 3D bioengineered *in vitro* model that can incorporate multiple cell types for the study of PCa.

Poly (ϵ -caprolactone) (PCL) scaffolds were fabricated using direct writing by way of melt electrospinning. PCL filaments were spun in a $0/90^\circ$ pattern at a distance of $\sim 100\mu\text{m}$ to allow for cellular infiltration. Primary prostate fibroblasts were successfully incorporated onto the scaffold and were shown to proliferate and deposit extracellular matrix to form a stromal network. Importantly, this stromal network could instruct the morphology of a prostate epithelial cell line when incorporated into the 3D microenvironment.

In summary, the development of accurate and reproducible 3D bioengineered PCa constructs, which support relevant primary human cells with a 3D arrangement, will provide the field with more realistic alternatives to both *in vitro* and animal models being used today.

1. Australian Institute of Health and Welfare: Australian Cancer Incidence and Mortality (ACIM) books - Prostate Cancer. (2012). Retrieved 03/04/2014, from <http://www.aihw.gov.au/acim-books/>

224

Regulation of activin A production and fibrotic transformation by cultured human lung fibroblasts and the effects of blocking activin action by follistatin

Annan Sali¹, David M de Kretser¹, Mark P Hedger¹

1. MIMR-PHI Institute of Medical Research, Clayton, VIC, Australia

Transforming growth factor- β (TGF β) and activin A increase in lung inflammation. Follistatin, which binds activin A, but not TGF β , modulates post-inflammation fibrosis in the lung *in vivo*. This implies a crucial role for activin A in lung fibrosis, which was investigated at the cellular level in adult human lung fibroblasts (Lonza). When maintained in fibroblast growth medium (FGTM) containing basic fibroblast growth factor (bFGF) and 2% FCS, these cells express low levels of the fibrosis genes, collagen 1A1 (Col1A1) and α -smooth muscle (α SMA), measured by qRT-PCR. For experiment, cells were first expanded in 10% FCS, without bFGF, then seeded into 6 well plates at low density and incubated for 4h. After attachment, the cells were washed with PBS and transferred to serum-free medium. Under these conditions, the cells produced both activin A, measured by ELISA, and follistatin, measured by RIA. Production of activin A was stimulated by TGF β 1 and by rh-thrombin, known inducers of fibrosis, although not by angiotensin II or endothelin-1. Significantly, bFGF had no effect on activin A production, but the effects of TGF β 1 were potentiated by bFGF. Transfer to low cell density under serum-free conditions led to increased expression of Col1A1 and α sm-actin, and this transition was accelerated by TGF β 1. Addition of 300 ng/ml rh-follistatin 288 reduced activin A levels in culture and reduced expression of Col1A1 and α SMA in the presence of TGF β 1. These data confirm that cultured adult lung fibroblasts produce activin A and undergo fibrotic differentiation in the absence of bFGF, a process that is stimulated by TGF β 1. Blocking activin A action inhibits this process, highlighting a facilitative role for activin A in both spontaneous fibrotic differentiation and in mediating the pro-fibrotic effects of TGF β 1. The data also suggest that bFGF reduces the transition to fibrosis by blocking pro-fibrotic actions downstream of TGF β 1/activin A.

225

Endogenous and Synthetic Glucocorticoid Steroids activate different but overlapping sets of target genes during mammalian lung development

Bennet Seow¹, Annie McDougall², Megan Wallace², Timothy Cole³

1. Monash University Biochem, Clayton, VIC, Australia

2. The Ritchie Center, MIMR-PHI Institute of Medical Research, Melbourne, VIC, Australia

3. Biochemistry and Molecular Biology, Monash University, Melbourne, VIC, Australia

Lung immaturity is a common feature in preterm babies, which can lead to a serious condition known as respiratory distress syndrome (RDS), where the lungs of preterm infants are too immature to respire without the assistance of a mechanical ventilator. Current treatment includes antenatal injections of synthetic glucocorticoids to mothers at risk of preterm birth in an attempt to rapidly mature the fetal lung and reduce the risk of RDS. However there are some adverse side effects associated with glucocorticoid use, such as a decrease in overall fetal and brain growth and altered alveoli development. We propose that synthetic and endogenous glucocorticoids differentially regulate a specific, but different, subsets of genes in the lung which contributes to lung maturation and other adverse side effects. RNA was isolated from primary fetal rat lung fibroblast cells (at E20, term \sim E22) treated for 6h with synthetic (betamethasone 10^{-6}M) or endogenous (corticosterone 10^{-6}M) glucocorticoids or vehicle control. Using Next Generation Sequencing (RNA-seq) we have shown that the gene expression profile is distinct for both endogenous and synthetic glucocorticoids. Synthetic glucocorticoids modulated particular genes to a higher degree compared to endogenous glucocorticoids. RNA-seq results were confirmed using qPCR; gene targets such as Cysteine-rich secretory protein LCCL domain containing 2 (*Crispld2*) and SLIT-ROBO Rho GTPase activating protein 3 (*Srgap3*) showed a significant increase ($p < 0.05$) in mRNA levels between control fibroblast cells and fibroblast cells treated with the corticosterone and the betamethasone. These genes, respectively, play a role in alveolarization and extracellular matrix remodeling, which are important events during lung development. By gaining a better understanding of the mechanisms driving glucocorticoid mediated lung development it may be possible to develop better lung-specific treatments for preterm babies that result in reducing adverse side effects, but retaining its effectiveness in inducing rapid lung maturation.

Recurrent pituitary apoplexy due to two successive tumours presenting with ophthalmoplegia and epistaxis

Stephanie L Teasdale¹, Fahid Hashem¹, Warrick Inder²

1. Department of Endocrinology, Gold Coast University Hospital, Southport, QLD, Australia

2. Department of Diabetes and Endocrinology, Princess Alexandra Hospital, Brisbane, QLD, Australia

We describe a case of recurrent pituitary apoplexy, initially with haemorrhage into a non-functioning pituitary adenoma, and then five years later re-presented with what was found histologically to be a sellar malignant spindle and round cell neoplasm. Multiple pituitary tumours have previously been reported to coexist in the same individual, but to our knowledge this is the only case where the occurrence of two distinct *de novo* pituitary tumours have successively arisen in a single patient. This case is also unusual in its progressive ophthalmoplegia, including at one point a bilateral sixth nerve palsy, and in its presentation with epistaxis.

1. Koutourousiou, M. et al. "Collision sellar lesions: experience with eight cases and review of the literature" *Pituitary* 2010, 13:8-17
2. Lau et al. "Isolated bilateral oculomotor nerve palsy in pituitary apoplexy: case report and review", *British journal of neurosurgery*, 2007, 21(4), 399-402
3. Noh SJ "Pituitary adenoma and concomitant Rathke's cleft cyst" *Acta Neurochir (Wien)* 2007 Dec; 149(12): 1223-8. Epub 2007 Oct 3.
4. Kontogeorgos, G. et al. "Multiple adenomas of the human pituitary" *J Neurosurg* 74:243-247, 1991
5. Kontogeorgos, G. et al. "Multiple adenomas of the human pituitary" *J Neurosurg* 74:243-247, 1991
6. Kim et al. "Cranial nerve palsies accompanying pituitary tumour, *J Clin Neuroscience* 14,2007,1158-1162
7. Grover et al "Rathke's cleft cyst presenting as bilateral abducens nerve palsy" *Pituitary*, 14, 2011, 395-399
8. Chentli, F. "Nasal bleeding due to huge prolactinomas", *Acta Endocrinologica (Buc)* vol IX, no 3, 473-478, 2013
9. Ghannam, N.N. Et al. "Primary hypothyroidism-associated TSH-secreting pituitary adenoma/hyperplasia presenting as a bleeding nasal mass and extremely elevated TSH level" *J. Endocrinol. Invest.* 22: 419-423, 1999
10. Keane, J.R. "Pituitary apoplexy presenting with epistaxis" *J. Clin. Neuro-ophthalmol.* 4: 7-8, 1984
11. Komurcu, H.F et al. "Pituitary adenoma apoplexy presenting with bilateral third nerve palsy and bilateral proptosis: A case report" *Med Princ Pract* 2012; 21:285-287
12. Liniker et al. "Temporary bilateral oculomotor nerve palsy as the sole presenting sign of a pituitary mass" *BMJ case report* 2009, 2193-

MIC-1/GDF15, role in physiological and pathological regulation of appetite and body weight

Vicky Wang-Wei Tsai¹, Rakesh Manadhar¹, Ka Ki Michelle Lee-Ng¹, Hong Ping Zhang¹, Yasmin Husaini¹, Shu Lin², Amanda Sainsbury³, David A Brown¹, Samuel N Breit¹

1. St Vincent's Centre for Applied Medical Research, Darlinghurst, NSW, Australia

2. The Garvan Institute of Medical Research Australia, Sydney, NSW, Australia

3. The Boden Institute of Obesity, Nutrition, Exercise & Eating Disorders, The University of Sydney, Sydney, NSW, Australia

Macrophage inhibitory cytokine-1 (MIC-1/GDF15) is a divergent member of TGF- β superfamily cytokine that circulates in humans at levels between 150 – 1150 pg/ml. Its increased expression in diseases such as cancer is associated with development of the anorexia/cachexia syndrome. In mice, high serum levels of MIC-1/GDF15 decrease food intake, leading to reduction of both fat and lean mass that is not associated with altered energy expenditure. This anorexic effect is mediated by activation of brainstem nuclei and modified expression of hypothalamic NPY and POMC. Further, viral expression of MIC-1/GDF15 in the hypothalamus, or ICV administration of recombinant MIC-1/GDF15 has the same anorexigenic effects as systemically administration of MIC-1/GDF15.

To further investigate the relative importance of sites of action of MIC-1/GDF15 in the brain, we have selectively lesioned brainstem AP and NTS nuclei activated by systemic administration of MIC-1/GDF15. Lesioned mice became completely resistant to the anorexigenic actions of MIC-1/GDF15, suggesting that these brainstem regions are critical for its anorexic actions.

To determine whether MIC-1/GDF15 might also participate in physiological regulation of appetite, we studied germline MIC-1/GDF15 gene deleted (MIC-1^{-/-}) mice and found that they exhibited increased food intake, body weight and adiposity, an effect that is more marked in female than male mice. Further, this phenotype could be corrected by infusing MIC-1/GDF15 by osmotic minipump, in amounts sufficient to raise their serum levels into the human normal range.

These studies suggested that MIC-1/GDF15 play a role in regulation of food intake and body weight under both physiological and pathological conditions, and brainstem AP and NTS nuclei are critical in this process.

Increasing muscle mass using novel activin-targeted therapeutics

Kelly L Walton¹, Justin L Chen¹, Sara L Al-Musawi¹, Hongwei Qian², Paul Gregorevic², Craig A Harrison¹

1. MIMR-PHI Institute, Clayton, VIC, Australia

2. Muscle Research & Therapeutics Development, Baker IDI, Melbourne, VIC, Australia

Transforming growth factor- β (TGF- β) superfamily proteins that signal via activin type II receptors (ActRIIA/ActRIIB), including activin A, activin B, myostatin and GDF11, are essential regulators of adult tissue homeostasis. Blocking the activity of these proteins using soluble forms of ActRIIA or ActRIIB has been shown to increase muscle and bone mass, correct anaemia and protect against diet-induced obesity. While exciting, these multiple actions of soluble ActRIIA/IIIB limit their therapeutic potential and new reagents are required that target only one, or a subset, of ActRIIA/IIIB ligands. Here, we modified the activin A and activin B prodomains, regions required for mature growth factor synthesis and activation, to generate specific activin antagonists. Initially, we fused the prodomains to the Fc region of a mouse IgG2A antibody and, subsequently, we incorporated "fastener" residues (Lys⁴⁵, Tyr⁹⁶, His⁹⁷ and Ala⁹⁸, activin A numbering) that help confer latency to pro-myostatin. For the activin A prodomain, these modifications generated a reagent that potently (IC₅₀ 5nM) and specifically inhibited activin A signalling *in vitro* and activin A-induced muscle wasting *in vivo*. Interestingly, the modified activin B prodomain inhibited both activin A and B isoforms *in vitro* (IC₅₀ ~2nM) and *in vivo*, suggesting it could serve as a general activin antagonist. Importantly, unlike soluble ActRIIA/IIIB, the modified prodomains did not inhibit myostatin or GDF11 activity. Finally, to underscore the therapeutic utility of specifically antagonising activin signalling, we demonstrate that the modified activin prodomains can promote significant increases in muscle mass.

The Iron Chelator Deferasirox induces browning and increased energy expenditure of white adipose tissue in mice

Mawson Wang¹, Kuan Minn Cha¹, Michael Swarbrick¹, Jenny E Gunton^{1,2}

1. Diabetes and Transcription Factors Group, Garvan Institute of Medical Research, Darlinghurst, NSW, Australia

2. Westmead Clinical School, University of Sydney, Westmead, NSW, Australia

Background:

The obesity epidemic is a significant global health crisis, and is closely associated with numerous metabolic disease processes such as type 2 diabetes. Hypoxia-inducible factors (HIFs) are transcription factors involved in regulating numerous cellular processes, including lipid and glucose metabolism. Iron regulates HIFs, with iron chelation increasing levels of HIF protein.

Aims and Methods:

C57Bl/6 mice were fed high fat diet (HFD) with or without addition of the iron chelator deferasirox (DFS) for 10 weeks. The effects of HFD \pm DFS on energy expenditure of subcutaneous fat were measured using the Seahorse Bioanalyser. Gene expression was measured in fat of the mice.

Results:

HDS+DFS mice had significantly lower weight gain, lighter subcutaneous and visceral fat depots, and better glucose tolerance compared to HFD mice. Histological examination of subcutaneous fat showed increased UCP-1 positive area in subcutaneous fat of HFD+DFS mice. There were 2-3 fold increases in expression of *Pgc-1a*, *Prdm16* and *Ucp-1* in the subcutaneous fat of the mice.

HFD+DFS mice had markedly higher oxygen consumption, and HFD+DFS subcutaneous fat explants had a 32 % increase in oxygen consumption rate measured by the Seahorse.

Conclusion:

DFS ameliorated the subcutaneous and visceral fat gain and glucose intolerance caused by HFD. The beneficial metabolic outcome of DFS related to the upregulation of brown/ beige genes within subcutaneous white fat, inducing a 'browning' effect with resultant increased mitochondrial oxygen consumption and overall body energy expenditure. Thus, if well-tolerated in human subjects, iron chelators may be a novel therapy for the treatment of diet-induced obesity.

Do sheep have pelvic organ prolapse and differences in vaginal pressure?

Natharnia Young^{1,2}, Caroline Gargett¹, Jerome Werkmeister³, John Arkwright⁴, Joseph Lee², Anna Rosamilia²

1. The Ritchie Centre, MIMR-PHI, Clayton, VIC, Australia

2. Monash Health, East Bentleigh, VIC, Australia

3. CSIRO, Clayton, VIC, Australia

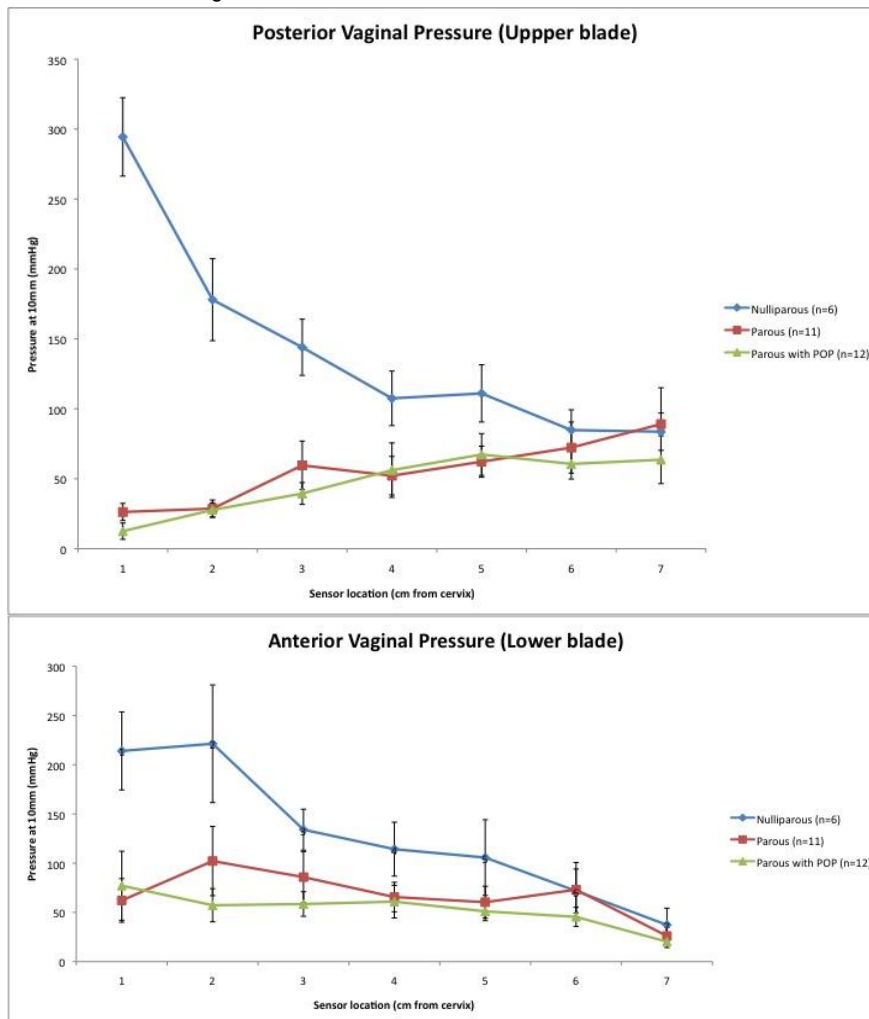
4. Biomedical Engineering, Flinders University, Adelaide, SA, Australia

Sheep develop spontaneous POP at a similar frequency as women and maybe a suitable model for preclinical studies evaluating cell-based therapies for POP. The aim was to establish a clinical score of POP in ewes and correlate this with vaginal tone measured with a fibre-optic pressure sensor device.

Vaginal examinations were conducted on 29 conscious ewes (6 nulliparous, 23 parous) without sedation standing in a V drive, by adapting the human POP-Q (1). Maximum displacement of vaginal tissue at POP-Q points; Aa, 3cm above the introitus on the anterior vaginal wall (range -3above to +3 below the introitus); Ap, 3cm above the introitus (posterior wall); Ba above the urethra (anterior wall) (-3 to total vaginal length); GH (genital hiatus); PB (perineal body). Ovine POP was defined as descent to the introitus, or increased Ba (0) relative to the urethra. The pressure sensor device has 7 pressure sensors on each blade of a speculum, which electronically recorded vaginal pressures at 10mm dilation.

There was no evidence of tissue mobility at Aa, Ap, Ba in nulliparous ewes, which also had smaller GH and PB compared to parous ewes (Table 1). Twelve parous sheep showed significant POP at Ba, with greater tissue mobility at Aa and Ap compared to the other parous ewes (P < 0.0001, 0.003, and 0.019 respectively). Nulliparous ewes showed significantly greater

pressures in the upper vagina (Ba, sensors 1,2,3) ($P < 0.0001$) compared to parous sheep with/without POP. Parous ewes with POP had lower pressures at point 3 compared to those without (Figure 1&2). Our data suggests correlation between increased vaginal tissue mobility and lower vaginal tone in the upper anterior vagina of parous ewes that is not evident in nulliparous animals. These methods may predict subclinical POP in sheep enabling their selection for assessing new treatments for POP



POP-Q point	Nulliparous (n=6)	Parous (n=12)	Parous with "POP" (n=11)	P value
Aa	-3 ± 0	-1.75 ± 1.06	-0.36 ± 0.92	<0.0001
Ap	-3 ± 0	-1 ± 1.13	0.18 ± 1.1	<0.0001
Ba	-3 ± 0	-2.71 ± 0.49	1.15 ± 1.89	<0.0001
GH	1.67 ± 0.26	1.98 ± 0.31	2.31 ± 0.41	0.003
PB	2.92 ± 0.49	2.21 ± 0.45	2.77 ± 0.51	0.008

1. Bump RC, Mattiasson A, Kari B, Brubaker LP, Delancey JOL, Klarskov P, et al. The standardization of terminology of female pelvic organ prolapse and pelvic floor dysfunction. 1996;10-7.

Protective effects of *in vivo* hexarelin treatment on pancreatic β -cell function in streptozotocin-induced diabetic rats

Xinli Zhang¹, Yan Zhao¹, Walter G Thomas¹, Chen Chen¹

¹.University of Queensland, St.Lucia, QLD, Australia

Pancreatic β -cell dysfunction is major characteristic of diabetes and destructive β -cell morphology has been found in different diabetic animal models. Growth hormone secretagogue, ghrelin, was reported has protective effect on pancreatic β -cell function and able to normalize blood glucose level in diabetes. Thus, we aim to use synthetic growth hormone secretagogue, hexarelin, to investigate pancreatic β -cell function in streptozotocin (STZ)-induced diabetic animal model.

STZ-induced diabetic rat was employed as animal model in comparison with control vehicle. Male Wistar rats at age of 6-week old were injected intra-peritoneally with a single dosage of 65mg/kg STZ to induce diabetes for 6 weeks. After 4 weeks of disease development, a group of control and diabetic animals were receiving daily hexarelin (100mg/kg) treatment for 2 weeks. During 6 weeks disease development, blood glucose level (once a week), water consumption (daily) and body weight gain (twice a week) were monitored. By the end of treatment, GTT, ITT, blood plasma insulin level and pancreatic islets immunostaining were assessed.

We observed a significant increase of blood glucose level and slow body weight gain through 6 weeks disease development in STZ-induced diabetic animals. After hexarelin treatment, body weight gain increased and blood glucose level decreased. Islets of control animals were round, with a clear boundary, normal structure and cell numbers. But in diabetes group, numbers of insulin-positive cells were sharply declined and structure of islets was disrupted. In the group co-treated with STZ and hexarelin, the numbers of insulin-positive cells increased significantly and showed close-to-normal structure of islets. Further measurement on insulin level under fasting and feeding condition showed that insulin level was significantly declined in diabetic animals but increased in both treated control and diabetic animals. There was not much difference in GTT study but hexarelin treated diabetic animals exhibited good insulin sensitivity in ITT study.

Hypertensive crisis in a patient with malignant paraganglioma: a therapeutic challenge

Azni Abdul-Wahab¹, Nirupa Sachithanandan², David Pattison², Michael Hofman², Michael Michael², Cherie Chiang^{1,2}

1. Royal Melbourne Hospital, Melbourne, VIC, Australia

2. Peter MacCallum Cancer Centre, Melbourne

A 46 year old man presented with a painful left mandibular mass. Subsequent investigations confirmed an organ of Zuckerkandl primary paraganglioma with metastases to left mandible, inferior ramus and T6 vertebral body on a background of SDHB mutation. Catecholamines were elevated and hypertension controlled on phenoxybenzamine 20mg b.d and perindopril/amlodipine. 14 months after disease stabilisation with ¹⁷⁷Lu-DOTA-Octreotate (LuTate) peptide receptor radionuclide therapy and radiotherapy, the primary Organ of Zuckerkandl was resected. Post-operative nadir of normetadrenaline level was 3,555 pmol/L (<900 pmol/L) with improvement in abdominal symptoms (Fig. 1).

Re-staging scans 3 months later revealed new osseous metastases and exponential rise of plasma normetadrenaline. Sunitinib was commenced. Two weeks later, he developed abdominal pain, constipation and nausea. Admission blood pressure was 230/125 mmHg, he was febrile with a sinus tachycardia of 120 bpm. Hypertension was resistant to intravenous phentolamine, sodium nitroprusside, glyceryl trinitrate and labetalol. CT revealed pseudo-obstruction with dilated bowel loops up to 12.5 cm and faecal loading. Plasma normetadrenaline level was 135,136 pmol/L.

The pseudo-bowel obstruction was initially managed conservatively without success. Neostigmine infusion achieved a temporary response in bowel action. Hypertension and constipation persisted, and on day 7 of admission, an urgent low dose of LuTate therapy was administered. Subsequently, hypertension was stabilised on oral agents (phenoxybenzamine 40mg t.d.s, metoprolol, amlodipine and perindopril). His bowels opened weekly post discharge on oral pyridostigmine and laxatives. He remains stable clinically and restaging scan confirms scintigraphic stabilisation of the disease.

The exponential rise of catecholamines resulted in pseudo-bowel obstruction (Ogilvie syndrome) and hypertensive crisis. Although alpha-blockade is associated with survival of a paraganglioma crisis, the acute management remains challenging (1). Our case highlights the importance of recognising Ogilvie syndrome, a rare feature of paraganglioma/pheochromocytoma crisis whereby bowel perforation is associated with a high mortality rate (2).

Discussion points:

1. Management of pheochromocytoma/paraganglioma crisis.
2. The use of neostigmine in Ogilvie syndrome, a complication of catecholamine excess.
3. The role of PRR.T and tyrosine kinase inhibitors in metastatic paraganglioma.

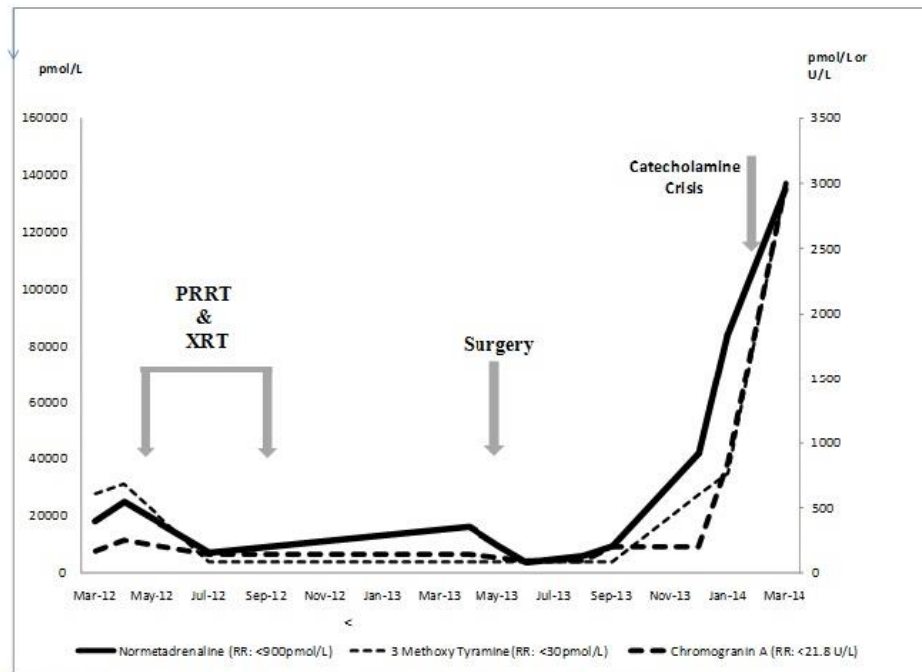


Figure 1. Plasma normetadrenaline and neuroendocrine tumour markers level in relation to treatment intervention, and on presentation of catecholamine crisis. RR=Reference Range; XRT= External Beam Radiotherapy; PRRT= Peptide Receptor Radionuclide Therapy

1. Whitelaw BC, Prague JK, Mustafa OG, Schulte KM et al. Pheochromocytoma crisis. Clin Endocrinol (Oxf). 2014;80(1):13-22
2. Osinga TE, Kerstens MN et al. Intestinal pseudo-obstruction as a complication of paragangliomas: case report and literature review. Neth J Med. 2013;71(10):512-7.

Hypothyroidism in pregnancy: audit of the Monash health endocrine pregnancy clinic

Sally Abell¹, Fran Milat¹, Jun Yang¹, Peter Fuller¹, Cameron McLaren¹, Carolyn Allan¹

1. Monash Medical Centre, Clayton, VIC, Australia

Background

The Endocrine Pregnancy Clinic provides dedicated care for women with endocrine disorders during pregnancy and the early post-partum phase. Thyroid dysfunction is important due to the inter-relationships between thyroid and pregnancy, and the potential implications for both mother and child

Aims

1. To assess adequacy of thyroid hormone replacement in pre-existing hypothyroidism.
2. To document range of TSH values and presence of autoantibodies in newly diagnosed hypothyroidism in pregnancy.

Method

An audit of the first two years of women referred to the Endocrine Pregnancy Clinic from March 2012 to March 2014. Data collected included age of pregnant woman, gravidity, parity, gestation, past and family history of thyroid dysfunction, thyroid function tests (TFTs), presence of a goitre and autoantibody status.

Results

210 women were referred for assessment of hypothyroidism, at a mean gestation of 20 weeks. 100 women (47.6%) were treated for hypothyroidism prior to the current pregnancy. At referral, 62 patients (62%) had elevated TSH levels (2.5-5.0 IU/L, n=35; 5.1-10 IU/L, n=14, >10.1 IU/L, n=13). A mean thyroxine dose adjustment of 33% was required throughout the pregnancy. 110 women had newly diagnosed hypothyroidism in pregnancy and 40% had positive thyroid peroxidase (TPO) antibodies. At referral, 101 patients (92%) had elevated TSH (2.5-5.0 IU/L, n=51; 5.1-10 IU/L, n=36, >10.1 IU/L, n=14). They required a mean dose adjustment of 25% during the pregnancy. 19 patients with new hypothyroidism had a normal TSH on repeat and did not require replacement.

Conclusion

Women frequently have TSH levels above the ideal range, despite recommendations for management of pre-existing hypothyroidism in pregnancy. Thyroid hormone replacement should be optimised prior to conception with early measurement of thyroid function upon confirmation of pregnancy. Those with hypothyroidism in pregnancy should be followed closely until TSH reaches target. Both groups should be seen at regular intervals thereafter for dose adjustment.

Cushing's conundrum: A case of Primary Pigmented Nodular Adrenal Disease in a 60 year female

Jasna Aleksova¹, Glenn Ward¹, Kim Taubman¹, Stephen Farrell¹, Jason Tan¹, richard macisaac¹, Nirupa Sachithanandan¹

1. St Vincents Hospital, Fitzroy, VIC, Australia

A 60year old female with difficult to control hypertension and poorly controlled type2 diabetes was referred for investigation of hypercortisolism. She had multiple comorbidities including COPD requiring treatment with inhaled corticosteroids. Clinical examination revealed a BMI of 31, supine hypertension (BP 160/90), truncal obesity, proximal muscle wasting and weakness but no evidence of striae, bruising, skin thinning or buffalo hump. She was not pigmented, had no abdominal masses and had normal visual fields.

Investigations for secondary hypertension showed a normal aldosterone to renin ratio 18.6 (n<20), plasma metadrenaline 139pmol/L (n <500pmol/L) and normetadrenaline 92 pmol/L (n <90 pmol/L). GH, IGF-1, thyroid function and plasma DHEAS was normal. Renal artery doppler did not reveal significant stenosis.

24 hour urine free cortisol measurements were 181nmol/L and 454nmol/L (n<350nmol/L). Her ACTH remained undetectable on numerous occasions (<5pg/ml). Due to difficulty in ceasing inhaled steroids an overnight 1mg Dexamethasone suppression test was performed whilst the patient was taking fluticasone/salmeterol. The following morning cortisol was 278 nmol/L (n<120nmol/L). Persistent hypercortisolism was then confirmed with IV dexamethasone suppression testing¹ performed after withholding inhaled fluticasone for 3 days. An Adrenal CT scan showed a slightly enlarged left adrenal with an 8mm nodule at the inferior pole (Hounsfield unit <5). Given the lack of localisation of cortisol secretion on anatomical imaging functional imaging with iodocholesterol was performed but also non-diagnostic. Adrenal vein sampling was thus performed^{2,3} (Table 1). Results were consistent with bilateral autonomous cortisol secretion. The patient was subsequently referred for bilateral adrenalectomies.

The case discussion evaluates the challenges of diagnosing hypercortisolism when exogenous steroids cannot be ceased, the importance of selecting an assay that would reliably exclude cross reacting steroids and methods in localising the source of cortisol secretion when conventional imaging is unhelpful. Histology results will be available by the conference date.

Table 1

TIME	1415	1415		1415	1415		1422	1422		1425	1425		1430	1430	
	LA1	LP1		LA2	LP2		RA1	RP1		RA2	RP2		RA3	RP3	
Cortisol (units)	2463	408	6.04*	5744	375	15.32*	9108	386	23.60*	11186	112	99.88*	11718	411	28.51*
ACTH (units)	<5	<5		<5	<5		<5	<5		<5	<5		<5	<5	
Aldosterone (units)	618	107	5.78#	1466	121	12.12#	2186	130	16.82#	2783	392	7.1#	12254	126	97.25#
C/A	3.98	3.81		3.92	3.01		4.17	2.97		4.02	0.29		0.96	3.26	
C/A Right: Left							1.05			1.02					
Noradrenaline (units)	3.7	0.9		6.4	1.2		9.1	1.2			1.2		7	1	
Adrenaline (units)	5	0		>6.0	0		>6.0	0			0		>6	0	
Dopamine (units)	0	0		0	0		0	0			0		0	0	

LA1- left adrenal 1; LP1- Left periphery 1; LA2-left adrenal 2; LP2- Left periphery 2; RA1- right adrenal 1; RP1- Right periphery 1; RA2- right adrenal 2; RP2- Right periphery 2; RA3- right adrenal 3; RP3- Right periphery 3
 C/A: cortisol to aldosterone ratio
 *AV: AV cortisol ratios
 # AV: PV aldosterone ratios

1. Jung C, Alford FP, Topliss DJ, Burgess JR, Long F, Gome JJ, Stockigt JR, Inder WJ. The 4-mg intravenous dexamethasone suppression test in the diagnosis of Cushing's syndrome. Clin Endocrinol (Oxf). 2010 Jul;73(1):78-84
2. Doppman JL, Gill JR Jr. Hyperaldosteronism: sampling the adrenal veins. Radiology. 1996; 198:309-312
3. Young WF, du Plessis H, Thompson GB, Grant CS, Farley DR, Richards ML, et al. The clinical conundrum of corticotropin-independent autonomous cortisol secretion in patients with bilateral adrenal masses. World J Surg. 2008;32(5):856-62

Between a rock and a hard place: the management challenges of recurrent Cushing's disease

Dushyanthy Arumugam¹, Sumathy Perampalam¹

1. Endocrinology Department, The Canberra Hospital, Garran, ACT, Australia

Cushing's Disease is associated with 3-5 fold increase in mortality. The primary treatment modality has been trans-sphenoidal surgery as it allows treatment of the underlying cause without the need for long term hormone replacement. Complete remission rates of 60-85% have been documented, however recurrence can occur in up to 25% of patients postoperatively. In repeat pituitary surgery following recurrence, remission rates are lower at 50-60%, and chances of pituitary failure are higher. Other possible treatment modalities include pituitary radiotherapy, bilateral adrenalectomy and medical management. The latest medication to gain recognition for its role in Cushing's Disease is Pasireotide, a somatostatin analogue.

This case is a 48 year old lady who underwent pituitary surgery for a non-functioning pituitary cystic lesion. Years later she developed clinical and biochemical features of Cushing's Disease however imaging studies could not identify an adenoma. Histology from the initial operation was reviewed which showed widespread immunoreactivity for ACTH. She underwent two further pituitary surgeries and achieved remission. Clinically and biochemically she was cured. Unfortunately within a year, the Cushing's Disease recurred. This is her second recurrence of Cushing's disease in the context of three previous pituitary surgeries, with no visible lesion on MRI.

This case illustrates the difficult management decisions that need to be made in a patient with recurrent Cushing's disease. Surgical management has traditionally been considered first line treatment for recurrent Cushing's Disease, however with the recent addition of Pasireotide we need to consider the possibility of a medical alternative which show promise as a viable alternative first line therapy.

1. Atkinson, AB; Kennedy, A (2005) Long term remission rates after pituitary surgery for Cushing's disease: the need for long-term surveillance. *Clinical Endocrinology*, 63, 549-559.
2. Bertagna X, Guignat L (2013) Approach to the Cushing's Disease Patient With Persistent/Recurrent Hypercortisolism After Pituitary Surgery. *Journal of Clinical Endocrinology and Metabolism*. 98(4), 1307-1318.
3. Sheehan MD et al (2013) Results of Gamma Knife Surgery for Cushing's disease. *Journal of Neurosurgery*. 119, 1486-1492
4. Liubinas SV, Del Porto L, Kaye AH (2011) Management of recurrent Cushing's disease. *Journal of Clinical Neuroscience*. 18, 7-12
5. Colao A et al (2012) A 12-Month Phase 3 Study of Pasireotide in Cushing's Disease. *New England Journal of Medicine*. 366, 19-24.
6. Gadelha MR, Neto LV; (2014) Efficacy of medical treatment in Cushing's disease: a systematic review; *Clinical Endocrinology*. 80, 1-12

236

Graves' Disease and multifocal papillary thyroid cancer

Dushyanthy Arumugam¹, Sally Newsome¹, Susan J Wigg¹

1. Endocrinology Department, The Canberra Hospital, Garran, ACT, Australia

The coexistence of Graves' Disease and multifocal papillary thyroid microcarcinoma is a rare phenomenon. A retrospective case-control study (1) found that Papillary thyroid cancer (PTC) was incidentally discovered in 2% of 2356 surgically treated Graves' disease patients. However there are no published series of metastatic multifocal PTC in patients presenting with Graves' Disease. We present 2 cases of metastatic multifocal PTC in young patients presenting with Graves' Disease. Case 1 is a 24 year old woman who presented with thyrotoxicosis and classical clinical and biochemical features of Graves' Disease (TSH Receptor antibody 38, normal <1.5IU/L). A thyroid ultrasound (arranged by GP) showed enlargement and increased vasculature in keeping with Graves' disease. However there were also diffuse microcalcifications suggestive of PTC. Fine needle aspirates (FNA) of the thyroid gland and suspicious lymph nodes showed metastatic PTC. She proceeded to a total thyroidectomy with lymph node dissection. The histopathology confirmed multifocal, bilateral papillary microcarcinoma with lymph node metastases on background Graves' disease. Case 2 is a 31 year old man who presented with typical Graves' thyrotoxicosis (TSH Receptor Antibody >40IU/L) and goiter confirmed on uptake scan. He responded well to Carbimazole (normal TFTs) but after 16 months of treatment he became hypothyroid (TSH 91, normal 0.40-4.00mIU/L) and his neck examination revealed cervical lymphadenopathy. Ultrasound showed extensive microcalcification and FNA confirmed PTC. He underwent total thyroidectomy with right and central compartment neck dissection and histopathology confirmed bilateral multifocal PTC with extensive lymph node metastases.

1>

These cases of multifocal PTC in young patients presenting with typical Graves' Disease raise the question of whether thyroid U/S should be considered in the routine assessment of Graves' thyrotoxicosis.

1. Yano Y et al (2007) Recent outcome of Graves' disease patients with papillary thyroid cancer. *European Journal of endocrinology*, 157, 325-329

237

HAART Break - An Unusual Case of HIV associated bone disease

Kharis Burns¹, Teresa Lam¹, David Chipps¹

1. Department of Diabetes and Endocrinology, Westmead Hospital, Westmead, NSW, Australia

A 63 year old man presented with newly diagnosed HIV/AIDS, and Hepatitis B. Highly Active Anti Retroviral Therapy (HAART) including zidovudine, lamivudine and efavirenz was commenced with adefovir for Hepatitis B. The HAART regimen was later changed to tenofovir, emtricitabine and efavirenz due to evidence of viral resistance, and adefovir ceased. Shortly after, the patient suffered a minimal trauma metatarsal fracture. BMD Lumbar Spine T-Score was -1.1, and total proximal femur T-score -1.7. Total testosterone was 9.6nmol/L (ref 9.5-28), free testosterone 181nmol/L (ref 80-370), LH 15U/L (ref 2-10) FSH 21U/L (ref 1.5-3.0), and SHBG 74nmol/L (ref 10.0-50.0). Bisphosphonate therapy and testosterone replacement were commenced. Three years later the patient developed acute onset of left thigh pain in the absence of trauma. CT imaging confirmed an incomplete subtrochanteric cortical proximal femoral shaft fracture. A nuclear medicine bone scan demonstrated corresponding uptake in the femur and multiple symmetrical focal areas of uptake in ribs and first metatarsals bilaterally. Retrospective review

identified a steady decline in serum phosphate since shortly after initial HIV presentation with rapid decline following the introduction of tenofovir to a nadir of 0.45mmol/L (ref 0.75-1.5). The serum corrected calcium was within the normal range (2.10-2.60) with replete serum 25(OH) Vitamin D 96nmol/L, and 1,25(OH)₂ Vitamin D 157pmol/L (ref 60-158). Alkaline phosphatase had been stable at 75-100U/L apart from a single rise to 220U/L. 24-hour urine investigations found elevated fractional excretion of phosphate 46% (ref range 5-20%), proteinuria 0.83g/L and aminoaciduria. Urinalysis revealed glucose 1+. Investigations were indicative of tenofovir-induced hypophosphataemic osteomalacia secondary to phosphate wasting and Fanconi Syndrome. However, the femoral shaft fracture showed characteristic features of an atypical fracture possibly related to bisphosphonates. The concomitant findings of two varying fracture pathologies questions the contribution of bisphosphonates to reduced bone turnover in the setting of osteomalacia.

Pitfalls with Parathyroid hormone measurement - lessons learnt.

Simon Carrivick^{1,2}, **Narelle Hadlow**², **Rob Wardrop**², **Aaron Simpson**², **Kalani Kahapola Arachchige**², **Melissa Tanner**², **Ee mun Lim**^{1,2}

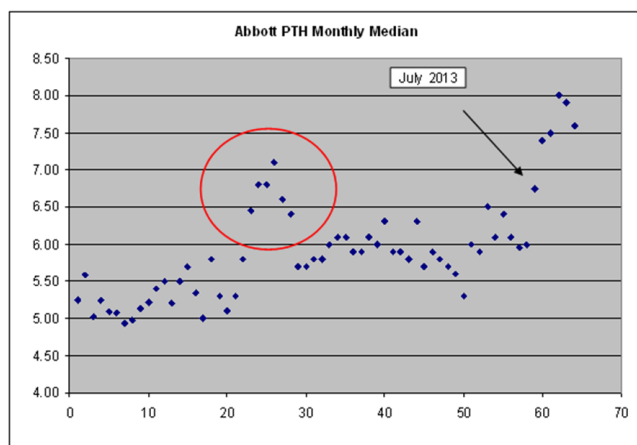
1. Endocrinology, Sir Charles Gairdner Hospital, Perth, Western Australia, Australia

2. Biochemistry, PathWest QEII, Perth, Western Australia, Australia

Introduction: Parathyroid hormone (PTH) is commonly measured in the setting of chronic renal failure, investigation and management of hyperparathyroidism and osteoporosis. It is also routinely requested in 'general health' checks, particularly given the recent interest in calcium and vitamin D.

Background: On the 17th February 2014 Abbott Diagnostic issued an immediate discontinuation of its Architect intact PTH assay (27/148 Australian laboratories used this assay), stating a magnitude shift of 13-45% in patient results when using current reagent and calibrator lots in comparison to an earlier study in August 2012.

Data: In-house retrospective data revealed a transient spike in mean PTH results in early 2010 and a significant rise in monthly median PTH from mid 2013. Mean and median PTH levels for the second half of 2013 were above the upper limit of the reference interval (mean 7.7 pmol/L, median 9.2 pmol/L, reference interval 0.7-7.0 pmol/L). Samples tested on both the Abbott and Roche assays showed a significant positive proportional bias towards the Abbott results, however the reference intervals on these assays are very similar.



Discussion: Subsequent to the discontinuation of the assay, PTH was briefly unavailable for analysis. Every PTH request was then individually reviewed. Samples requiring analysis were sent to a different laboratory. In the ten days following the assay withdrawal, only 68/322 samples (21.1%) were sent for analysis. The remaining samples were not analysed as they were known to have chronic renal failure, had a normal calcium, or normal calcium and vitamin D. Given each PTH request costs \$26 and there are 22,000 samples analysed yearly, reviewing PTH requests could potentially save \$450,000 per year.

Conclusion: These events highlight the relevance of ongoing assay quality control as well as the need for appropriate requesting of tests.

Osteoporosis management at Western Health - a retrospective audit

Daniela WC Chan^{1,2}, **Roslin Botlero**³, **Stephanie Ward**², **Peter Ebeling**^{4,5}

1. Department of Endocrinology & Diabetes, Barwon Health, Geelong, VIC, Australia

2. Department of Geriatric Medicine, Western Health, Melbourne, Victoria, Australia

3. Department of Medicine, Population Health, University of Melbourne, Melbourne, Vic, Australia

4. Department of Medicine, School of Clinical Sciences, Monash University, Monash Medical Centre, Clayton, VIC, Australia

5. Department of Endocrinology, Western Health, Melbourne, Vic, Australia

Objectives:

- To compare osteoporosis management among different units at Western Health with previously published “best-practice” guidelines
- To audit outcomes of patients presenting to Western Health with fragility fractures
- To investigate patient factors influencing length of stay

Background:

Osteoporosis is frequently unrecognised and inadequately managed, despite availability of effective therapies. Anecdotal experience suggests that significant variation in osteoporosis management exists among different units.

Methods:

A retrospective audit of Western health patients ≥60 years of age, presenting with fragility fractures¹ from July to December 2012, was performed. Admission episodes were identified using the keyword “fracture” under the ICD-10 coding system. Electronic Medical Records were reviewed by one investigator to identify fragility fractures. Demographic information, documentation of existing osteoporosis treatment, risk factors, investigations, and interventions on discharge were collected and entered into a standardized database.

Results:

366 fragility fracture admissions were included. 31.1% had documentation regarding the presence of osteoporosis/osteopenia. Only 5.5% had documentation of a prior bone mineral density (BMD) scan. 56.3% had renal function, serum 25(OH)D and calcium tested, with the worst performance by Orthopaedic and Cardiothoracic units. 1.9% of admitted patients had inpatient BMD scans, and 4.6% had a scan organised upon discharge. 40% were not taking osteoporosis therapies prior to admission; only 15.6% of these patients were initiated on ≥1 osteoporosis therapies on discharge. Of patients discharged from acute units, 9.3% were on triple therapy²; 35.8% were discharged on no treatment. At hospital discharge 6.6% were deceased, 10.4% were non-ambulant, and 66.4% required assistance with mobility. The only patient factor influencing length of stay was fracture type (hip>wrist, foot and hand).

Conclusion:

Significant variation in osteoporosis management exists between units at Western Health, with low investigation and treatment rates. A systematic approach, such as a fracture liaison service, is required to improve these outcomes.

¹occurring from a standing height or less

² vitamin D replacement, calcium supplement and either bisphosphonate, strontium, raloxifene, denosumab or teriparatide

Treating units (366)	Osteoporosis workup								
	Renal function		% test ordered	Corrected calcium		% test ordered	25(OH)D		% test ordered
	Yes	No		Yes	No		Yes	No	
Acute Aged Care (84)	84	0	100%	64	20	76.2%	77	7	91.7%
Cardiology (2)	2	0	100%	2	0	100%	1	1	50%
Cardiothoracic (7)	7	0	100%	3	4	42.9%	0	7	0%
Gastroenterology (2)	2	0	100%	2	0	100%	1	1	50%
General Surgery (all units) (6)	6	0	100%	4	2	66.7%	3	3	50%
General Medicine (all units) (42)	42	0	100%	29	13	69%	26	16	61.9%
Nephrology (4)	4	0	100%	4	0	100%	2	2	50%
Neurology (2)	2	0	100%	2	0	100%	1	1	50%
Neurosurgery (4)	4	0	100%	3	1	75%	3	1	75%
Orthopaedics (137)	129	8	94.2%	67	70	48.9%	45	92	32.8%
SAC-NOF/D (76)	76	0	100%	74	2	97.4%	72	4	94.7%
Total % ordered	358	8	97.8%	254	112	69.4%	229	137	62.6%

Table 2 Percentage of essential pathology tests ordered to assess osteoporosis by treating units. SAC-NOF/D Specialised Aged Care- Orthogeriatric/ Delirium unit. 8 patients had none of these tests, all were under Orthopaedics.

Refractory hyperparathyroidism with a T3 bony lesion – differential diagnoses

Daniela WC Chan¹, Diana Moir², Richard Standish², Mark A Kotowicz^{1,3}

1. Department of Endocrinology & Diabetes, Barwon Health, Geelong, VIC, Australia

2. St John of God Pathology, Geelong, Vic, Australia

3. Deakin University School of Medicine, Geelong, Victoria, Australia

Introduction

Primary hyperparathyroidism (pHPT) is common with 85% due to a sporadic solitary adenoma, 10-15% multiglandular disease, and <1% parathyroid carcinoma[1]. Differentiating carcinoma from benign causes at presentation can be difficult. Brown tumour (osteitis fibrosa cystica) is a rare manifestation of severe hyperparathyroidism[2] with locally invasive lesions resembling primary bone tumours or bony metastases[3].

Case report

An 83 year old man admitted with myocardial infarction was incidentally found to have severe, asymptomatic hypercalcaemia (Ca^{2+} 3.13mmol/L) and hyperparathyroidism (PTH>100pmol/L). Neck ultrasound and sestamibi failed to localise a parathyroid adenoma. MRI showed bilateral enlarged inferior parathyroid glands (L 7.6x12x17mm, R 16x14x15mm) and a right T3 bony lesion, not evident on bone scan. PSA and myeloma screens were negative.

Left inferior parathyroidectomy, left hemithyroidectomy, and partial resection of the left recurrent laryngeal nerve with the enlarged right parathyroid gland left in situ were performed due to an intraoperative suspicion of parathyroid carcinoma. Histopathology showed some atypical features with no definite malignant features. Immunohistochemistry for parafibrinogen and PGP9.5 was inconclusive.

Staging CT and FDG PET showed a lytic, hypermetabolic T3 soft tissue bony lesion with local invasion. A right T3 hemilaminectomy was undertaken and histopathological examination indicated a brown tumour. A right parathyroidectomy was then performed and histopathology showed features most consistent with glandular hyperplasia or a parathyroid adenoma. Serum calcium and PTH normalised postoperatively and remained stable.

Conclusion

The presence of the bony lesion with hyperparathyroidism raised the possibility of metastatic parathyroid carcinoma, with a differential diagnosis of primary bone tumour, metastasis with co-existing hyperparathyroidism, or brown tumour. Differentiation of parathyroid carcinoma from other benign tumours may be difficult, due to overlapping clinical, biochemical, imaging and histological features. Regardless, clinical suspicion of parathyroid carcinoma or multigland disease demands that all four parathyroid glands should be thoroughly explored to minimise the risk of recurrence.

1. Silverberg, S.J., M.D. Walker, and J.P. Bilezikian, Asymptomatic primary hyperparathyroidism. *J Clin Densitom*, 2013. 16(1): p. 14-21.
2. De Crea, C., et al., Are brown tumours a forgotten disease in developed countries? *Acta Otorhinolaryngol Ital*, 2012. 32(6): p. 410-5.
3. Hong, W.S., et al., Emphasis on the MR imaging findings of brown tumor: a report of five cases. *Skeletal Radiol*, 2011. 40(2): p. 205-13.

Comparison of four immunoassays for measurement of free Thyroxine (fT4) levels in pregnancy; which assay do you use?

Wei-Ling Chiu¹, Elif Ekinci^{3,1,2}, Zhong Lu^{4,5}, Ken Sikaris⁴, QUE LAM⁶, Intissar Bittar⁶, Karey Chong¹, Nick Crinis⁶, Chris Houlihan^{1,7}

1. Department of Endocrinology, Austin Health, Heidelberg

2. University of Melbourne, Parkville, Victoria

3. Menzies School of Health Research, Darwin

4. Melbourne Pathology, Collingwood

5. Department of Medicine, Monash University, Clayton

6. Austin Pathology, Austin Health, Heidelberg, Victoria

7. Mercy Hospital for Women, Heidelberg

Background: The aim of antithyroid drug treatment of hyperthyroidism due to Graves' disease in pregnancy is to control maternal hyperthyroidism while minimizing risk of fetal hypothyroidism. Consequently, it is recommended in such pregnancies to maintain "free T4 (fT4) values at or just above the upper limit of normal" using trimester-specific fT4 values," or in their absence to use "reference ranges for non-pregnant patients"¹.

Aim: We sought to determine trimester-specific fT4 reference intervals (RI) for common methods used in Australia.

Method: Healthy, thyroid-peroxidase antibody negative women with singleton pregnancy ≤ 13 weeks gestation were followed prospectively throughout pregnancy with samples collected at Trimester-1 (T1), Trimester-2 (T2), Trimester-3 (T3), and postpartum (PP). Serum fT4 was measured by four immunoassays: Beckman DXI800, Roche e602, Abbott Architect and Siemens Centaur. Reference intervals are presented as 95%CI (calculated as mean \pm 2SD). Differences in mean were tested using ANOVA.

Results: Samples from the same group of women were analysed by all four methods. There were 118 women at T1 (11.8 \pm 0.2) (mean \pm SE weeks gestation), 78 at T2 (24.4 \pm 0.3), 63 at T3 (35.9 \pm 0.3) and 73 at postpartum (PP).

Table 1: Assay and trimester specific fT4 reference intervals.

METHOD	T1	T2	T3	PP
n	118	78	63	73
Beckman [7.5-21.1]	10.6 ± 2.4 (5.9-15.4)	8.1 ± 1.6* (4.9-11.3)	7.8 ± 1.7* (4.5-11.1)	10.3 ± 2.3 (5.6-15.0)
Roche [12-22]	15.1 ± 2.7 (9.6-20.6)	12.4 ± 1.9* (8.6-16.2)	11.9 ± 1.9* (8.2-15.6)	15.6 ± 3.0 (9.5-21.7)
Abbott [9.0-19.0]	14.5 ± 2.1 (10.3-18.7)	12.1 ± 1.4* (9.4-14.8)	11.9 ± 1.4* (9.1-14.8)	13.1 ± 1.8 (9.4-16.8)
Siemens [10-19]	17.0 ± 2.1 (12.7-21.2)	14.6 ± 1.5* (11.5-17.7)	14.9 ± 1.6* (11.8-18.0)	16.0 ± 2.5 (11.0-20.9)

fT4 results (pmol/L) are shown as mean±SD (95% Confidence Intervals). The manufacturer quoted non-pregnant reference intervals are shown in []. * $p < 0.001$ for T2 or T3 versus T1 in each method.

Within each method, all showed an approximate 15-20% decrease in fT4 in T2 and T3 compared to T1. Between methods, significant differences were present at all time points. The Beckman method was approximately 30% lower than the Roche and Abbott methods, and 45% lower than the Siemens method. Roche and Abbott gave similar results.

Conclusion: Both gestation and assay method had a significant influence on fT4 results in pregnant women. Knowledge of trimester and method specific reference intervals assists in optimizing antithyroid drug therapy in pregnancies affected by Graves' disease.

1. Stagnaro-Green A, Abalovich M, Alexander E, et al. Guidelines of the American Thyroid Association for the Diagnosis and Management of Thyroid Disease During Pregnancy and Postpartum. *Thyroid*. 2011;21(10):1081-25.

A case of postpartum adrenocortical carcinoma

Darshika J Christie-David^{2,1}, **Howard C Smith**^{2,1}

1. Diabetes and Endocrinology, Westmead Hospital, Sydney

2. The University of Sydney, Sydney

A 21 year old female with a new diagnosis of hypertension, eight months post-partum following an uncomplicated pregnancy. Symptomatology included headache, palpitations, increased appetite, bruising and hirsutism. Imaging identified a large left adrenal mass (6.5cm) and multiple lung nodules. Hypertension was managed with phenoxybenzamine and propranolol initially for possible pheochromocytoma. Endocrine investigations showed normal aldosterone:renin ratio, normal plasma and urine metanephrines and normetanephrines, normal DHEA and androstenedione. However, morning cortisol was elevated, with elevated 24-hour urinary free cortisol:creatinine ratio, and elevated midnight cortisol with a suppressed midnight ACTH. MIBG scan showed no uptake, whereas PET scan demonstrated a metabolically active left adrenal mass and innumerable metabolically active pulmonary metastases.

Video-assisted thoracoscopic surgery for biopsy of lung metastases confirmed metastatic adrenocortical carcinoma (Ki67 60%, IGF2 positive, IGF-1R positive, ER negative, PR positive). In the absence of symptoms or signs of Cushing's syndrome in pregnancy, this 21 year old female had a rapidly progressive cortisol-secreting adrenocortical carcinoma (ACC) post-partum.

Blood pressure control was achieved with spironolactone and nifedipine with weaning of alpha blockade. Ketoconazole was initiated then changed to metyrapone due to worsening acne and hirsutism. The patient was planned for palliative chemotherapy with etoposide, doxorubicin and cisplatin with mitotane. However, the patient passed away within two months of her initial hospital admission.

There are 24 cases described in the literature of ACC arising in pregnancy or post-partum. According to one study, ACC arising in pregnancy and post-partum are associated with worse overall survival than ACC diagnosed in women who have not been pregnant (1). A proposed mechanism for this difference is the stimulation of hormone receptors on adrenal tumours during pregnancy.

1. Abiven-Lepage G, Coste J, Tissier F et al. Adrenocortical carcinoma and pregnancy: clinical and biological features and prognosis. *European Journal of Endocrinology* 2010; 163: 793–800

A delicate pregnancy

Melissa Clarke¹, Anna McLean^{1,2}, Ashim Kumar Sinha^{1,2}, Nirjhar Nandi¹

1. Endocrinology Department, Cairns Hospital, Cairns, QLD, Australia

2. Department of Medicine, James Cook University, Cairns, QLD, Australia

Case Presentation

A 41-year-old G1P0 Caucasian lady presented with atraumatic polyarticular pain on a background of obesity and likely polycystic ovarian syndrome. She developed left knee pain at 17 weeks gestation followed by severe right knee and bilateral hip pain at 28 weeks. She was unable to weight bear due to pain. Later, she developed gestational diabetes mellitus.

Based on the MRI findings of the hips and knees which showed bony oedematous changes, a diagnosis of transient osteoporosis of pregnancy (TOP) was made. Postpartum BMD showing lumbar spine Z score of -1.9 (T score -1.8) and femoral neck Z score of -3.6 (T score -3.9) and fractures at T7 and T8 on x-ray confirmed the diagnosis. Secondary osteoporosis screen was unremarkable.

At 38 weeks, the patient had an uncomplicated elective caesarian section. The patient returned to full weight bearing over the following 6 months. At six months post partum, there was resolution of the bony oedematous changes on MRI. At seven months, lumbar Z score improved to -1.7 (T score -1.5) and left hip Z score to -2.3 (T score -2.6).

Discussion

Transient Osteoporosis of Pregnancy (TOP) is a rare condition that typically presents in the third trimester of pregnancy with severe hip pain on weight bearing, sometimes with fracture.¹ There is only one prior case report of polyarticular TOP. 2 Symptoms and imaging changes resolve without intervention within weeks to months postpartum.³

Our TOP case is unique because of simultaneous multiple sites of involvement.

Differential diagnosis includes transient migrating osteoporosis of pregnancy.⁴ Other conditions including avascular necrosis, infection, and non-osteoporotic stress fractures were ruled out.¹ It is unclear if genetic causes (e.g. LRP5 mutation) should be searched for.⁵ Aetiology of TOP is unclear. Treatment is conservative and involves rest, vitamin D and calcium replacement.¹

1. Maliha, G., Morgan, J., & Vrahas, M. (2012) Transient osteoporosis of pregnancy. *Injury*, 43, 1237-1241.
2. Ma, F.Y.P., & Falkenberg, M. (2006) Transient Osteoporosis of the Hip. *Clinical Orthopaedics and Related Research*, 445, 245-249.
3. Lequesne, M. (1968) Transient osteoporosis of the hip: a nontraumatic variety of sudeck's atrophy. *Ann Rheum Dis*, 27, 463-471.
4. Uzum, M., Ayhan, E., & Beksac, B. (2013) Regional migratory osteoporosis and transient osteoporosis of the hip: are they all the same? *Clin Rheumatol*, 32, 919-923.
5. Campos-Obando, N., Oei, L., Hoefsloot, L.H., Kiewiet, R.M., Klaver, C.C.W., Simon, M.E.H., & Zillikens, M.C. (2014) Osteoporotic Vertebral Fractures During Pregnancy: Be Aware of a Potential Underlying Genetic Cause. *J Clin Endocrinol Metab*, 99(4), 1107-1111.

A case of flaccid quadriplegia due to concurrent presentation of thyrotoxic hypokalaemic periodic paralysis and severe thyrotoxic myopathy complicating Graves' disease

Sheila J Cook¹, Sam Fogarty¹, Jacob Wembri¹, Erin Ridler¹

1. Toowoomba Health Service, Toowoomba, QLD, Australia

We present the case of a 42 year old woman from Papua New Guinea with Graves' Disease, who presented with sudden onset of flaccid quadriplegia, facial diplegia and hypophonia in the setting of thyroid storm. Severe hypokalaemia (2.7mmol/L) was treated initially with aggressive intravenous potassium supplement, but responded quickly to the addition of Propranolol as part of the definitive management of the thyrotoxicosis. However, despite normalization of the serum potassium, the weakness persisted to include respiratory muscles, thus leading to intubation and ventilation. In the ICU, a combination of Carbimazole, Dexamethasone, Propranolol and Lugol's Iodine led to a rapid resolution of the biochemical thyrotoxicosis (FT4 57 reduced to 16 after 3 days). The weakness was slow to improve and predominantly affected proximal muscles in the lower limbs and bulbar muscles. CK was only mildly elevated, Acetylcholine Receptor antibodies were negative. Acid fast bacilli were identified in the sputum and pleural fluid to confirm active multi-drug resistant tuberculosis as the precipitant for the thyroid storm. She is being treated with a combination of six anti-tuberculous antibiotics.

Thyrotoxic¹ periodic paralysis is a rare complication of thyrotoxicosis that usually affects Asian males and is characterized by sudden onset of hypokalaemia and weakness. The weakness typically responds quickly to normalization of the serum potassium, which is achieved with beta-blockers and anti-thyroid drugs. Thyrotoxic myopathy² typically presents as proximal weakness which slowly recovers with resolution of the thyrotoxicosis. It rarely causes flaccid quadriplegia and bulbar muscle weakness.

Our patient presents with the combination of two very rare complications of thyrotoxicosis. The sudden onset of weakness and hypokalaemia was in keeping with thyrotoxic periodic paralysis, while the slow recovery of muscle function in association with normalization of thyroid function was typical of severe thyrotoxic myopathy. This is the first time this combination has been described.

1. Vijayakumar A, Ashwath G, Thimmappa D. Thyrotoxic Periodic Paralysis: Clinical Challenges. *J Thyroid Res*. 2014; Feb 20

Cracks in the system: pelvic fractures do not lead to intensification of osteoporosis management

Dahlia Davidoff¹, Harvey Newnham¹, Vathy Nagalingham¹

1.Alfred Health, Windsor, VIC, Australia

Background

Unlike fracture of the femoral neck, osteoporotic pelvic fractures that do not require procedural intervention may receive scant attention despite significant risks of morbidity and mortality (1-3). Initiation or modification of osteoporotic therapies including calcium, vitamin D and bone remodelling agents, most commonly bisphosphonates, may be neglected in favour of more acute priorities of pain relief and mobilisation. The aim of this study was to determine if patient factors including discharge disposition and mobility were associated with modification to osteoporosis treatment during an admission with pelvic fracture.

Methods

We retrospectively reviewed medical records of patients aged 65 years and older who were admitted to the General Medicine Unit between July 2010 and June 2013 for pelvic fracture. Osteoporosis therapy was defined as treatment with calcium, vitamin D and/ or bone remodelling agents. Group A were discharged on no therapy or one medication and Group B were discharged on two or three osteoporosis medications.

Results

158 patients met the inclusion criteria. There were 77 patients in Group A and 81 patients in Group B. Factors such as discharge to high level care or very poor mobility, did not differ between groups ($p=0.57$ and $p=0.08$ respectively). There were significantly less patients from Group A on vitamin D (OR 2.27, CI 1.16-4.42, $p = 0.016$), calcium supplementation (OR 4.72, CI 2.16-10.3, $p = 0.009$) or bone remodelling agents (OR 2.84, CI 1.3-6.22, $p = 0.009$) on arrival to hospital. Therefore the most significant determinant of discharge medications was admission medications.

Conclusion

Hospital admission for pelvic fracture does not change osteoporosis treatment in our hospital. Plans for osteoporosis management should be reviewed during discharge planning for all pelvic fracture patients. We plan to assess the effect of management algorithms with check-listing of interventions and follow-up for all elderly fracture patients.

1. Pasco JA, Sanders KM, Hoekstra FM et al. The human cost of fracture. *Osteoporos Int*. 2005;16(12):2046-52.
2. Boufous A, Finch C, Lord S et al. The increasing burden of pelvic fractures in older people, New South Wales, Australia. *Injury*. 2005;36(11):1323-9.
3. Soles GL, Ferguson TA. Fragility fractures of the pelvis. *Curr Rev Musculoskelet Med*. 2012;5(3):222-228.

The prevalence of BRAF V600E mutation and its associated histopathology features in papillary thyroid carcinoma in New Caledonia and Australia

Veronica Dy¹, Triyana Lie¹, Catherine Woolnough², Jessie A Tubb¹, Dominique Dubourdieu³, Vivienne Damiens³, Susan V McLennan^{1,2}, Elizabeth L Chua^{1,2}

1.University of Sydney, Sydney, NSW, Australia

2.Endocrinology, Royal Prince Alfred Hospital, Camperdown, NSW, Australia

3.Laboratoire d'Anatomie et Cytopathologie, Nouméa, Noumea, New Caledonia

New Caledonia (NC), a French territory in the Pacific, has the highest incidence of thyroid cancer with an age standardized incidence rate of 71.4/100,000 in Melanesian women[1]. To date, the only molecular genetic study in this population was on RET/PTC in papillary thyroid carcinoma (PTC)[2]. The prevalence of BRAF V600E mutation and its association with histopathology features is not known. Therefore, we aim to investigate the BRAF V600E mutation status in NC patients with PTC and compare this to an Australian cohort.

The BRAF V600E mutation status was determined in 87 micro-dissected Formalin Fixed Paraffin Embedded (FFPE) PTC tumour tissue obtained from Laboratoire d'Anatomie et Cytopathologie, Nouméa, New Caledonia($n=30$) and from Royal Prince Alfred Hospital, Australia ($n=57$). Pathological data were obtained from histopathology reports and patients' medical records. Data was analyzed using Chi squared analysis.

In both populations, PTC was more common in females, similar to the pattern worldwide. 47% of NC PTC were multifocal involving both lobes. BRAF V600E prevalence was 64% in NC and 55% in the Australian cohort. Furthermore, the mutation was significantly more common in NC multifocal bilateral tumours (NC: 88% vs Australian: 67%, $P<0.005$).

Table 1: Demographic, Histopathology and BRAF V600E Prevalence

Variables	New Caledonia (n=30)	Australia (n=57)
Female : Male	22:11 (2:1)	46:18 (2.5:1)
Multifocal	47%	44%
unilateral	3/14 (21%)	8/25 (32%)
bilateral	11/14 (79%)	17/25 (68%)

BRAF V600E +ve	N=21 (64%)	N=35 (55%)
Multifocal	9/21 (44%)	13/35 (37%)
unilateral	1/9 (12%)	4/13 (33%)
bilateral	8/9 (88%)*	9/13 (67%)

*P<0.005 different from the Australian population

The high prevalence of the BRAF V600E mutation in the NC population suggests its utility as a diagnostic marker of PTC. Further the association of the BRAF V600E mutation in the NC cohort with multifocal bilateral PTC may indicate more aggressive tumours in these individuals.

1. Truong T et al Eur J Cancer Prev, 2007, 16:62-70
2. Chua E et al J Clin Endo and Metab, 2000,85:2733-2739

ARMC5 mutations are common in Familial Bilateral Macronodular Adrenal Hyperplasia

Lucy Gagliardi^{1, 2, 3}, Andreas W Schreiber^{4, 5}, Chris N Hahn^{2, 3}, Jinghua Feng^{4, 5}, Treena Cranston⁶, Hannah Boon⁶, Cheri Hotu⁷, Bergithe E Oftedal^{2, 8}, Richard Cutfield⁹, David L Adelson⁵, Wilton J Braund¹⁰, Richard D Gordon^{11, 12}, D A Rees¹³, Ashley B Grossman¹⁴, David J Torpy^{1, 3}, Hamish S Scott^{2, 3, 4, 5, 15}

1. Endocrine and Metabolic Unit, Royal Adelaide Hospital, Adelaide, SA, Australia
2. Genetics and Molecular Pathology, SA Pathology, Adelaide, SA, Australia
3. School of Medicine, University of Adelaide, Adelaide, SA, Australia
4. ACRF Cancer Genomics Facility, Centre for Cancer Biology, SA Pathology, Adelaide, SA, AUSTRALIA
5. School of Molecular and Biomedical Science, University of Adelaide, Adelaide, SA, Australia
6. Oxford Medical Genetics Laboratories, Oxford University Hospitals NHS Trust, Oxford, LE, United Kingdom
7. Department of Endocrinology, Auckland District Health Board, Auckland, New Zealand
8. Department of Clinical Science, University of Bergen, Bergen, Norway
9. Department of Endocrinology, Waitemata District Health Board, Auckland, New Zealand
10. Department of Endocrinology, Flinders Medical Centre, Adelaide, SA, Australia
11. School of Medicine, University of Queensland, Brisbane, Qld, Australia
12. Endocrine Hypertension Research Centre, Greenslopes and Princess Alexandra Hospitals, Brisbane, Qld, Australia
13. Centre for Endocrine and Diabetes Sciences, School of Medicine, University of Cardiff, Cardiff, United Kingdom
14. Oxford Centre for Diabetes, Endocrinology and Metabolism, Churchill Hospital, University of Oxford, Oxford, United Kingdom
15. School of Pharmacy and Medical Sciences, Division of Health Sciences, University of South Australia, Adelaide, SA, Australia

Context

Bilateral macronodular adrenal hyperplasia (BMAH) is a rare form of adrenal Cushing's syndrome. Familial cases have been reported but at the time we conducted this study, the genetic basis of BMAH was unknown. Recently, germline variants of armadillo repeat containing 5 (*ARMC5*) in patients with isolated BMAH, and somatic, second-hit mutations in tumor nodules were identified.¹

Objective - To identify the genetic basis of familial BMAH.

Design - We performed whole exome capture and sequencing of two affected individuals from each of three BMAH families we have previously described (BMAH-01, BMAH-02, BMAH-03) and one additional kindred (BMAH-05).² Based on clinical evaluation there were seven, three, three and four affected individuals in these families, respectively. Sanger sequencing of *ARMC5* was performed in one other BMAH kindred, BMAH-06.

Results - Exome sequencing identified novel variants: Chr16:g.31477540, c.2139delT, p.(Thr715Leufs*1) (BMAH-02) and Chr16:g.31473811, c.943C>T, p.(Arg315Trp) (BMAH-03) in *ARMC5* (GRCh37/hg19), validated by Sanger sequencing. BMAH-01 had a recently reported mutation Chr16:g.31476121, c.1777C>T, p.(Arg593Trp). Sanger sequencing of *ARMC5* in BMAH-06 identified a previously reported mutation, Chr16:g. 31473688; c.799C>T, p.(Arg267*). The genetic basis of BMAH in BMAH-05 was not identified.

Conclusions - Our studies have detected *ARMC5* mutations in four of five BMAH families tested, confirming that these mutations are a frequent cause of BMAH. Two of the four families had novel mutations, indicating allelic heterogeneity. Preclinical evaluation did not predict mutation status. The *ARMC5* negative family had unusual prominent hyperaldosteronism. Further studies are needed to determine the penetrance of BMAH in *ARMC5* mutation-positive relatives of affected patients, the practical utility of genetic screening and genotype-phenotype correlations.

1. Assié G, Libé R, Espiard S, Rizk-Rabin M, Guimier A, Luscip W, Barreau O, Lefèvre L, Sibony M, Guignat L, Rodriguez S, Perlemoine K, René-Corail F, Letourneur F, Trabulsi B, Poussier A, Chabbert-Buffet N, Borson-Chazot F, Groussin L, Bertagna X, Stratakis CA, Ragazzon B, Bertherat J. *ARMC5* Mutations in Macronodular Adrenal Hyperplasia with Cushing's syndrome. *New Engl J Med* 2013; 369:2105-14

2. Gagliardi L, Hotu C, Casey G, Braund WJ, Ling KH, Dodd T, Manavis J, Devitt PG, Cutfield R, Rudzki Z, Scott HS, Torpy DJ. Familial Vasopressin-sensitive ACTH-Independent Macronodular Adrenal Hyperplasia (VPs-BMAH): Clinical Studies of Three Kindreds. *Clin Endocrinol (Oxf)* 2009; 70:883-91.

Clinical practice patterns in the assessment and management of low testosterone in men: an international survey of endocrinologists

Mathis Grossmann¹, Bradley D D Anawalt², Frederick CW Wu³

1.University of Melbourne, Austin Health, Heidelberg, VIC, Australia

2.Department of Medicine, University of Washington Medical Center, Seattle, Washington 98195, USA

3.Andrology Research Unit, School of Biomedicine, University of Manchester, Manchester M13 9WL, United Kingdom

Context: Given that recommendations on the approach to low testosterone in older men are based on low-level evidence, we hypothesized that there would be a wide variability in clinical practice patterns.

Objective: To document current practices among members of U.S., European and Australasian endocrine and andrology societies.

Design, Setting and Participants:Members of The Endocrine Society, the American Association of Clinical Endocrinologists, the European Endocrine Society, the Endocrine Society of Australasia, the American Society of Andrology, and the European Academy of Andrology were invited to participate in a web-based survey of the diagnostic work-up and management of a hypothetical index case of a 61-year old overweight man presenting with symptoms suggestive of androgen deficiency, without evidence of hypothalamic-pituitary-gonadal (HPT) axis disease.

Results:943 respondents (91.2% adult endocrinologists) from Northern America (63.7%), Europe (12.7%), Oceania (8.2%), Latin America and Caribbean (7.6%), and the Middle East, Asia, or Africa (7.8 %) completed the survey. There was a wide variability in clinical practice patterns, especially regarding biochemical diagnosis of androgen deficiency, exclusion of HPT axis pathology, and monitoring for prostate cancer. In a man with suggestive symptoms, 42.4% of participants would offer testosterone treatment below a serum total testosterone of 10.4 nmol/L (300ng/dl). 46.0% of participants were, over the last five years, "less inclined" to prescribe testosterone to men with nonspecific symptoms and borderline testosterone levels, compared to "no change" (29.3%) or "more inclined" (24.7%), $p < 0.001$.

Conclusions:This large-scale international survey shows a wide variability in the management of lowered testosterone in older men, with deviations from current clinical practice guidelines, and a temporal trend towards increasing reluctance to prescribe testosterone to men without classical hypogonadism. These findings highlight the need for better evidence to guide clinicians regarding testosterone therapy.

Primary hyperparathyroidism and the relationship between 25-vitamin D, 1,25 vitamin D and parathyroid hormone: A prospective case series

Thomas I Hadwen¹, Melissa S Clarke², Ashim K Sinha², Anna G McLean²

1.Princess Alexandra Hospital, Brisbane, QLD, Australia

2.Cairns Base Hospital, Cairns, QLD, Australia

Introduction

Primary hyperparathyroidism is a common endocrinological disease with an evolving clinical presentation¹. Vitamin D deficiency is more common in PHPT than the general population, partly related to the elevated PTH converting 25-hydroxyvitaminD into 1,25-dihydroxyvitaminD². Observational studies have shown that a low 25-hydroxyvitaminD is associated with reduced BMD, post-op hypocalcaemia and elevated PTH³. In a small RCT 25-hydroxyvitaminD replacement decreased PTH and increased lumbar BMD without increasing adverse events³. The role of 1,25-dihydroxyvitaminD was not investigated.

Aims/Objectives

To analyse the data of patients with PHPT looking for correlations between PTH, calcium, 25-hydroxyvitaminD, 1,25-dihydroxyvitaminD and 25-hydroxyvitaminD replacement.

Methods

We performed a prospective case series of all patients referred to the Cairns Hospital endocrine outpatients clinic with hypercalcaemia.

Results

49 patients with hypercalcaemia were identified. 40 were diagnosed with PHPT. Average corrected calcium in the PHPT group, expressed as mmol/L above normal, was 0.2. The average PTH, expressed as a multiple above normal, was 1.73. The average 25-hydroxyvitaminD was 61nmol/L (50-150), the average 1,25-dihydroxyvitaminD was elevated at 173pmol/L (40-150). There was a statistically significant difference in PTH level between vitamin D replete and deficient groups, 1.51 and 2.45 times normal respectively ($p=0.003$) without a difference in corrected calcium. The correlation factor of PTH and 25-hydroxyvitaminD was -0.56. The correlation factor of PTH and 1,25-dihydroxyvitaminD was 0.43. There was a negative correlation between 25-hydroxyvitaminD and 1,25-dihydroxyvitaminD ($r=-0.64$). Replacing vitamin D did not alter hypercalcaemia.

Conclusion

In our study low 25-hydroxyvitaminD is associated with increased PTH but not hypercalcaemia and 25-hydroxyvitaminD replacement didn't worsen hypercalcaemia. Interestingly, 25 and 1,25-hydroxyvitaminD are inversely related. There is conflicting evidence about this relationship in the literature⁴. The proposed mechanism for 25-hydroxyvitaminD replacement suppressing PTH is by increasing the level of 1,25-hydroxyvitaminD. Our finding of elevated 1,25-hydroxyvitaminD in the vitamin D deficient does not support this.

1. Yu N, Donnan P, Murphy M, Leese G. Epidemiology of primary hyperparathyroidism in Tayside, Scotland. *Clinical Endocrinology*. 2009. 71:485–493
2. Tassone F, Gianotti L, Baffoni C, Visconti G, Pellegrino M, Cassibba S, Croce C, Magro G, Cesario F, Attanasio R, Borretta G. Vitamin D status in primary hyperparathyroidism: a Southern European perspective. *Clinical Endocrinology*. 2013. 79: 784–790
3. Rolighed L, Rejnmark L, Sikjaer T, Heickendorff L, Vestergaard P, Mosekilde L, Christiansen P. Vitamin D Treatment in Primary Hyperparathyroidism: a Randomized Placebo Controlled Trial. *Journal of Clinical Endocrinology and Metabolism*. 2014. 99:1072-1080
4. Moosgaard B, Vestergaard P, Heickendorff L and Mosekilde L. Plasma 1,25-dihydroxyvitamin D levels in primary hyperparathyroidism depend on sex, body mass index, plasma phosphate and renal function. *Clinical Endocrinology*. 2007. 66:35–42

Challenges of managing Cushing's disease in pregnancy

Thomas Hadwen¹, Ken Ho

1.Princess Alexandra Hospital, Brisbane, QLD, Australia

This is a case of a 29 year old female with persistent Cushing's disease after repeat surgery, wishing to become pregnant. Cushing's disease/syndrome in pregnancy is associated with significant maternal and/or fetal morbidity and mortality in approximately 70% of cases. For the mother there is an increased risk of hypertension, diabetes, osteoporosis with fracture, poor wound healing and preeclampsia. For the fetus there is a high rate of premature birth as well as increased risk of intrauterine growth restriction, miscarriage and still birth.

The treatment options during pregnancy are either surgical or medical. A review of published cases has shown that treatment is associated with a 13% increase in the rate of live births (76% to 89%). Metyrapone is the most commonly used and is generally well tolerated but has been associated with hypertension and preeclampsia. Ketoconazole has been used in 3 pregnancies with no adverse events. Somatostatin analogues and dopamine agonists are other possibilities but there is little experience or proof of efficacy.

Monitoring the efficacy and titrating the dosing of treatment in Cushing's disease during pregnancy is complicated by the physiological hypercortisolaemia of pregnancy which can result in an up to three times elevation in urinary free cortisol.

Our case is of a 29 year old female with active Cushing's disease who wishes to become pregnant. We review the available evidence in relation to the complications, treatment and monitoring of Cushing's disease during pregnancy and discuss the options for optimizing maternal and fetal outcomes.

1. Lindsay et al 2005 Cushing's Syndrome during Pregnancy: Personal Experience and Review of the Literature *J Clin Endocrinol Metab* 90:3077-83
2. Berwaerts et al 1999 Cushing's syndrome in pregnancy treated by ketoconazole: Case report and review of the literature. *Gynecol Endocrinol* 13:175–182
3. Caron et al 2010 Acromegaly and Pregnancy: A Retrospective Multicenter Study of 59 Pregnancies in 46 Women. *J Clin Endocrinol Metab* 95: 4680–4687
4. Lindsay JR and Nieman LK 2005 The hypothalamic-pituitary-adrenal axis in pregnancy: Challenges in disease detection and treatment. *Endocr Rev* 26:775-99
5. Feldt-Rasmussen and Mathiesen 2011 Endocrine disorders in pregnancy: Physiological and hormonal aspects of pregnancy. *Best Practice & Research Clinical Endocrinology & Metabolism* 25: 875–884

Management of hypoparathyroidism in pregnancy and lactation - A report of 11 cases

Brianna L Hatswell¹, C A Allan^{3,4,2}, J Teng^{2,1}, P Wong^{3,2,1}, P J Fuller^{3,2,1}, F Milat^{3,2,1}

1.Department of Medicine, Monash University, Clayton

2.Department of Endocrinology, Monash Health, Clayton

3.Monash Institute of Medical Research, Prince Henry's Institute, Clayton

4.Department of Obstetrics and Gynaecology, Monash Health, Clayton

Hypoparathyroidism is rare in pregnancy with limited case reports and no established management guidelines reported in the literature. However, hypoparathyroidism is important as it is associated with maternal morbidity and fetal loss. Optimal maintenance of calcium levels within lower normal range during pregnancy is required to minimise risk of related complications. Variable responses to calcitriol and calcium, and altered calcium homeostasis during pregnancy and lactation make the management of this condition challenging. Monash Health's maternity service is the largest maternity provider in Victoria, with an associated database that captures birthing outcomes in over 9,000 women each year. We audited the database between 2000-2014 to examine the clinical course, treatment, and maternal and fetal outcomes of pregnant women with hypoparathyroidism. We identified 11 pregnancies from 6 women with pre-existing hypoparathyroidism secondary to thyroid surgery for Graves disease (n=3) and thyroid cancer (n=1), DiGeorge syndrome (n=3), idiopathic hypoparathyroidism (n=3), and familial hypoparathyroidism (subsequently diagnosed with autosomal dominant hypocalcemia with hypercalciuria) (n=1). In all cases, maternal calcium levels were monitored through pregnancy, and calcitriol and calcium doses adjusted to maintain normocalcemia. One woman delivered by caesarean section at 34 weeks gestation in the setting of IUGR and oligohydramnios in two pregnancies. The perinatal course was otherwise uneventful in the remaining pregnancies. The postpartum period was complicated by severe hypercalcemia in one woman 9 days postpartum and by symptomatic, labile serum calcium levels during lactation in another woman which required close monitoring over a 6 month period. Although rare, hypoparathyroidism in pregnancy poses a management challenge for clinicians and co-ordinated care is required between obstetricians and

endocrinologists to ensure optimal outcomes for mother and baby. Continued monitoring of maternal calcium levels during lactation and weaning is required to avoid the potential complications of hypercalcemia or hypocalcemia.

252

Evolution of a pheochromocytoma in an elderly woman: clinical, biochemical and radiological features

Nicholas Hockings¹, Jason Hockings^{1,2}, Sofia Velosa^{1,3}, Christopher Strakosch^{1,3}, Christine Rowland^{1,3}, Nick Daunt^{3,4}, Gregory Hockings^{1,3}

1. Endocrinology Unit, Greenslopes Private Hospital, Brisbane, Qld, Australia

2. Princess Alexandra Hospital, Brisbane, Qld, Australia

3. School of Medicine, University of Queensland, Brisbane, Qld, Australia

4. Queensland XRay, Greenslopes Private Hospital, Brisbane, Qld, Australia

In 1999 a healthy 73-year-old woman was found to have an incidental solid lesion in her right adrenal gland on CT (2.0 cm diameter). She had intermittent mild systolic hypertension but no postural symptoms and was not taking any medications. She gradually developed sustained hypertension and was commenced on amlodipine in 2005; irbesartan was added in 2007.

Her mother had hypertension and died of a cerebrovascular event aged 76 years; her two brothers were alive and well. Initial endocrine investigations, including 24-hour urinary fractionated catecholamines, were normal.

Follow-up CT scans were initially unchanged but in 2003 the lesion's diameter was 2.3 cm and it had developed a small cystic component. By 2010, it had grown to 2.7 cm (3.2 cm on coronal views), with further cystic degeneration/necrosis and a reduction in its absolute contrast washout from 71% (in 2006) to 12%.

Adrenal function tests were repeated in 2010; plasma and 24-hour urinary metadrenaline and normetadrenaline and urinary adrenaline were elevated. I-123 MIBG scan showed avid isotope uptake by the adrenal mass. Pheochromocytoma was diagnosed and the patient's anti-hypertensive medications were progressively changed to phenoxybenzamine and propranolol.

She underwent laparoscopic right adrenalectomy in early 2011. Histopathology confirmed a pheochromocytoma, with a diameter of 4.8 cm and focal extension into peri-adrenal adipose tissue. She has remained normotensive post-operatively, with normal plasma and urinary catecholamine levels. In 2013 she underwent successful total knee replacement surgery and continues to live independently. She does not have any children, nephews or nieces and has declined genetic testing.

Pheochromocytomas may pass through a "pre-biochemical" stage of development in which they are asymptomatic and their catecholamine secretion is not elevated¹. This patient's non-functioning adrenal lesion evolved into a symptomatic pheochromocytoma over a lengthy period, indicating the need for ongoing follow-up of small and initially non-functioning adrenal "incidentalomas".

1. Young WF in Estey MP, Diamandis EP, Eisenhofer G et al Clin Chem 2013; 59(3): 466-472.

253

An unusual cause of marked insulin resistance in a patient with type 2 diabetes mellitus

Rajini Jayaballa¹, Rohit Rajagopal¹

1. Campbelltown Hospital (NSW), Campbelltown, NSW, Australia

Background: Insulin resistance is a hallmark feature of type 2 diabetes mellitus. It is not uncommon that some patients with type 2 diabetes mellitus require large doses of insulin. However it is important to consider other causes of insulin resistance in patients whose glycaemic control remains suboptimal despite increasing doses of insulin. We present a case of a patient with poorly controlled type 2 diabetes mellitus and marked insulin resistance due to hyperandrogenism.

Case Description: A 47 year old female presented with poorly controlled type 2 diabetes mellitus, HbA1c 10.3% (89 mmol/mol), despite large doses of insulin up to 338 units daily. In addition, the patient reported sudden onset amenorrhoea with hirsutism on a past history of possible polycystic ovarian syndrome (PCOS). Biochemical testing showed an extremely high total testosterone level of 14.4 nmol/L (reference range 0.2-1.8 nmol/L) with normal adrenal androgens. This level is a lot higher than what one would expect from PCOS alone. Subsequent localisation studies revealed bilateral bulky ovaries. As the patient was close to menopausal age and fertility was no longer an issue, she proceeded to undergo a bilateral salpingo-oophorectomy and total abdominal hysterectomy. Histopathology revealed bilateral ovarian hyperthecosis, a rare cause of hyperandrogenism. Her testosterone level fell to 0.8 nmol/L day one after surgery. Three months following surgery, her testosterone level remained normal and there was a significant improvement in her glycaemic control with HbA1c of 7.7% (61 mmol/mol), and the patient reported multiple hypoglycaemic episodes despite reduction in her insulin dosage.

Conclusion: Although insulin resistance is a paramount feature of type 2 diabetes mellitus, other causes of insulin resistance need to be considered in patients with suboptimal glycaemic control despite large insulin doses. Hyperandrogenism is a well recognized cause of insulin resistance and should be sought after in patients with suggestive clinical features.

254

Solitary Pituitary Metastasis

Tripti Joshi¹, Shamasunder Acharya¹, Stephen Bigbie², Andre Van Westhuizen³, Mitchel Hansen¹

1. John Hunter Hospital, New Lambton, NSW, Australia

2. Medical Oncology, Port Macquarie Base Hospital, Port Macquarie, NSW, Australia

3. Medical Oncology, Calvary Mater, Newcastle, NSW, Australia

A 68 year-old lady, transferred from a peripheral hospital with a 3-week history of lethargy, headaches, visual disturbance, retro-orbital pain, nausea, and vomiting. MRI brain had revealed a large pituitary mass suggestive of a pituitary adenoma. Her past history was significant for a melanoma resected from the back 1 year ago with a 2cm margin. A recent CT chest was suspicious for a right lung upper lobe lesion.

There was no ophthalmoplegia and formal visual field testing showed minor deficits.

The initial pituitary profile revealed deficiencies of cortisol and thyroid axis. She was started on replacement doses of thyroxine and hydrocortisone.

Given the history of prior melanoma, possibility of pituitary metastasis was considered. PET scan revealed multiple hypermetabolic lesions in bilateral lungs and a moderate sized area of avid uptake in the pituitary fossa.

MRI of the pituitary revealed a pituitary mass measuring 15 x12 mm, abutting the optic chiasm and extending into the cavernous sinus, with no other lesions in the brain.

The patient developed diabetes insipidus, 7 days post admission requiring intranasal Desmopressin.

The biopsy from the original melanoma tumor was negative for BRAF mutation, making the patient ineligible for targeted therapy.

Transphenoidal surgery / biopsy of the pituitary mass was considered as the treating oncology team favoured resection to enable better treatment options, but following multi-disciplinary team consultation it was decided against in view of likely metastatic disease.

She developed progressive metastatic disease involving the brain despite cranial irradiation post discharge.

The repeat MRI brain revealed stable pituitary lesion and a possible new metastasis to the right with reduction in headaches. The lung lesions were stable with no new systemic metastasis on the repeat CT scan.

It was decided to proceed with immunotherapy, if patient responded.

However, patient rapidly deteriorated and succumbed.

255

A giant retroperitoneal teratoma encasing the adrenal gland and persistent adrenal Insufficiency

Tripti Joshi¹, Shamasunder ACHARYA¹, PHILLIP WOODFARD¹, JON GANI¹

1. John Hunter Hospital, New Lambton, NSW, Australia

Large retroperitoneal teratomas involving adrenal gland are exceedingly rare.

A 29 year old male was found to have a large right renal /adrenal mass on CT scan whilst being worked up for hypertension in 2004. He was lost to follow up and represented in 2012 with abdominal discomfort. A repeat CT scan, showed this large and complex mass arising from the right kidney measuring 23 x 23 x 26 cm, encasing the dual renal arteries, causing right urinary tract obstruction. An elective right nephrectomy and removal of the mass was performed through laparotomy and median sternotomy, after consulting multi-disciplinary team.

The histology was suggestive of a mature teratoma with mucinous borderline proliferation with no secretory component arising from retroperitoneum. There was extensive perirenal fibrosis and necrosis. The right adrenal gland was compressed and trapped in the mass.

He had a complicated post-operative course and was hypotensive requiring vasopressors. Unexpectedly, he was found to have a low cortisol level of 276nmol/L at 0500 hrs. and 302nmol/L at 0800hrs on two separate occasions in the intensive care, which appeared to be low for his critical illness.

He received hydrocortisone replacement from 3rd post-operative day with improvement in his blood pressure.

Repeat cortisol was 205nmol/L with an ACTH level of 19.8pmol/L (RR 0-10). An outpatient short-synacthen test on two occasions found him to be glucocorticoid deficient. The adrenal antibodies were negative. The renin was 1.3ng/ml/hr. (1.2-2.8), Aldosterone 66 pmol/L (80-1040) with an aldosterone renin ratio of 1.8 (0-30). The 17-hydroxy progesterone was 10.2 nmol/L(<10.3) following synacthen stimulation making classic and non-classic congenital adrenal hyperplasia unlikely.

The tumor markers were negative: AFP 1IU/L (RR<8), HCG <2IU/L (RR <5).

We present a case of large retroperitoneal teratoma involving adrenal gland with persistent hypocortisolism..

256

"Indications and interpretation of Thyroid function tests in Acute Medical Inpatients"

Balvinder BK Kalra¹, Ghazaleh GA Ahmadi¹, Vikas VW Wadhwa¹, Chris CG Gilfillan¹

1. Eastern Health, Box Hill, VIC, Australia

Background

Screening inpatients for abnormal thyroid function is not recommended unless thyroid disease is suspected since changes in thyroid hormones, binding proteins, and TSH concentrations occur in severe non-thyroidal illness (NTI).

Objectives-

1. To determine the indications for and interpretation of TFTs by junior medical staff
2. To estimate the cost burden on the health care system due to inappropriate requests to perform TFT's in acute medical inpatients.

Methods-

1- Reviewing patient database (CPF from 01st February 2012 to 30th March 2012) at Maroondah Hospital for TFTs ordered at admission and Indications for, interpretation of, and costs of TFTs in these patients.

2- A questionnaire regarding knowledge of interpretation of TFTs amongst the Junior Medical staff was administered and analysed

Results-

804 patients were admitted under the Medical unit at Maroondah Hospital between February 2012 and March 2012, a total of 208 patients (25.87%) had TFT's performed. Out of which 123 (59%) patients were judged to have an acceptable indication for performing TFT's. The most common indication was delirium, followed by tachycardia and exacerbation of congestive cardiac failure. 33 (16%) patients were found to have thyroid dysfunction and only 17 (8%) patients had a clinically significant thyroid disease. The most common thyroid disease was subclinical hypothyroidism (9/17 = 52.9%), followed by subclinical hyperthyroidism (6/17 = 35.29%).

Approximately 72% (36/50) junior doctors scored 50% or more in the questionnaire related to Thyroid and Non-Thyroid illness.

Conclusion-

Thyroid function should not be done frequently in acute medical inpatients, unless there are clear indications. TSH should be the initial screening test as adding on FT4 or FT3 initially could lead to unnecessary expense for the health system.

257

For a modern Sherlock: The mysterious case of disappearing diabetes insipidus

Dev A Kevat¹, Kelly W Carruthers¹, Moe Thuzar¹, Michael C D'Emden¹, Emma L Duncan

1. Royal Brisbane, Herston, QLD, Australia

We present an unusual case of panhypopituitarism with diabetes insipidus (DI), with diagnostic dilemma despite extensive investigations, and subsequent spontaneous resolution of DI.

A 55-year-old man presented with an abrupt onset of DI (urine output >6L/day, serum sodium 142mmol/L, osmolality 311mOsm, paired urine osmolality 245mmol/L. His GP started DDAVP with dramatic relief. He reported a painless non-dermatomal blistering rash resolving spontaneously after 2 weeks, weight loss (5kg), myalgias and headache but no arthralgias. He was pale, overweight, with good testicular volumes. Biochemically he had profound panhypopituitarism and was started on hydrocortisone and thyroxine with later testosterone replacement. MRI showed a small pituitary gland without posterior bright spot, normal stalk and no intra- or suprasellar lesions but did demonstrate a small frontal lobe lesion with possible ring enhancement. Serum calcium, CSF examination; CT chest/abdomen/pelvis were normal with a negative infectious disease and autoimmune screen. One of three serum ACE was elevated 93U/L (normal<51), though thought insignificant by the respiratory team

Followup MRI (3/12 later) showed a doubling in size of the frontal lesion, with a differential diagnosis of glioblastoma multiforme, lymphoma, and inflammation. Neurosurgical review resulted in commencement of dexamethasone and prompt resection. A firm histopathological diagnosis proved elusive. Histology showed parenchymal necrosis with perivascular, EBV-negative T-lymphocytic infiltrate with monoclonal rearrangement of TCR genes suspicious for peripheral T-cell lymphoma. Despite the clonality, the pattern of infiltration was highly unusual for lymphoma.

High dose steroids were weaned rapidly to physiological replacement. The patient stopped DDAVP without medical supervision. Remarkably, there was no recurrence of polyuria and biochemistry remained normal. Anterior pituitary dysfunction persisted. Sinus node dysfunction was diagnosed after a collapse. A pacemaker was inserted; no evidence of infiltrative disorder was found on cardiac MRI. Indeed, two years later, there has been no definitive evidence of sarcoid, lymphoma or vasculitis.

258

The study of the long term effect on glucose metabolism in patients with acromegaly receiving SSA versus patients not treated with SSA

Ni Ni Khin¹, Ann McCormack²

1. Endocrinology Advanced Trainee, Caboolture Hospital, Caboolture, QLD, Australia

2. Endocrinologist, St Vincent Hospital and Garvan Institute of Medical Research, Sydney, NSW, Australia

Background: Acromegaly may result in impaired glucose metabolism. Somatostatin analogues (SSA) may themselves impair glucose metabolism by inhibiting insulin secretion. The long term impact on glucose status in patients with acromegaly treated with SSA remains unclear.

Objectives: To study the long term effect on glucose metabolism in patients with acromegaly receiving SSA versus not treated with SSA.

Methods: Retrospective chart review of 22 patients with acromegaly treated for >5 years. Patients were divided into 4 groups. Group 1: 4 patients on primary medical therapy with SSA and biochemical control. Group 2: 6 patients who had primary surgery with achievement of biochemical control. Group 3: 6 patients who had primary surgery and postoperative SSA with subsequent biochemical control. Group 4: 6 patients who had primary surgery followed by SSA and have not achieved biochemical control.

Results: The Median age of patients was 55 (30-78)yrs. Mean BMIs in group 1, 2, 3 and 4 were 25, 30, 28 and 33 respectively. All patients had follow up of at least 8 years. A deterioration in glucose metabolism was seen in group 1 (3 of 4 patients), group 3 and group 4 (each 2 of 6 patients). No patient undergoing primary surgical treatment developed impaired glucose metabolism after long term follow-up. In group 1, one patient had baseline impaired fasting glucose and by 9 years was on Metformin. In group 3, baseline fasting glucose in one patient was 6.2mmol/L rising to 7.4mmol/L by 5-6 years of SSA despite weight loss. One patient in group 3 and two in group 4 had baseline diabetes and were on insulin therapy after SSA at the end of 8-9 years follow-up.

Conclusion: SSA treatment, either as primary medical treatment or after surgery regardless of biochemical control or weight, may be associated with a longer term deterioration in glucose metabolism compared with primary surgical management.

Pituitary Apoplexy secondary to Pituitary Haemorrhage related to Rivaroxaban use

Thinn Thinn TK Khine¹, Duncan DJ Topliss²

1. Alfred Health, Melbourne, VIC, Australia

2. Department of Endocrinology and Diabetes, The Alfred, Melbourne, Victoria, Australia

An 84 year old man presented to the Emergency Department with acute onset of frontal headache, nausea, and vomiting for 2 days. He had a 10 day history of unprovoked isolated left medial gastrocnemius vein thrombosis, diagnosed by Doppler ultrasound. He had been treated by his GP with oral rivaroxaban, 15mg BD, for the past 7 days.

He had a history of pituitary macroadenoma (18 mm x 24 mm x 19 mm) found incidentally with CT and subsequently confirmed by MRI. His pituitary hormonal profile was normal and he was managed conservatively.

Additional past medical history includes; hypercholesterolaemia, treated with atorvastatin 20mg daily, and hiatus hernia, treated with pantoprazole 40mg daily.

A CT Brain in the Emergency Dept showed acute haemorrhage into the pituitary macroadenoma; A subsequent MRI showed intrinsic high T1 signal in the enlarged pituitary mass in keeping with acute haemorrhage.

Rivaroxaban was ceased, and a Doppler ultrasound was repeated which showed no ongoing features of deep vein thrombosis. His hormonal profile indicated panhypopituitarism, with very low random cortisol, borderline low FT4 without TSH elevation, and very low testosterone with low LH.

Hormonal replacement therapy with IV hydrocortisone 100 mg QID was initiated, followed by oral cortisone acetate 25 mg bd.

The patient gradually exhibited neurological symptoms with reduced peripheral vision in the next 2 days, in spite of discontinuation of anticoagulation.

He underwent transphenoidal pituitary tumour resection with no significant postoperative complications.

The histological findings were of a necrotic and infarcted pituitary adenoma.

He has since been maintained on hormone replacement therapy (cortisone acetate, thyroxine, desmopressin. He is well and continues in endocrine and neurosurgical follow up.

RECOMMENDATIONS

1. Prompt recognition and management of pituitary apoplexy is essential.

2. We need to assess each case of thrombosis for risk and benefit of anticoagulation particularly in treatment of elderly patients with underlying co-morbidities.

Unusual presentation of hyponatremia

Thinn Thinn TK Khine^{1,2}, Sennye SM Mogale¹, Catriona CM McLean², Daniel DF Fineberg^{1,2}

1. Cabrini Health, Melbourne, VIC, Australia

2. Alfred Health, Melbourne, VIC, Australia

A 73-year-old independent lady presented with hyponatremia (Serum Na⁺ - 119mmol/L). She has several weeks of feeling unwell and difficulty concentrating. Her medications included Paroxetine and Irbesartan which were both withheld from admission.

The symptoms were consistent with SIADH. The workup for causes of hyponatraemia showed no underlying problem with thyroid function or hypoadrenalism.

Initial investigations included Xray and CT chest which showed small nonspecific granulomas and an initial MRI brain showed features of small vessel disease.

Her Na⁺ level slowly corrected with fluid restriction of 135mmol/L over 3 weeks. Afterwards, she complained of visual disturbances followed by non-specific episodes of syncope.

There were no abnormality identified in ophthalmic review. Her decreased conscious state did not appear to be consistent with any epileptic phenomenon or cardiac causes. MRI brain and EEG were unremarkable.

The possibility of an underlying psychiatric issue was explored and was Mirtazepine 15mg daily was trialed. Her conscious state deteriorated and a repeat MRI and EEG showed significant changes consistent with hypothalamic encephalitis.

CT Chest and Abdomen showed the same small granulomatous lung lesions and an enlarged paracolic lymph node(1.3 cm).

Lumbar puncture - an elevated protein level and a neuronal western blot revealed a positive PNMA2, suggestive of limbic encephalitis.

A few doses of IVIG were given, however, she continued to deteriorate and passed away in a few days.

Post mortem - Paraneoplastic encephalitis involving hypothalamus, midbrain, pons and part of thalamus.

Discussion

This case was an unusual presentation of euvoelaemic hyposmolar hyponatraemia with the initial presentation not revealing organic pathology on clinical examination or imaging.

A psychiatric or behavioural change in the context of hyponatraemia should alert the clinician to a potential encephalopathic process.

This is one of the only reports in the literature with histopathological confirmation of the targeted hypothalamic structures associated with the CSF protein abnormality.

261

Clinical aspects and mortality rate of pediatric diabetic ketoacidosis

Min Sun Kim¹, Dae Gyu Lee², Sun-Young Kim¹, Dae-Yeol Lee¹

1. Pediatrics, Chonbuk National University Medical School, Jeonju-si

2. HanBit Ophthalmology clinic, Jeonju-si

Background: Diabetic ketoacidosis (DKA) is a very serious, acute pediatric type 1 diabetes (T1DM) complication. This study aimed to determine the risk factors and clinical aspects of DKA. Methods: Children hospitalized for DKA from January 2000 to December 2012 were included. Cases were classified as mild, moderate, or severe according to the clinical and laboratory results collected during that time period. Statistical significance was defined as $P < 0.05$. Results: Fifty-nine DKA cases ($pH \leq 7.3$) were confirmed among 43 patients. The average age was 11.98 ± 4.40 years (range, 1.3–19.9 years). Thirty-one patients had previously experienced DKA. DKA was most frequent in moderate cases (21 cases, 35.6%), followed by severe (19 cases, 32.2%) and mild cases (19 cases, 32.2%). Clinical manifestation did not differ; however, severe cases exhibited more aggravated metabolism (e.g., hyperglycemia, elevated corrected serum Na and effective serum osmolality). Female patients were more frequently severe and moderate ($P = 0.041$). HbA1c levels did not differ between initial and recurrent cases. Two female patients (11.2 and 13.4 years) died with symptoms of brain edema. The mortality rate was 3.39% (2/59). Only the blood sugar level differed significantly between surviving and non-surviving cases ($P = 0.022$). Conclusion: In this study, no statistically significant differences were identified besides blood sugar levels. However, female patients should be carefully diagnosed and treated. Proper blood sugar level maintenance and continuous education are needed, particularly in summer, even among previously diagnosed and insulin-treated T1DM patients.

262

Auricular Calcification: an unusual clue to an important endocrine disorder

Tien Lee¹, Anthony Zimmermann¹

1. Department of Endocrinology, Lyell McEwin Hospital, Elizabeth Vale, SA, Australia

Abstract

Calcification of the auricles that presents clinically with stiffened ears and moves as a single unit is rare¹. It has been reported in patients with frostbite or trauma², but has also been described in important endocrinopathies such as Addison's disease or hypopituitarism^{2,3,4}. It could be the only important clue to the underlying endocrinopathy, which if missed, may have a fatal outcome.⁵ As a rare sign, it is often missed. In literature, it is generally discovered only when the patient presents acutely unwell with symptoms suggestive of adrenal insufficiency.

We report a unique case of hypopituitarism that was undiagnosed for over 30 years despite significant morbidity, in which investigations that resulted in the diagnosis were ordered following discovery of auricular calcification. This occurred in a 61 year old man who had to resign from work due to severe fatigue, presyncope and confusion. His hypopituitarism was only discovered recently after complaining about his stiffened outer ear. Clinically, he responded well to hormonal therapy for his central hypothyroidism, hypogonadotrophic hypogonadism, and secondary adrenal insufficiency.

We will discuss the case history and provide a brief literature review.

1. Mastronikolis NS, Zampakis P, Kalogeropoulou C, et al. Bilateral ossification of the auricles: an unusual entity and review of the literature. *Head & face medicine* 2009;5:17.
2. Gordon DL. Calcification of Auricular Cartilage. *Archives of Internal Medicine* 1964;113:23.
3. Randall RE, Spong FW. Calcification of the auricular cartilage in a patient with hypopituitarism. *The New England journal of medicine* 1963;269:1135–7.
4. Barkan a, Glantz I. Calcification of auricular cartilages in patients with hypopituitarism. *The Journal of clinical endocrinology and metabolism* 1982;55:354–7
5. Gogate Y, Gangadhar P, Walia RR, Banshali A. "Petrified ears" with idiopathic adult-onset pituitary insufficiency. *Indian journal of endocrinology and metabolism*. 2012 Sep;16(5):830-2.

263

Sleep disturbance in pregnant women with and without Gestational Diabetes Mellitus

Jaime Lin¹, Annette Robertson^{1,2}, Sue Lynn Lau¹, Colin Sullivan³, Mark McLean¹, Annemarie Hennessy^{1,2}

1. University of Western Sydney, School of Medicine, NSW, Australia

2. Campbelltown Hospital, Campbelltown, NSW, Australia

3. University of Sydney, Sydney, NSW, Australia

Introduction: Studies demonstrate a link between sleep disorder and diabetes risk. Whether sleep deprivation, or sleep-disordered breathing, contribute to pathogenesis or severity of gestational diabetes (GDM) remains unknown.

Methods: 2309 pregnant women recruited from antenatal clinics were administered the Epworth Sleepiness Scale and Berlin Questionnaire. Anthropometry was performed and self-reported pre-pregnancy weight recorded. 'SonoMat' home sleep tests

were conducted in 202 women. From this larger cohort, 150 women with GDM and 150 non-GDM controls were selected, matched for age and pre-pregnancy BMI. Diabetes status was confirmed on glucose tolerance test results, using ADIPS criteria. Sleep questionnaire results were compared between GDM and control groups. Within the GDM group, glucose levels were compared between those with 'high risk' and 'low risk' sleep questionnaire scores.

Results: Mean age (31yrs both groups) and prepregnancy BMI (30.8 both groups) confirmed successfully matching of GDM and controls. 3% of GDM were classified high risk, and 20% moderate risk according to the Epworth scale, not significantly different from the control group (4% high risk, 22% moderate risk). 68% of GDM were classified 'high risk' on Berlin Questionnaire, compared to 63% of normal controls ($p=ns$). In GDM, mean fasting glucose did not differ between the high or low risk Berlin Questionnaire groups (5.3 vs 5.5mmol/L, $p=0.2$). No differences in fasting/2hr glucose were found between Epworth Scale risk groups. Preliminary analysis of 'SonoMat' studies in 14 GDMs and 12 controls found a trend to higher apnoea: hypopnoea index and significantly more snoring in GDM women; further analysis is planned.

Conclusions: In groups matched for pre-pregnancy BMI, sleep questionnaire results did not differ according to glucose tolerance. Sleep disorder, independent of BMI, may not contribute significantly to GDM pathogenesis or severity. Alternatively, sleep questionnaires may be a poor method of assessing sleep disorders in pregnancy. Further SonoMat studies will be analysed.

Cryptic pulmonary lesions in ectopic ACTH syndrome

M Ling¹, A Lih¹, F Marroquin-Harris², B Champion¹

1. Department of Endocrinology, Nepean Hospital, Kingswood, NSW 2747

2. Northern Clinical School, University of Sydney, Sydney, NSW 2000

Case1. A 63-year-old woman with resistant hypertension and osteoporotic crush fractures was confirmed to have marked hypercortisolism with raised ACTH(31.3pmol/L). Repeated high-dose dexamethasone suppression tests failed to suppress cortisol. Brain MRI was inconclusive reporting possible pituitary microadenoma.

IPSS with CRH stimulation localised a central source of ACTH production to the Left(Figure1). Despite two transphenoidal hypophysectomy on two occasions she had persistent postoperative hypercortisolaemia unresponsive to ketoconazole therapy. Histopathology showed normal pituitary tissue(Figure2-A) with an incidental finding of a sphenoid mycetoma with aspergillus species.

Subsequently she was discovered to have bilateral pulmonary lesions and possible liver lesions on CT/MRI. FDG-PET and Ga68-Octreotide-PET were performed: both upper lobe lung lesions demonstrated FDG-avidity but no uptake on the Ga⁶⁸-Octreotide scan(Figure3-A/B/C). She underwent pulmonary core biopsy twice(initial biopsy non-diagnostic) with normal/non-malignant histopathology(Figure2-B). Repeat lung biopsy and bronchoscopic lavage culture both yielded *Nocardia asteroides*, for which she was successfully treated with Bactrim(sulfamethoxazole-trimethoprim).

Due to persistent symptomatic hypercortisolaemia unresponsive to adrenal blockade with high-dose ketoconazole, the patient underwent emergency bilateral adrenalectomy with successful recovery.

Figure1

ACTH	Peripheral (pmol/L)	RIGHT IPS (pmol/L)	RIGHT ACTH Ratio Central:Peripheral	LEFT IPS (pmol/L)	LEFT ACTH Ratio Central:Peripheral	SVC (pmol/L)	IVC (pmol/L)
Baseline	14	14	1.00	16	1.14		
TIME 0	14	15	1.07	19	1.36		
TIME 2 mins	13	14	1.08	30	2.31		
TIME 5 mins	12	14	1.17	48	4.00		
TIME 10 mins	14	16	1.14	59	4.21		
TIME end						16	13
Prolactin	Peripheral (mIU/L)	RIGHT IPS (mIU/L)	RIGHT PROLACTIN Ratio Central:Peripheral	LEFT IPS (mIU/L)	LEFT PROLACTIN Ratio Central:Peripheral	SVC	IVC
Baseline	537	503	0.94	2499	4.65		
TIME 0	541	485	0.90	2038	3.77		
TIME 2 mins	496	447	0.90	1982	4.00		
TIME 5 mins	489	462	0.94	2284	4.67		
TIME 10 mins	456	450	0.99	2829	6.20		
TIME end						519	444

Figure2-A/B

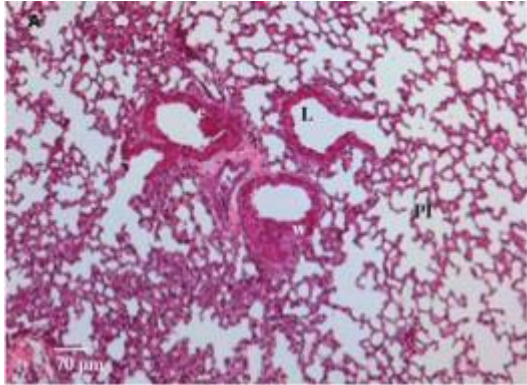
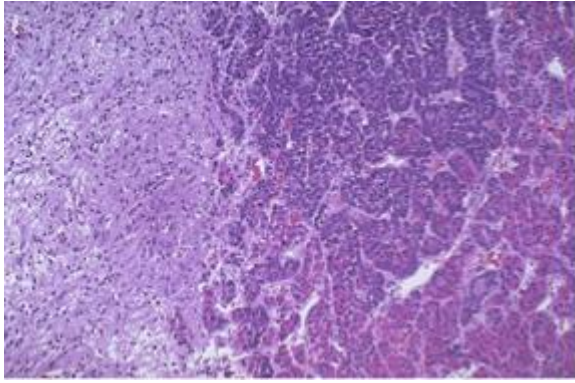
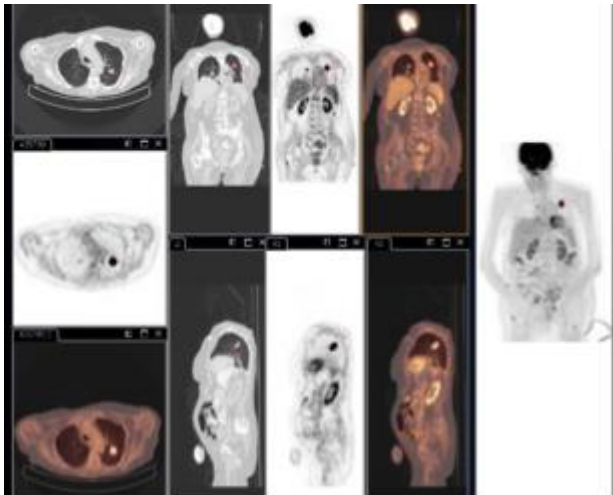
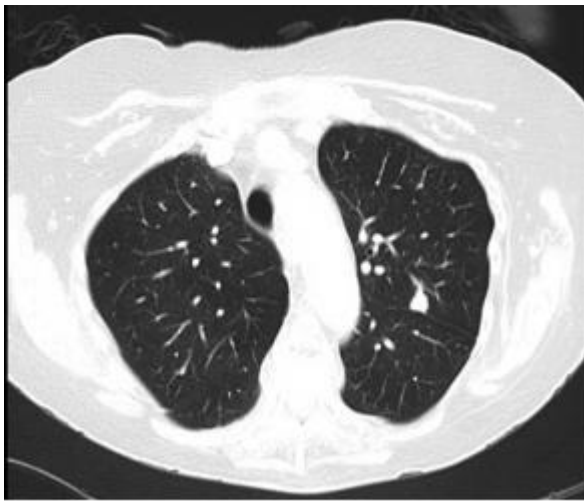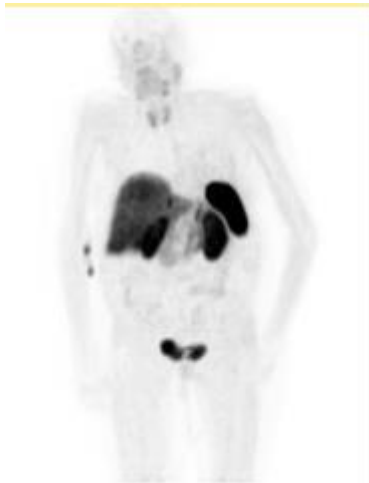


Figure3-A/B/C





Case2. A 64-year-old Caucasian male presented with erratic glycemic control with recurrent psychosis, hypokalemia, hypertension and lymphopenia. Further investigations detected cavitating lung and multiple liver lesions. PET scan showed FDG uptake in the above lesions and also in the head of pancreas and pylorus. He underwent fine needle aspiration of the lung lesion and *Nocardia asteroides* were found.

Core biopsy of the liver lesion revealed intermediate-grade neuroendocrine tumour with ACTH-positive stain. The 24-hour urine cortisol excretion was elevated, so was serum ACTH(86.1pmol/L). He was started on ketoconazole/metyrapone and palliative chemotherapy.

Discussion: These two cases illustrate complex presentation of ectopic ACTH syndrome with a series of diagnostic and management challenges, including severe immunosuppressive complications. We will present literature review on data of relevant results, investigational modality and currently available therapy.

1. Salgado LR, Fragoso MCBV, Knoepfelmacher M, Machado MC, Domenice S, Pereira MAA and de Mendonca BB. Ectopic ACTH syndrome: our experience with 25 cases. *European Journal of Endocrinology* 2006; 155: 725–33.
2. Stewart PM, Walker BR, Holder G, O'Halloran D and Shackleton CH. 11 beta-Hydroxysteroid dehydrogenase activity in Cushing's syndrome: explaining the mineralocorticoid excess state of the ectopic adrenocorticotropin syndrome. *Journal of Clinical Endocrinology and Metabolism* 1995; 80: 3617–20.
3. Isidori AM, Kaltsas GA, Pozza C, Frajese V, Newell-Price J, Reznick RH, Jenkins PJ, Monson JP, Grossman AB and Besser GM. The Ectopic Adrenocorticotropin Syndrome: Clinical Features, Diagnosis, Management, and Long-Term Follow-Up. *Journal of Clinical Endocrinology and Metabolism* 2006; 91: 371–7.
4. Natale R, Yagoda A, Brown A, Singer C, Stover D and Bajorunas D. Combined *Pneumocystis Carinii* and *Nocardia asteroides* pneumonia in a patient with an ACTH-producing carcinoid. *Cancer* 1981; 47: 2933-5.
5. Graham BS and Tucker WS Jr. Opportunistic Infections in Endogenous Cushing's Syndrome. *Annals of Internal Medicine*. 1984; 101: 334-8.
6. Beinart GA, Rao RK and Hollander H. Ectopic ACTH Syndrome Resulting in Nocardiosis and Acute Respiratory Failure. *Hospital Physician* 2003; 39 (10): 49-51.
7. Sutton BJ, Parks GE, Manavi CK, Palavecino EL and Geisinger KR. Cushing's Syndrome and Nocardiosis Associated With a Pulmonary Carcinoid Tumor: Report of a Case and Review of the Literature. *Diagnostic Cytopathology* 2011; 39 (5): 359–62.
8. Lindsay JR and Nieman LK. Differential diagnosis and imaging in Cushing's syndrome. *Endocrinology and Metabolism Clinics of North America* 2005; 34: 403–21.
9. Wind JJ, Lonser RR, Nieman LK, DeVroom HL, Chang R and Oldfield EH. The Lateralization Accuracy of Inferior Petrosal Sinus Sampling in 501 Patients With Cushing's Disease. *Journal of Clinical Endocrinology and Metabolism* 2013; 98 (6): 2285-93.
10. Ritzel K, Beuschlein F, Mickisch A, Osswald A, Schneider HJ, Schopohl J and Reincke M. Outcome of Bilateral Adrenalectomy in Cushing's Syndrome: A Systematic Review. *Journal of Clinical Endocrinology and Metabolism* 2013, 98 (10): 3939–48.

Severe hypoglycaemia, hypercalcaemia and thyrotoxicosis in a patient three months postpartum

Rakesh Mallikarjunan^{1,2}, **Aaron Simpson**³, **Christopher Nolan**^{1,2}

1. Canberra Hospital, Phillip, ACT, Australia

2. Australian National University, Canberra, ACT, Australia

3. Endocrinology, Sir Charles Gairdner hospital, Perth, Western Australia, Australia

A 35 year old, previously well caucasian woman presented with an episode of loss of consciousness, 3 months after the delivery of her first child. The post partum period was complicated by significant post partum haemorrhage. Initial investigations showed blood glucose 1.8mmol/L (3.5-5.5), corrected calcium 3.66mmol/L (2.10-2.55) and a suppressed TSH <0.03mIU/L (0.4-4.0) with an elevated freeT4 44.8pmol/L (9.0-20.0) indicating severe hypoglycaemia, hypercalcaemia and thyrotoxicosis. She responded rapidly to intravenous fluids, glucocorticoids, zoledronic acid and anti thyroidal medication. Thyroid scintigraphy was consistent with thyroiditis. Baseline cortisol and ACTH were undetectable indicating secondary adrenocortical deficiency.

An insulin tolerance test demonstrated lack of ACTH and cortisol response with an appropriate GH response indicating isolated ACTH deficiency (IAD). MRI pituitary did not show features of Sheehan's syndrome. On long term follow up, isolated ACTH deficiency was noted to be the only endocrine abnormality until she developed Graves' disease four years later. Although hypercalcaemia in association with Addison's disease aggravated by concomitant thyrotoxicosis has been described, IAD presenting with hypercalcaemia is a unique feature. The patient's development of Graves' disease on follow up indicates underlying autoimmune pathophysiology increasing the likelihood that her IAD was a consequence of postpartum autoimmune hypophysitis. The role of postpartum haemorrhage in development of IAD in our patient is uncertain.

Marked hypercalcaemia, hypercalcuria and two parathyroid adenomas in a patient with Familial Hypocalcuric Hypercalcaemia

Rakesh Mallikarjunan¹, Roderick Clifton-Bligh², Leigh Delbridge³, James Dennis Wilson¹

1. Canberra Hospital, Phillip, ACT, Australia

2. Endocrinology, Royal North shore hospital, Sydney, NSW, Australia

3. Endocrine Surgery, Royal north shore hospital, Sydney, NSW, Australia

A 46-year-old lady presented with left groin pain and was found to be hypercalcaemic. She admitted to lethargy and polydipsia but denied bone pain, depression, previous fractures or renal calculi. She denied thiazide or lithium use. There was a family history of primary hyperparathyroidism. Her paternal aunt remained persistently hypercalcaemic despite removal of a parathyroid adenoma. Subsequent selective venous sampling raised the possibility of an ectopic parathyroid gland. CASR gene mutation was negative. The patient's father was also persistently hypercalcaemic despite subtotal parathyroidectomy. His parathyroid histopathology was consistent with hyperplasia.

At presentation she was adequately hydrated; neck and systemic examination were unremarkable. Corrected calcium was 3.30 mmol/L (2.15-2.55) and PTH 11.7 pmol/L (1.6-6.8). 24-hour urine calcium excretion was 9.3mmol/day (2.5-7.5), Urine calcium creatinine ratio was 0.018 (>0.01) indicating hypercalcuria. Renal function and hormonal investigations were normal. Bone mineral density and renal tract ultrasound were normal. Right inferior parathyroid adenoma was identified on ultrasound and sestamibi scans. Since the presentation was consistent with primary hyperparathyroidism she was referred for parathyroidectomy. Three enlarged parathyroid glands were removed during neck exploration. Histopathology revealed two adenomas and a normal parathyroid gland. Postoperatively, PTH levels normalized; calcium levels decreased to 2.78 mmol/L. A repeat sestamibi scan was normal. Due to persistent hypercalcaemia she was referred for CASR gene testing. Meanwhile, her father and aunt were reported positive for a new heterozygous R172T point mutation in CASR. Subsequently, this mutation was found in our patient. This indicates dual pathology namely Familial Hypocalcuric Hypercalcaemia (FHH) and Primary Hyperparathyroidism (PHPT).

Coexistence of FHH and PHPT is rare. It remains uncertain if CASR mutation plays a pathophysiological role in development of adenoma in FHH. It is important to identify this coexistence because removal of the adenoma can result in decrease in calcium levels to those characteristic of FHH.

Acromegaly in a patient with Primary Polycythaemia: A case report

Rakesh Mallikarjunan¹, Sally Newsome¹

1. Canberra Hospital, Phillip, ACT, Australia

A 66-year-old man with recent diagnosis of Primary Polycythaemia was referred for management of Pituitary macroadenoma, identified on a pituitary MRI performed for frequent dizzy spells. It showed a 2.4cm sellar mass compressing and elevating the optic chiasm. On further questioning, he reported increase in ring and shoe size, arthritis affecting his hands, elbows and knees and symptoms of obstructive sleep apnoea. Physical examination findings consistent with acromegaly such as spade like hands, wide feet, increased interdental separation were present. There was bilateral gynaecomastia. His blood pressure was 150/95 mm of Hg. A formal visual field assessment showed early bitemporal hemianopia. Further investigations revealed an elevated IGF 1 level of 53nmol/L (8-42), but GH didn't fall below 1 ng/ml during an oral Glucose tolerant test. Prolactin level was mildly elevated at 1030mIU/L and testosterone was low normal at 10nmol/L. Rest of the pituitary profile was normal.

He was diagnosed with GH secreting pituitary tumour and underwent transphenoidal resection of the pituitary tumour. Unfortunately, his postoperative period was complicated by epistaxis and respiratory arrest requiring mechanical ventilation. Post operatively, polycythaemia resolved, GH levels became undetectable, IGF 1 levels normalised. Pituitary MRI didn't show a residual tumour. His recovery was complicated with panhypopituitarism.

Discordant IGF 1 and GH values have been reported in acromegaly. Importance of this phenomenon is uncertain, but it can pose significant dilemmas during management. Secondary polycythaemia can occur in acromegaly due to excessive chronic stimulation of JAK2/STAT pathway leading to proliferation of myeloid progenitor cells but co-occurrence of acromegaly and primary polycythaemia is an extremely rare event, with only one case report published to date. Another report suggested increased prevalence of myeloproliferative neoplasms in acromegalic patients. The role of JAK2 mutation in development of acromegaly remains to be determined in these patients.

Calcimystery in HIV

Emma Scott¹, Mani Manoharan¹, Kris Park¹

1. Nepean Hospital, Penrith, NSW, Australia

A 52-year-old Caucasian man with insidious onset dyspnoea, productive cough, lethargy, anorexia and weight loss presented to ED. On examination, he was febrile, dehydrated and cachectic. He was in hypoxic respiratory failure and required intubation. Chest X ray showed bilateral ground glass opacities which was confirmed on CT scan and *Pneumocystis jirovecii* infection was yielded from bronchoalveolar lavage. HIV infection was confirmed with viral load of 163000 viral copies/ml and initial CD4 count was 2uL (380-1390).

Marked hypercalcaemia was noted; corrected serum calcium was 3.22mmol/l (2.20-2.52). Initial iPTH was 1.7pmol/l (1.1-6.8) but subsequently iPTH was suppressed 0.3pmol/l as expected. The S.25OH Vit D was 96pmol/l and 146pmol/l on 2 different occasions. His 1, 25 (OH) 2Vit D was high 183 pmol/L (ranges 60 to 158). PTH-rP was normal. Fractional calcium excretion was >0.01. His ACE level, thyroid function and serum cortisol level was normal. Solid organ malignancy and haematological malignancies were excluded. Serology and cultures for viral, bacterial, fungal, mycobacterial and parasitic infections yielded negative results.

Patient was treated with Trimethoprim/Sulfamethoxazole and prednisone for 21 days for *Pneumocystis pneumonia*. Antiretroviral therapy (Truvada and Raltegravir) was commenced resulting in improvement in CD 4 counts and reduction in viral load. Hypercalcaemia rapidly decreased with intravenous fluids. One month later calcium remained elevated 2.77mmol/l, 25(OH) Vit 108nmol/l and 1, 25 (OH) 2Vit D 160pmol/l.

In summary 51 yr old man who presented with *Pneumocystis pneumonia* and hypercalcaemia in the context of newly diagnosed HIV. There are many well recognised causes of hypercalcaemia in HIV, both endocrine and non-endocrine related. In our patient hypercalcaemia was initially attributed to *Pneumocystis jirovecii* infection. However hypercalcaemia did not resolve following adequate treatment which raises the possibility of other mechanisms in this patient.

This case highlights effects of HIV infection¹; HIV related opportunistic infection² as well as antiviral therapy on Vitamin D metabolism^{3,4}.

1. Garcia et al. Abnormalities in the bone mineral metabolism in HIV-infected patients. *Clinical Rheumatology*. 2006;25: 537-39.
2. Dusso et al. A Mechanism for the hypercalcemia of various Granulomatoses. *JCEM*;1997;82 2222-32
3. Gutierrez et al. The role of HIV and antiretroviral therapy in bone disease. *AIDS Rev* 2011;13; 109-18.

Two cases of congenital hypogonadotropic hypogonadism: similar but different

Natalie Marijanovic¹, Jui Ho¹

1. Flinders Medical Centre, Bedford Park, SA, Australia

We present two cases of Congenital Hypogonadotropic Hypogonadism (CHH) who both presented with absence of menses by the age of 16. On specific questioning, Case 1 reported anosmia.

On examination, Case 1 was of normal weight and height. She had Tanner stage 4 development of secondary sexual characteristics, microdontia of the incisor teeth and brachydactyly of the hands and feet. Case 2 was overweight (BMI 26 kg/m²) and had underdeveloped, rudimentary breasts (Tanner stage 2), sparse pubic hair (Tanner stage 1), and absent axillary hair. Case 2 also had acanthosis nigricans.

Investigations of both cases showed hypogonadotropic hypogonadism with no other pituitary hormone abnormalities. Further, there was no evidence of calcium homeostasis abnormalities. The karyotype of both cases was 46, XX. Insulin resistance was confirmed for Case 2 (HbA1c 6.0 %).

Pelvic ultrasound of both cases identified a prepubertal-sized small uterus and small ovaries, but no urogenital tract anomalies. Pituitary MRI was normal in both cases. Plain radiographs of the hands and feet of Case 1 showed bilaterally short fourth metacarpals with Madelung deformities of the wrists and bilaterally short metacarpal bones, respectively.

Discussion

CHH is rare and is usually due to an isolated deficiency or lack of efficacy of gonadotropin-releasing hormone (1). The prototype of CHH, where there is associated anosmia/hyposmia, is termed Kallmann Syndrome. In females, CHH presents with delayed or absent puberty with primary amenorrhoea. The main differential diagnosis of CHH is constitutional delay of puberty. Our cases highlight the variable phenotype of CHH. This variability can be attributed to the over twenty genes in which defects have been identified in patients with CHH and the complex heritability of these genes (2). These genes are also associated with other features such as bony and dental anomalies and renal agenesis. The identification of these genes in individuals has reproductive implications.

1. Seminara et al. Gonadotropin-releasing hormone deficiency in the human (idiopathic hypogonadotropic hypogonadism and Kallmann's syndrome): pathophysiological and genetic considerations. *Endocr Rev*, 1998; 19.
2. Miraoui et al. Mutations in FGF17, IL17RD, DUSP6, SPRY4, and FLRT3 are identified in individuals with congenital hypogonadotropic hypogonadism. *Am J Hum Genet*, 2013; 92.

Camurati-Engelmann disease: bones gone wild.

Shannon McCarthy¹

1. Barwon Health, Geelong, VIC, Australia

Camurati-Engelmann disease is a rare autosomal dominant metabolic bone disorder. We report the case of a 34-year-old woman diagnosed at age 16. She initially presented with chronic lower limb pain, and lethargy. There was no family history of any bone disease. She demonstrated bony enlargement and warmth of both femora and tibiae, muscle wasting and decreased subcutaneous fat of all limbs, and her body mass index was less than 14. A nuclear medicine bone scan demonstrated markedly increased uptake in the diaphyseal regions of the humeri, femora, and proximal tibiae bilaterally, and the skull base. Plain X-rays demonstrated patchy cortical thickening and sclerosis of both femora, humeri, radii, ulnae and of the skull, with loss of corticomedullary differentiation. Total body bone mineral density was in the 125th centile matched for age, weight and ethnicity. Serum alkaline phosphatase and erythrocyte sedimentation rate were markedly elevated, as were urine hydroxyproline, pyridinoline, and deoxypyridinoline. Treatment was difficult. Repeated trials of oral alendronate caused increased pain, glucocorticoids did not improve symptoms, and non-steroidal anti-inflammatories provided some relief. She received a total of 12 intravenous pamidronate infusions between ages 18 to 20, which gave short-term symptomatic relief without significant impact on biochemical markers. She received intravenous zoledronic acid initially in 2003 with short-term symptomatic relief. Over time she developed proptosis, pseudoclubbing, and widespread small, nontender lymphadenopathy. An MRI brain at age 33 demonstrated progressive bony expansion of the skull, ongoing mass effect of the orbits, a partially empty sella, and prominent fluid in the optic nerve sheaths suggestive of intracranial hypertension. She was reviewed by a neurosurgeon, and a conservative approach was adopted given the lack of data regarding the progression of disease, the current preservation of vision, and the technical difficulty of surgery in this disorder due to the abnormal density of bone.

1. Bartuseviciene A, Samuilis A, Skukas J. Camurati-Engelmann disease: imaging, clinical features and differential diagnosis. *Skeletal Radiol* (2009) 38:1037-1043.
2. Campos-Xavier B, Saraiva JM, Savarirayan R, Verloes A, Feingold J, Faivre L, Munnich A, Le Merrer M, Cormier-Daire V. Phenotypic variability at the TGF-beta1 locus in Camurati-Engelmann disease. *Hum Genet*. 2001 Dec;109(6):653-8. Epub 2001 Nov 9.
3. Carlson ML, Beatty CW, Neff BA, Link MJ, Driscoll CL. Skull base manifestations of Camurati-Engelmann disease. *Arch Otolaryngol Head Neck Surg*. 2010 Jun;136(6):566-75.
4. Janssens K, Vanhoenacker F, Bonduelle M, Verbruggen L, Van Maldergem L, Ralston S, Guañabens N, Migone N, Wientroub S, Divizia MT, Bergmann C, Bennett C, Simsek S, Melançon S, Cundy T, Van Hul W. Camurati-Engelmann disease: review of the clinical, radiological, and molecular data of 24 families and implications for diagnosis and treatment. *Am J Med Genet A*. 2004 Sep 1;129A(3):235-47. *J Med Genet*. 2006 Jan;43(1):1-11.
5. Wallace SE, Lachman RS, Mekikian PB, Bui KK, Wilcox WR. Marked phenotypic variability in progressive diaphyseal dysplasia (Camurati-Engelmann disease): report of a four-generation pedigree, identification of a mutation in TGFβ1, and review. *Am J Med Genet A*. 2004 Sep 1;129A(3):235-47.

The safety of injectable testosterone undecanoate

Timothy L Middleton¹, Leo Turner¹, Carolyn Fennell¹, Sasa Spasevska¹, Veena Jayadev¹, Ann J Conway¹, David J Handelsman¹

1. Concord Repatriation General Hospital, Concord, NSW, Australia

Depot injectable testosterone undecanoate (TU) was introduced in the last decade but its safety experience in clinical practice is not well defined. We surveyed prospectively TU injections given in the Andrology Department, Concord Hospital over 3.5 years (3,022 injections given to 345 patients) to estimate the incidence of (a) immediate cough/syncope related to oil vehicle microembolisation, (b) self-reported post-injection hematoma in patients taking antiplatelet &/or anticoagulant drugs and (c) the prevalence of secondary polycythaemia during treatment. Immediate cough/syncope was observed after 56 injections (66% mild, 16% severe; 40% before injection completed). The incidence was 19 (95% CI 14-24) per 1000 injections with patients displaying an excess of two or more episodes per patient (vs one or none, $p < 0.001$ Poisson distribution) but the incidence rate was no different between 3 experienced nurse injectors. No post-injection hematoma was reported (upper 95% confidence limit $< 0.1\%$) including after 269 injections to patients taking antiplatelet, anticoagulant or both drugs, of whom 56 did not withhold drugs prior to TU administration (upper 95% CL 5.4%). Mean PCV during treatment ($n=345$) was 0.47 ± 0.05 (SD) (range and quartiles 0.31, 0.44, 0.47, 0.50, 0.59) with 77 (22%) > 0.50 , 39 (11%) > 0.52 and 13 (4%) > 0.54 . We conclude that while TU injection is generally safe and well tolerated, the incidence of immediate cough/syncope is 1.9% (1.4-2.4%) following injections by experienced nurses with recurrence among patients experiencing an episode more likely than by chance. Most cough/syncope was mild with nearly half occurring during slow deep im injection. Post-injection hematoma was not observed, even among men continuing to take anticoagulant &/or antiplatelet drugs. Mild polycythemia is relatively common but rarely required specific treatment other than optimising inter-injection interval.

Vitamin D is independently associated with depression and inflammation in overweight women with and without PCOS

Lisa J Moran^{1,2}, Helena Teede², Amanda Vincent²

1. University of Adelaide, North Adelaide, SA, Australia

2. Monash University, Clayton, Victoria, Australia

Context: Depression and anxiety are common in women with polycystic ovary syndrome (PCOS). An association between vitamin D deficiency and mood disorders or inflammation has been previously reported in the general population.

Objective: To investigate the association between 25 hydroxy-Vitamin D (25OHVD) status, anxiety and depression and inflammation in women with (n=50) and without (n=23) PCOS.

Design: Cross-sectional study conducted from 2008-2010 in the general community.

Participants: Overweight or obese (body mass index > 25 kg/m²) premenopausal (aged 18-45 years) women with (n=50) and without (n=23) PCOS. Participants were recruited through community advertisement.

Main outcome measures: Primary outcome measures were 25OHVD status, self-reported mood (validated Hospital Anxiety and Depression questionnaire) and inflammation (highly sensitive C-reactive protein (CRP)).

Results: Vitamin D deficiency (25OHVD < 50 nmol/L) was observed in 46% of women with PCOS and 39% of women without PCOS (p=0.311). Mean 25OHVD was not significantly different in women with and without PCOS (50.4±22.2 versus 51.6±19.0 nmol/L p=0.828). For all women combined, 25OHVD was the only significant independent predictor of depression ($\beta = -0.063 \pm 0.021$, p=0.005) and CRP ($\beta = -0.041 \pm 0.015$, p=0.010) but not anxiety.

Conclusions: Vitamin D deficiency is common in women with and without PCOS. Vitamin D is independently associated with depression and CRP in overweight and obese women with and without PCOS. Further investigation to clarify the interrelationship between vitamin D, inflammation and depression is required to identify optimal prevention and treatment strategies for psychological and metabolic dysfunction in PCOS.

Idiopathic hypogonadotrophic hypogonadism and central hypothyroidism

May Lea Ong¹, Mark Kotowicz¹, Sam Worboy¹, Shannon McCarthy¹

1. Endocrinology, Barwon Health, Geelong, VIC, Australia

A 49-year-old lady presented with a history of minimal trauma fracture of the left proximal tibia and fibula neck 7 years ago. Significantly, she had a history of secondary amenorrhoea at the age of 35. Her dietary history and exercise habits were unremarkable and her family history was non-contributory. Her comorbidities comprised of haemolytic uraemic syndrome, peptic ulcer disease, hyperlipidaemia and depression. There was no history of cranial surgery or irradiation. Her medications include alendronate, pantoprazole, venlafaxine and rosuvastatin. Examination was unremarkable with a BMI of 24.9, normal secondary sexual characteristics, no signs of hyperandrogenism or galactorrhoea. Investigations were as followed:

Tests	Result	Normal range
Oestradiol-17-B	<70 pmol/L	-
Follitropin (FSH)	5.3 IU/L	-
Lutropin (LH)	1.9 IU/L	-
Testosterone	0.7 nmol/L	0.2-1.8
TSH	0.51 mIU/L	0.3-4.0
Free T4	9.2 pmol/L	11.5-22
TG antibody	<15 IU/ml	<60
TPO antibody	38 IU/ml	<60
Cortisol	649 nmol/L	119-619
ACTH	6.2 pmol/L	<20
IGF-1	42.3 nmol/L	12.3-33
Ferritin	69 ug/L	8-252

MRI of the pituitary showed a pituitary gland of normal size and signal with no evidence of empty sella. This ruled out pituitary and hypothalamic mass, infiltrative lesions and infarction.

The disease most likely to cause acquired gonadotrophin deficiency is haemachromatosis, which can uncommonly be associated with other pituitary hormone deficiency¹. However, this is ruled out with a normal ferritin level. Hypophysitis was another consideration although the clinical/pathological features were not inconsistent. Typically, patients have radiological findings of a pituitary mass^{2,3}. Combined gonadotrophins and TSH deficiency can be due to PROP1 mutation. The age of onset of the first hormonal deficiency can vary although almost invariably, GH deficiency begins early in infancy or childhood resulting in short stature.

We present a case of adult-onset idiopathic hypogonadotrophic hypogonadism associated with central hypothyroidism. Further molecular and immunological testing will be necessary to ascertain the pathogenesis.

1. Charbonnel B, Chupin M, Le Grand A, Guillon J. Pituitary function in idiopathic haemochromatosis: hormonal study in 36 male patients. *Acta Endocrinol (Copenh)*. 1981;98(2):178.
2. Thodou E, Asa SL, Kontogeorgos G, Kovacs K, Horvath E, Ezzat S. Clinical case seminar: lymphocytic hypophysitis: clinicopathological findings. *J Clin Endocrinol Metab*. 1995;80(8):2302.
3. Cheung CC, Ezzat S, Smyth HS, Asa SL. The spectrum and significance of primary hypophysitis. *J Clin Endocrinol Metab*. 2001 Mar;86(3):1048-53.

A small cell neuro-endocrine tumour presenting with hypopituitarism and diabetes insipidus as the initial presentation of malignancy

Danae Papachristos¹, Carmela Caputo¹, Steer Christopher², Peter McNeill³, Richard MacIsaac¹, Sachithanandan Nirupa¹

1. Endocrinology, St. Vincents Hospital, Melbourne, VIC, Australia

2. Oncology, Peter MacCallum Cancer Centre, Melbourne, VIC, Australia

3. Neurosurgery, St. Vincent's Hospital, Melbourne, VIC, Australia

Metastatic disease to the pituitary and sellar region as an initial presentation of malignancy is a rare phenomenon. It accounts for approximately one-two per cent of sellar masses. The most common primary malignancies giving rise to pituitary metastases are breast and lung carcinomas. In contrast, neuroendocrine tumours are a heterogeneous group of tumours that arise from many organ systems and do not typically metastasise to the pituitary gland. We report a rare example of small-cell neuroendocrine tumour metastasising to the pituitary stalk, which presented with hypocortisolaemia, diabetes insipidus and hyperprolactinaemia. A 43-year-old woman with no prior history of malignancy presented to the emergency department with dizziness, fatigue and refractory hypotension. On further history, she reported amenorrhoea and recent weight loss. Biochemistry revealed hyperprolactinaemia (Prolactin 1943 mIU/L) and hypocortisolaemia (Cortisol 50 nmol/L). An MRI brain demonstrated marked thickening and enlargement of the pituitary infundibulum. Over the following month, the patient also developed headaches, nocturia and polydipsia. Repeat MRI showed an increase in size of the pituitary stalk, and a water deprivation test confirmed diabetes insipidus. Trans-sphenoidal resection of the pituitary lesion was performed and histopathology revealed high-grade metastatic small-cell neuroendocrine carcinoma. Post-operatively, both a CT chest/abdomen/pelvis and Positron Emission Tomography identified a lung lesion, which although not amenable to biopsy, likely represented a primary neuro-endocrine carcinoma of the lung. The patient underwent chemo-radiotherapy for the lesion, and cranial irradiation to the site of resected pituitary metastasis. Re-staging CT chest/abdomen/pelvis showed significant reduction in size of the primary lung nodule, indicating good response to chemo-radiotherapy. The patient continues to be followed up with surveillance imaging. This case illustrates the difficulties in diagnosis and management of sellar masses when the presentation is atypical and there is no previous history of malignancy.

An unusual case of hyponatraemia

Nadia Patel¹, Anders Taylor^{2,3}, Andrew Nicol⁴, Christine Rowland⁵

1. Diabetes and Endocrinology, Princess Alexandra Hospital, Brisbane, QLD, Australia

2. Cardiology, Greenslopes Private Hospital, Brisbane, QLD, Australia

3. Senior Lecturer, University of Queensland, Brisbane, QLD, Australia

4. Haematology, Greenslopes Private Hospital, Brisbane, QLD, Australia

5. Diabetes and Endocrinology, Greenslopes Private Hospital, Brisbane, QLD, Australia

Hyponatraemia is a commonly encountered electrolyte disturbance which has a variety of causes. We describe the case of an 80 year old gentleman with a history of multiple myeloma who developed hyponatraemia during an admission with congestive cardiac failure and a respiratory tract infection. His serum sodium fell from 131mmol/L to 126mmol/L within 2 days and continued to drop progressively.

Paired biochemistry, once the serum sodium fell to 117mmol/L, revealed a serum osmolality of 265mmol/kg with urine osmolality 402mmol/kg and urinary sodium <20mmol/L. Cortisol and thyroid hormone levels were normal. Given what appeared to be a mixed picture, he was managed with free water restriction plus salt tablets, which was unsuccessful. A chest x-ray revealed globular cardiomegaly and echocardiography confirmed the presence of a large pericardial effusion with increased filling pressures but no overt tamponade.

Pericardiocentesis resulted in a rise in serum sodium from 119mmol/L to 124mmol/L within 3 hours of evacuating 800mL of pericardial fluid. Continuing improvement in the serum sodium, associated with a significant diuresis, was noted over subsequent days with normalisation of serum sodium in the absence of any additional interventions.

Cardiac tamponade is a recognised cause of hyponatraemia but has been reported infrequently in the literature with only 5 published case reports between 1983 and 2012. The underlying mechanisms for this phenomenon remain unclear but are postulated to involve both antidiuretic hormone (ADH) and atrial natriuretic peptide (ANP), along with the renin-aldosterone system. These responses appear to be the result of the effects of the pericardial effusion on cardiac output and effective circulating volume, plus effects on atrial transmural pressures and wall tension.

This case will be presented along with a discussion of the available literature and the proposed hormonal mechanisms involved in the development of hyponatraemia secondary to pericardial effusions and cardiac tamponade.

1. Mouallem et al. Pericardial Tamponade-Associated Hyponatraemia. *Am J Med Sci* 2003;325(1):51-52
2. Shafique et al. Reversible Hyponatraemia Related to Pericardial Tamponade. *AJKD* 2007;50(2):336-341

3. Weekes et al. Hyponatraemia associated with cardiac tamponade and chronic fluid excess. *BMJ Case Reports* 2010; doi:10.1136/bcr.07.2009.2113
4. Groves et al. Hyponatraemia secondary to an inappropriately high release of antidiuretic hormone in cardiac tamponade. *BrHeartJ* 1990;64:206-7
5. Douglas et al. Pericardial Tamponade and the Excessive Secretion of Antidiuretic Hormone. *SouthMedJ* 1983;76(10):1327-1328
6. Chang et al. Hyponatremia in patients with symptomatic pericardial effusion. *JCMA* 2012;75:509-512
7. Mancini et al. Hormonal responses to cardiac tamponade: inhibition of release of atrial natriuretic factor despite elevation of atrial pressures. *Circulation* 1987;76(4):884-890
8. Edwards et al. Atrial stretch not pressure, is the principal determinant controlling the acute release of atrial natriuretic factor. *Circ Res.* 1988;62:191-195
9. Panayiotou et al. Atrial wall tension changes and the release of atrial natriuretic factor on relief of cardiac tamponade. *Am J Heart* 1995;129:960-7

Peptide Receptor Chemo-Radionuclide Therapy is highly effective for intractable hypoglycaemia due to metastatic insulinoma

David A Pattison^{1,2}, **Michael S Hofman**^{1,3}, **Grace Kong**¹, **Tim Akhurst**¹, **Sally Abell**^{4,5}, **Bethany Crinall**^{4,5}, **Nirupa Sachithanandan**^{2,3}, **Cherie Chiang**^{2,3}, **Rodney J Hicks**^{1,3}

1. Centre for Cancer Imaging, Peter MacCallum Cancer Centre, East Melbourne, VIC, Australia

2. Endocrinology, Peter MacCallum Cancer Centre, East Melbourne, VIC, Australia

3. Department of Medicine, University of Melbourne, Parkville, VIC, Australia

4. Diabetes & Vascular Unit, Monash Medical Centre, Clayton, VIC, Australia

5. Monash Centre for Health Research and Implementation, School of Public and Preventive Medicine, Monash University, Clayton, VIC, Australia

Background: There are limited effective treatment options for metastatic insulinoma with intractable hypoglycaemia in which the cause of death is often hypoglycaemia rather than oncologic disease burden.

Methods: A retrospective audit identified six patients (3 men, age 55–77 years) with a diagnosis of metastatic insulinoma treated with peptide receptor chemo-radionuclide therapy (PRCRT) according to defined eligibility criteria for control of hypoglycaemia between July 2004 - June 2014 at the Peter MacCallum Cancer Centre. Five patients had prior inadequate response and/or intolerance of therapies including surgical-debulking, somatostatin-analogue therapy, diazoxide, glucocorticoids, glucagon, enteral feeding and cytotoxic chemotherapy; one patient was treated at diagnosis. Of patients with available tumour histology, three were ENETs Grade 1 (Ki,67 $\leq 2\%$) and one was Grade 2 (Ki,67 20%). All patients received ¹⁷⁷Lu DOTA-octreotate (median cumulative dose 44.1 GBq) and radiosensitising 5FU chemotherapy; two patients also received either ¹¹¹In DOTA-octreotide or ⁹⁰Y DOTA-octreotate.

Results: All patients had complete resolution of hypoglycaemia after a median of 12 weeks (range 1–102 weeks) following treatment with PRCRT. Hyperglycaemic therapies were weaned and then ceased in all patients after a median of 4.5 weeks (range 1–14) and 32 weeks (range 1–128) respectively. Three patients were admitted for post-treatment flare of hypoglycaemia. Three patients had ongoing resolution of hypoglycaemia out to 35, 92 and 187 weeks follow-up. Recurrent hypoglycaemia occurred in three patients after 32, 77 and 222 weeks, and all were successfully re-treated with PRCRT. Median survival was not reached at median follow-up of 163 weeks. All patients demonstrated partial scintigraphic response to therapy and three of four patients with assessable lesions demonstrated partial response by RECIST criteria. Five patients with baseline elevated chromogranin A demonstrated a median reduction of 82% (range 51–94%) after PRCRT.

Conclusion: PRCRT is a highly effective therapy for relief of intractable hypoglycaemia in patients with metastatic insulinoma.

An unusual cause of Recurrent Fragility Fractures: 2 case studies.

Lorraine Pereira¹, **Jackie Center**^{1,2,3}, **John Eisman**^{1,2,3,4,5}

1. Endocrinology, St Vincents Hospital, Sydney

2. Garvan institute of medical research, Sydney

3. LIVEDIAB CRU, Ingham institute, UNSW, Sydney

4. UNDA, Sydney

5. SOMS, Sydney

Osteopetrosis, also known as marble bone disease, was first described by Albers-Schonberg in 1904. It is a rare group of heterogenous genetic disorders characterised by abnormal osteoclast activity and impaired bone resorption, which results in increased bone mass throughout the skeleton. Yet, despite seemingly better than normal bone density, it is associated with increased fractures and delayed healing.

We present two cases of autosomal dominant osteopetrosis (ADO), type 11. The first case is a 57-year-old-caucasian lady, who was referred for recurrent fragility fractures from the age of 12, despite robust bone density with T-scores of +3.4 SD in her lumbar spine and +2.9 SD in the right femoral neck. The second case is a 36-year-old-Asian man, similarly referred for recurrent fragility fractures, which began at the age of 13. His bone density was significantly elevated with T-scores of +7.1 SD in his lumbar spine and +13.6 SD in the right femoral neck. Interestingly, his younger brother also had a history of fractures starting from a young age with similar bone density measurements.

These two cases illustrate the genetic, clinical and radiological features of osteopetrosis. Furthermore, while there is no specific treatment for ADO except symptomatic management, we explore the role of high dose calcitriol (1,25-dihydroxyvitamin D), a known potent stimulator of osteoclast precursor proliferation and differentiation.

Hypophosphataemic osteomalacia following intravenous iron infusions.

Lorraine Pereira¹, John Eisman^{1,2,3,4,5}, Jackie Center^{6,2,3}

1. St Vincents Hospital, Glebe, NSW, Australia

2. Garvan institute of medical research, Sydney

3. LIVEDIAB CRU, Ingham institute, UNSW, Sydney

4. UNDA, Sydney

5. SOMS, Sydney

6. Endocrinology, St Vincents Hospital, Sydney

Intravenous iron preparations have improved significantly over the years. The newer second-generation formulations, such as iron sucrose and ferric gluconate, have been marketed as safe, effective agents for the management of iron deficiency. This has resulted in widespread use of iron infusions for a range of medical conditions. However, there have been an increasing number of case reports of hypophosphatemia following iron infusions. We report the case of a 46 year-old lady with long standing Crohn's disease who became iron transfusion dependent in the context of haemorrhagic ulcers and malabsorption. Subsequently she developed several episodes of hypophosphatemia with a clear temporal relationship to her iron infusions. Over time, the chronic hypophosphatemia resulted in osteomalacia with widespread insufficiency fractures involving the femoral head bilaterally, pelvis and right humerus. While the precise mechanism in which iron infusions cause hypophosphatemia is not completely understood, we demonstrate the probable mediation by FGF-23, a phosphaturic peptide essential for phosphate homeostasis. We also show that phosphate and calcitriol replacement at the time of the iron infusion may ameliorate the hypophosphatemia.

Based on these findings, we conclude iron infusions may cause severe asymptomatic hypophosphatemia. We hypothesise that due to the lack of symptoms and post infusion monitoring, hypophosphatemia is a more common complication of iron infusions than currently recognised. Furthermore, as our case illustrates, failure to recognise and treat the hypophosphatemia in the context of multiple iron infusions, can lead to osteomalacia in the long term.

Refreezing bone thawed by intermittent PTH? – A therapeutic dilemma

Sabashini K Ramchand¹, Cherie Chiang^{1,2}, Ego Seeman^{1,2}

1. Department of Endocrinology, Austin Health, Melbourne, Victoria, Australia

2. Department of Medicine, Austin Health, University of Melbourne, Melbourne, Victoria, Australia

Atypical femoral fractures (AFF) are stress fractures occurring at the lateral cortex of the subtrochanteric region (1). AFFs are associated with anti-resorptive use; the risk increases with increasing duration of exposure (2). The optimal management of patients with osteoporosis in the context of AFFs is challenging.

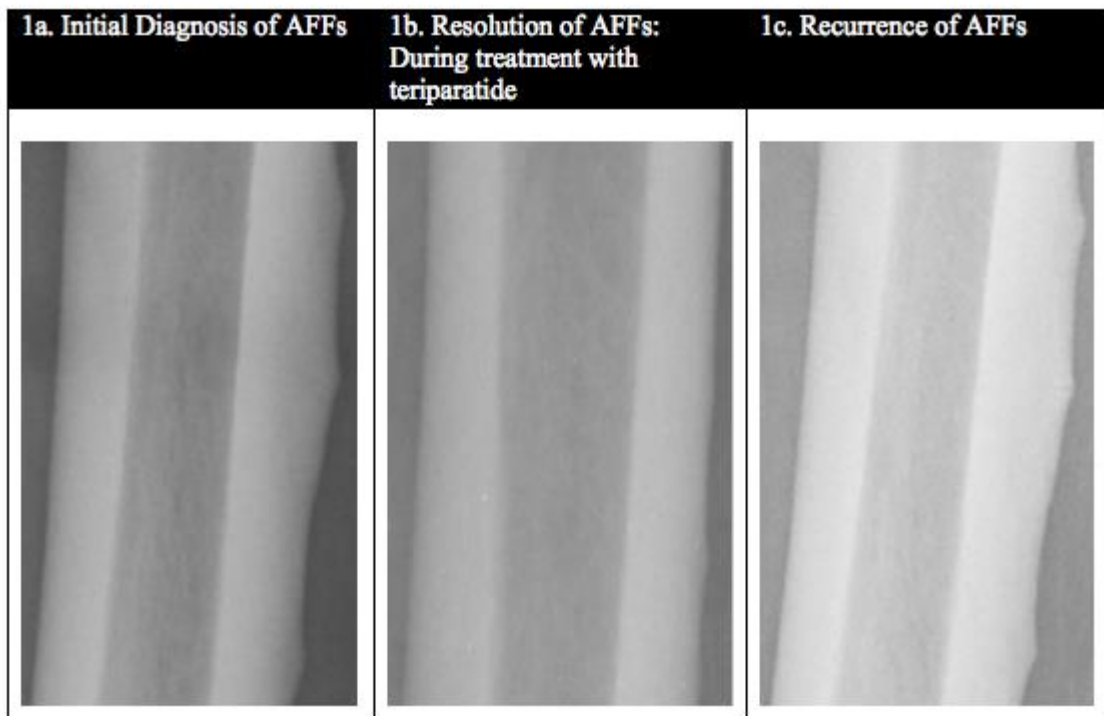
An 82 year old Caucasian woman with osteoporosis was treated with 7 years of oral bisphosphonates when she presented with bilateral thigh pain aggravated by mobilisation. Imaging revealed bilateral incomplete stress fractures in the lateral cortex of each femoral shaft (Fig. 1a).

Bisphosphonate (BP) therapy was discontinued and the patient agreed to a trial of teriparatide for 18 months. At the completion of this treatment she reported a reduction in thigh pain. Serial imaging showed healing of the stress fractures (Fig. 1b).

As this patient had osteoporosis and microstructural deterioration, assessed using high-resolution computed tomography, to preserve any benefits derived from teriparatide and to prevent structural decay, denosumab was commenced 12 months after cessation of teriparatide. Six months later, the patient reported increasing bilateral thigh pain. Repeat imaging confirmed the presence of recurrent bilateral mid shaft stress fractures (Fig 1c). The patient had prophylactic bilateral internal fixation.

This case illustrates the challenge in treating patients with osteoporosis and severe structural decay who suffer atypical femoral fractures associated with BP therapy. If left untreated after stopping BP, remodelling will increase, leading to continued structural decay. If anti-resorptive treatment is recommenced, remodelling is likely to be suppressed, and this may result in altered material composition predisposing to recurrent AFFs. Novel approaches such as sclerostin antibodies, which stimulate bone formation and reduce remodelling, combined or sequential use of denosumab or odanacatib plus PTH, or use of SERMs like raloxifene, which improve bone toughness – may play a role in the management of osteoporosis and AFF.

Figure 1: Serial plain radiographs of left mid femoral shaft



1. Shane E, Burr D, Abrahamsen B, Adler RA, Brown TD, Cheung AM, Cosman F, Curtis JR, Dell R, Dempster DW, Ebeling PR, Einhorn TA, Genant HK, Geusens P, Klaushofer K, Lane JM, McKiernan F, McKinney R, Ng A, Nieves J, O'Keefe R, Papapoulos S, Howe TS, van der Meulen MC, Weinstein RS, Whyte MP. Atypical subtrochanteric and diaphyseal femoral fractures: second report of a task force of the american society for bone and mineral research. *Journal of Bone and Mineral Research*. 2014;29:1-23.
2. Schilcher J, Michaelsson K, Aspenberg P. Bisphosphonate use and atypical fractures of the femoral shaft. *The New England Journal of Medicine*. 2011;364:1728-1737.

Severe PTU related hepatotoxicity during pregnancy - A case report.

Christopher Sadler¹, Ross Cuneo¹

1. Department of Endocrinology, Princess Alexandra Hospital, Woolloongabba, QLD, Australia

Graves disease is common amongst women of reproductive age. First line treatment is anti-thyroid medication with Propylthiouracil (PTU) recommended during the first trimester. PTU carries a small but significant risk of fulminant hepatic necrosis, at times fatal or necessitating transplant.

We discuss a case of a 33 year old Polynesian mother of five presenting with lethargy, pruritis and jaundice at 14 weeks gestation. She had a 4 year history of recurrent Graves' disease treated intermittently with Carbimazole, swapped to PTU during early pregnancy. She was euthyroid at presentation.

Initially she was deeply jaundiced, with mild encephalopathy and impaired synthetic function (total bilirubin 294 $\mu\text{mol/L}$, INR of 2.2, albumin 26). Half the bilirubin was unconjugated. Bilirubin peaked at 450 $\mu\text{mol/L}$ eight days after PTU cessation, transaminases peaked earlier with ALT 3060, AST 2790, ALP 639 and GGT 36 u/L . Trans-jugular liver biopsy showed acute hepatic necrosis with lobular and portal hepatitis involving fifty percent of hepatocytes. Most liver indices improved over 2 weeks, with bilirubin lagging.

Her course was complicated by episodes of fasting hypoglycemic episodes treated with oral supplements overnight.

Free T4 remained in the normal range for a week, then rose 1 pmol/L per day (to 28 pmol/L at the planned thyroidectomy). Morphology scan showed a normal, healthy fetus. At the time of writing thyroidectomy was pending.

Although clinically overt PTU induced hepatitis was seen in up to 1.2% of patients in one study severe liver injury is rarely reported. Unconjugated bilirubin is believed to cross the placenta, however outcome data for a fetus exposed to high levels during early pregnancy is sparse. We present a case illustrating a rare and serious adverse reaction to a commonly prescribed drug in pregnancy with a likely positive outcome for mother and uncertain prognosis for child.

1. Limaye, A., & Ruffolo, P. R. (1987). Propylthiouracil-induced fatal hepatic necrosis. *The American Journal of Gastroenterology*, 82(2), 152-4.
2. Sequeira, E., Wanyonyi, S., & Dodia, R. (2011). Severe propylthiouracil-induced hepatotoxicity in pregnancy managed successfully by liver transplantation: A case report. *Journal of Medical Case Reports*, 5(1), 461. doi:10.1186/1752-1947-5-461

- Kim, H. J., Kim, B. H., Han, Y. S., Yang, I., Kim, K. J., Dong, S. H., ... Chang, R. (2001). The incidence and clinical characteristics of symptomatic propylthiouracil-induced hepatic injury in patients with hyperthyroidism: a single-center retrospective study. *The American Journal of Gastroenterology*, 96(1), 165–9. doi:10.1111/j.1572-0241.2001.03469.x
- Waffarn, F., Carlisle, S., Pena, I., Hodgman, J. E., & Bonham, D. (1982). Fetal exposure to maternal hyperbilirubinemia. Neonatal course and outcome. *American Journal of Diseases of Children* (1960), 136(5), 416–7.
- Miyamura, T., Kanda, T., Minemura, S., Nakamura, M., Nakamoto, S., Jiang, X., ... Yokosuka, O. (2013). Acute liver failure associated with propylthiouracil in a pregnant 26-year-old woman. *Case Reports in Gastroenterology*, 7(2), 240–4. doi:10.1159/000351877

Achey breaky bones: a focus on skeletal disease in β -thalassaemia major.

Stella Sarlos^{1,2}, Phillip Wong^{1,2}, Peter Fuller^{1,2}, Carolyn Allan^{1,2}, Frances Milat^{1,2}

1.MIMR-PHI (formerly Prince Henry's Institute of Medical Research), CLAYTON, VIC, 3168

2.Department of Endocrinology, Monash Health, CLAYTON, VIC, AUSTRALIA

Patients with β -thalassaemia major have improved life expectancy and present unique challenges in medical management. The Monash Health service is the state referral centre for thalassaemia with experience spanning 30 years (1). We present the clinical course of a 49 year old man with β -thalassaemia major known to our health service since 1984, with multiple complications including hypogonadotrophic hypogonadism, severe osteoporosis, extramedullary erythropoiesis, mild cardiomyopathy and retinal pseudoxanthoma elasticum.

Having declined blood transfusions for over 20 years (religious beliefs), there has been significant impact on the progression of bone disease (2). From age 31, he had sustained multiple fractures despite regular im testosterone replacement and bisphosphonate therapy from 1997-2011 (3). Extramedullary erythropoiesis resulted in spinal cord compression in 1999 in the setting of im testosterone, but also again in 2007. On both occasions he received radiotherapy and hydroxyurea. Testosterone therapy was considered essential given the evolving severe osteoporosis. Upon recovery in 2007 he was changed to transdermal testosterone formulations to avoid large fluctuations in serum testosterone (4), given concern these may lead to intermittent marrow expansion.

In the face of progressive BMD decline and additional vertebral fractures, ongoing active treatment of osteoporosis was desired, but options limited. Given previous treatment with radiotherapy, teriparatide was contraindicated. With stable cardiovascular status and no history of thrombosis, strontium ranelate was commenced October 2013 with full disclosure to the patient of potential side effects.

Our case highlights the morbidity associated with severe osteoporosis in β -thalassaemia, as well as the unique challenges of optimising bone health in the non-transfused, hypogonadal patient. Furthermore, we report the correlation between the testosterone preparation pharmacokinetics and the serious complication of bone marrow expansion with spinal cord compression in thalassaemia. Considered selection of testosterone formulation according to clinical picture and the patients' adequacy of transfusion is advisable.

Myxoedema coma presenting with cerebellar dysfunction

Emma S Scott¹, Emily Hibbert¹

1.Nepean Hospital, Sydney, NSW, Australia

BACKGROUND

Hypothyroidism can present with signs of cerebellar dysfunction¹. Untreated hypothyroidism can progress to myxoedema coma, a rare condition with high mortality². Sepsis is a common precipitant for myxoedema coma in untreated hypothyroidism.

CLINICAL CASE

A 59 year old woman presented with a 12 month history of cognitive decline, dysarthria and bilateral limb ataxia. She had dysdiadochokinesis, intention tremor and past pointing. Cranial nerves, power, tone and reflexes were normal. A provisional diagnosis of stroke was made and she was admitted under neurology. Non contrast CT brain was normal. On day three of admission the patient developed hypothermia (T 33.2°C), hypoglycaemia (glucose 3.5mmol/L), hyponatraemia (Na 124 mmol/L [135-145]), type 2 respiratory failure and tonic-clonic seizures. ECG showed sinus rhythm with QT prolongation. Thyrotropin (TSH) was 98 mIU/L [0.2-3.5] with undetectable free thyroxine (fT4), thyroid peroxidase antibody 880 IU/mL [0-35] but negative thyroglobulin antibody. Septic screen revealed *Staphylococcus saprophyticus* urinary tract infection.

The patient required intubation and ventilation for 2 days, and inotropic support for hypotension. She was passively rewarmed and treated with cefazolin and sodium valproate. 150mcg T4 was given followed by intravenous liothyronine (T3) 20mcg bd. Nasogastric T4 125mcg daily was poorly absorbed, so NG T4 and IV T3 were co-administered for 5 days. Glucocorticoid stress doses were given until exclusion of adrenal insufficiency was excluded on short synacthen test (Time 0: 242 nmol/L, Time 30: 578nmol/L, Time 60: 638 nmol/L [N > 550]). A cerebral MRI showed chronic microvascular disease. Lumbar puncture excluded infection, but demonstrated elevated protein (1.14 g/L [0.25-0.55]). Serum sodium normalised by day 7. Cerebellar signs and confusion had completely resolved by day 29. TSH was 6.53 mIU/L by discharge on day 34.

CONCLUSION

Patients presenting with neurological signs require exclusion of hypothyroidism. Neurological signs may resolve with treatment of hypothyroidism³. Myxoedema coma remains challenging to manage.

- Selim M, Drachman DA. Ataxia associated with Hashimoto's disease: progressive non-familial adult onset cerebellar degeneration with autoimmune thyroiditis. *J Neurol Neurosurg Psychiatry* 2001; 71: 81-87
- Wartofsky L. Myxedema Coma. *Endocrinol Metab Clin N Am* 2006; 35: 687-698.

Withdrawal of renin angiotensin aldosterone system blockade precipitating hyponatraemic hypertensive syndrome crisis - A cautionary tale.

Emma S Scott¹, Bernard Champion¹, Danijela Dravec¹

1. Nepean Hospital, Sydney, NSW, Australia

INTRODUCTION

Hyponatraemic hypertensive syndrome (HHS) is associated with unilateral renal ischaemia¹. It is characterised by resistant hypertension, elevated renin and aldosterone, pressure natriuresis with consequent hyponatraemia, hypokalaemia and volume depletion².

BACKGROUND

A 48 year old woman presented with chronic hyponatraemia (Na 113-124 mmol/L [135-145]) and confusion. Background included hypertension (normotensive on olmesartan, lercanidipine, enalapril and moxonidine) and peripheral vascular disease. Serum sodium 131 mmol/L [135-145], osmolality 274 mOsm/kg [275-295], urine osmolality 212 mOsm/kg [300-900] and urinary sodium 53 mmol/L [N high \leq 16]. Secondary causes of hyponatraemia were excluded (Cortisol 775 nmol/L [100-540], TSH 1.46 [0-12]). Olmesartan, enalapril and lercanidipine were withdrawn over 2 months. The patient deteriorated, requiring hospitalisation with increased confusion, hypertension (160/90mmHg sitting, 120/80mmHg standing), hyponatraemia (Na 113, serum osmolality 241 mOsm/kg, urine osmolality 229 mOsm/kg, urine sodium 11 mmol/L), hypokalaemia (2.7 mmol/L [3.2-5]), and acute kidney injury (eGFR 33 ml/min/1.73m²).

Serum aldosterone was increased (3435 pmol/L [80-1040]). 24 hour urine protein was elevated 20.42 g/day with negative nephrotic screen. Renal ultrasound demonstrated a hypoplastic left kidney (7.59cm) with absent renal artery flow. On day 4 the patient transferred to the intensive care unit with hypertensive encephalopathy requiring sedation. Sodium normalised over 12 hours with 3% hypertonic saline. Blood pressure was controlled following reintroduction of ACE inhibition (ramipril 10mg). Renal vein sampling revealed elevated plasma renin (> 8000 Fm/L/s [100-1500]) with right and left renal vein renin 7433 Fm/L/s and > 8000 Fm/L/s respectively. DTPA scan identified virtually non-functioning left kidney. Blood pressure, electrolytes, proteinuria and renal function improved with ramipril. This is consistent with HHS, driven by unilateral renal ischaemia.

CONCLUSION

HHS is underreported^{3,4}. The cornerstone of therapy is nephrectomy or blockade of renin angiotensin aldosterone system. Clinicians need to be aware of the phenomena and vigilant to the dangers of ceasing ACE blockade in such individuals.

1. Brown JJ, Davies DL, Lever AF, Robertson JIS. Plasma renin concentration in human hypertension. 1: Relationship between renin, sodium, and potassium. *Br Med J*. Jul 17, 1965; 2 (5454): 144-148.
2. Browne WL, Nair B. The hyponatraemic hypertensive syndrome in renal artery stenosis: an infrequent cause of hyponatraemia. *J Postgrad Med*. 2007; 53 (1): 41-43.
3. Agarwal M, Lynn KL, Richards AM, Nicholls MG. Hyponatraemic-hypertensive syndrome with renal ischaemia: an underrecognized disorder. *Hypertension*. 1999; 33 (4): 1020-1024.
4. Kovalski Y, Cleper R, Krause I, Dekel B, Belenky A, Davidovits M. Hyponatraemic hypertensive syndrome in pediatric patients: is it really so rare? *Paediatr Nephrol*. 2012; 27 (6): 1037-1040.

Disseminated pineal gland germinoma presenting with pan-hypopituitarism mimicking Lymphocytic hypophysitis

Anita Singh¹, Mark A/Prof Kotowicz¹

1. Barwon Health, Rosanna, VIC, Australia

We present a case of disseminated intracranial germinoma presenting with diabetes insipidus and evolving panhypopituitarism.

A 17 year-old man presented with three month history of frequent nocturia, polydipsia associated with lethargy, weight loss and erectile dysfunction with normal secondary sexual characters. His initial investigations revealed a picture of hypogonadotropic hypogonadism associated with diabetes insipidus and was commenced on testosterone replacement and intranasal desmopressin

Testosterone : <0.7 nmol/L (8.0-26.0)

FSH : 0.4IU/L (1.4-18)

LH : 0.6IU/L

Cortisol : 405 nmol/L

MRI of the pituitary gland showed a normal pituitary gland with no stalk thickening and no mass effect on the hypothalamus. An incidental finding of a septated pineal cyst, measuring 14mmx10mmx12mm with enhancing septations was also noted. A transsellar pineal gland biopsy was inconclusive. A second biopsy under stereotactic guidance showed a calcified arachnoid cyst with no evidence of germ cell tumor.

He later developed secondary adrenal insufficiency and central hypothyroidism.

Cortisol 25 nmol/L

ACTH 1.6 pmol/L (<20.0)

TSH 2.019 mIU/L (0.300-4.000)

FT4 : 9.1 pmol/L (11.5-22.7)

FT3 : 2.8 pmol/L (3.5-6.7)

A repeat MRI revealed pituitary infundibular thickening and abnormal enhancement of the infundibulum and hypothalamus. The pineal tumor appeared solid and had increased in size. With the suspicion of lymphocytic hypophysitis, he was commenced on high dose prednisolone 50 mg daily for 4 weeks with no improvement in symptoms

He later developed a bitemporal hemianopia and an MRI revealed an increased pineal tumor measuring 18x17x17 mm with extension into adjacent brain parenchyma, extending to lateral ventricle, and suprasellar extension involving the optic chiasm. He underwent a craniotomy and pineal gland biopsy which confirmed a disseminated germinoma of the pineal gland.

Immunomodulation: Changing epidemiology of hypophysitis – Case reports

Divya Srivastava^{1,2}, Beverly Rodrigues¹, Vasant Shenoy^{1,2}, Zulfiquer Otty³, Kunwarjit S Sangla²

1. School of Medicine and Dentistry, James Cook University, Townsville, Qld, Australia

2. Department of Diabetes and Endocrinology, The Townsville Hospital, Douglas, QLD, Australia

3. Department of Oncology, The Townsville Hospital, Douglas, QLD, Australia

Autoimmune hypophysitis has been an uncommon cause of pituitary dysfunction [1]. However the increasing use of immunomodulation in cancer therapy has resulted in a rise and changing demographic of immune mediated endocrinopathies including hypophysitis [2,3]. We present two such cases of Ipilimumab (Anti CTLA4 checkpoint inhibitor) associated hypophysitis.

Both cases had metastatic melanoma, but disease presentation and burden differed. Whilst both patients also had generalised lethargy, their endocrine manifestations differed from secondary hypothyroidism only in one case and dual pituitary axes involvement in the other. Both had pituitary masses on imaging and whilst one received intravenous steroids, the other was managed on an outpatient basis only with oral steroids. Pituitary masses resolved in both cases, but one was weaned off thyroxine whilst the other required ongoing replacement therapy and their progression of underlying disease also differed.

Ipilimumab is proven to improve survival in patients of metastatic melanoma, but is associated with the risk of autoimmune endocrinopathies [2,3], which if diagnosed early can prevent significant morbidity & mortality. It is imperative that we as clinicians recognise and differentiate this disease spectrum from metastatic disease and identify optimal treatment regimens to enable the best possible outcomes for our patients.

1. Patrizio Caturegli, Craig Newschaffer, Alessandro Olivi, Martin G. Pomper, Peter C. Burger, and Noel R. Rose: Autoimmune Hypophysitis. *Endocrine Reviews*, 2005. 26(5): p. 599-614.
2. Corsello SM, Barnabei A, Marchetti P, De Vecchis L, Salvatori R, Torino F. Endocrine side effects induced by immune checkpoint inhibitors. *The Journal of clinical endocrinology and metabolism*. 2013 Apr;98(4):1361-75. PubMed PMID: 23471977.
3. Torino F, Barnabei A, De Vecchis L, Salvatori R, Corsello SM. Hypophysitis induced by monoclonal antibodies to cytotoxic T lymphocyte antigen 4: challenges from a new cause of a rare disease. *The oncologist*. 2012;17(4):525-35. PubMed PMID: 22477725. Pubmed Central PMCID: 3336822.

Removing interferences in plasma metanephrine analysis by LC-MS

Michael J Wright¹, Rebecca L Thomas¹, Phoebe E Stanford¹

1. SEALS (South Eastern Sydney Laboratory Services), Randwick, NSW, Australia

Introduction

Liquid chromatography Mass-spectrometry (LC-MS) is a widely used method for the quantitation of plasma metanephrines.

In 2% of our patients, 6 different uncharacterised co-eluting endogenous substances were found to interfere with the LC-MS/MS assay leading to inability to report results. We investigated the use of MRM³ detection to improve the selectivity of this important diagnostic assay.

Methods

Metanephrine and Normetanephrine were isolated from plasma samples using weak cation exchange solid phase extraction prior to analysis. Prepared samples were injected onto a Shimadzu Prominence HPLC system and chromatographic separation was achieved with hydrophilic interaction liquid chromatography. Mass spectrometric detection was performed using an ABSciex QTRAP 5500 mass spectrometer operating in positive ion electrospray mode.

Normetanephrine and Metanephrine were quantitated by two different processes. MRM transitions were created for each fragment produced by collision induced dissociation of the target analytes. By use of linear ion trap technology, each fragment was then fragmented again to produce MRM³ transitions. All MRM and MRM³ transitions were then assessed for analytical specificity.

Results

Over a 6 month period, 21 patient samples were identified as being affected by one or more interferences. Retrospective review of drug history could not yet identify a cause for these interferences.

No MRM transition fragments were capable of removing all the interferences. Each fragment was fragmented again and MRM³ transitions were then assessed. For metanephrine 180/149/121 and for normetanephrine 166/134/79, all interferences were removed.

Using these new MRM³ transitions a sample comparison was completed against the existing MRM method (Metanephrine 180/148, Normetanephrine 166/134) showing good agreement with slopes of 1.04 and 1.01 (Deming Regression) and bias of -3.2% and 0.2% for Metanephrine and Normetanephrine, respectively.

Conclusion

This is the first demonstration of MRM³ technology for the interference-free quantitation of plasma metanephrines contributing to improved quality of patient results.

287

Case reviews of a cohort of Multiple Endocrine Neoplasia (MEN) patients

Himali Suwandarathne¹, Alison Colley¹, Namson Lau¹

1.liverpool hospital, liverpool, NSW, Australia

Background:

Methodology:

From 1997 – 2014, all patients presenting to the tertiary referral Department of Clinical Genetics for South West Sydney with a positive molecular genetic result for MEN were identified and retrospectively analysed for demographic data, genotype, phenotype and clinical progress.

Results:

6 families with MEN were identified; 3 had MEN1, while rest had MEN 2a

1st family was Cambodian in origin. Proband had metastatic medullary thyroid cancer and recurrent bilateral extra adrenal pheochromocytomas consistent with MEN 2a. The RET proto-oncogene was identified; her children were negative while a cousin, who had medullary throid carcinoma and bilateral pheochromocytoma, was checked; results pending.

2nd family was Lebanese in origin. Proband had prolactinoma and hyperparathyroidism and found to have a rare mutation in MEN1 gene, later also found in her unaffected father.

3rd family was Anglo-Australian with known family mutation of TAS1 gene for MEN 1. Proband and mother were asymptomatic and had positive predictive tests, while maternal grandmother was positive with prolactinoma and hyperparathyroidism

4th family was Spanish in origin. While proband had negative predictive test, the sister and nephew were found to have a RET proto-oncogene for MEN 2a.

5th family was Anglo-Australian with known MEN 2a. Proband had pheochromocytoma with RET gene mutation; her unaffected daughter has the same mutation while 2 sons were negative.

6th family was Greek in origin. Proband has prolactinoma and hyperparathyroidism and pathogenic mutation for MEN1; waiting results of predictive testing for her children.

Conclusion:

While MEN is a rare disorder, the diagnosis is associated with a long term risk for malignancy. Screening at-risk family members is an essential part of management as it allows for targeted surveillance and early detection of neoplastic processes.

288

Opioid-induced transient secondary hypoadrenalism: are some clinically significant cases being overlooked?

Eddy J Tabet^{1,2}, Angela ST Lee^{1,2}, Elizabeth L Chua^{1,2}, Stephen M Twigg^{1,2}

1.Department of Endocrinology, Royal Prince Alfred Hospital, Camperdown, NSW, Australia

2.Sydney Medical School, University of Sydney, Camperdown, NSW, Australia

Opioid-induced hypoadrenalism may be an under-recognised entity with potential serious adverse outcomes. We report a case of acute, transient secondary hypoadrenalism in a hospitalised patient who received fentanyl and tramadol.

Case:

An 18 year-old female with a long history of hollow visceral myopathy presented with small bowel obstruction. Intravenous fentanyl was administered initially followed by high dose oral tramadol in the eight subsequent days. She then had multiple episodes of documented fasting hypoglycaemia despite adjustment of parenteral carbohydrate administration. There was no history of diabetes mellitus, exogenous insulin or oral hypoglycaemic medication use. Investigation for what was determined to be non-insulin mediated hypoglycaemia revealed a low morning cortisol of 109nmol/L and an inappropriately low ACTH level of 2.2pmol/L.

A diagnosis of secondary hypoadrenalism was confirmed on repeat cortisol and ACTH testing and by a sub-normal short SynACTHen test. After cessation of opioid therapy, there was recovery of adrenal function at ~24 hours with normalisation of morning cortisol and propensity to hypoglycaemia. However, the hypocortisolaemic pattern was replicated when fentanyl was readministered 5 days later. Subsequent short SynACTHen test and ACTH level undertaken nine days after opioid cessation reflected HPA axis recovery.

Discussion:

This case of transient opioid-induced secondary hypoadrenalism caused secondary fasting hypoglycaemia. Opioid-induced hypoadrenalism is a likely under-recognised clinical entity with potentially serious adverse patient outcomes. There are reported cases involving commonly prescribed opioids including fentanyl, tramadol and methadone. Both ACTH and β -endorphin are peptide derivatives of proopiomelanocortin. This patient's HPA axis was particularly susceptible to exogenous opioid causing negative feedback on ACTH, possibly via its relationship to β -endorphin. Given the widespread use of opioids, further studies are required to define what percentage of patients are affected by clinically significant acute and more long-term hypoadrenalism, and factors potentially modulating this relationship at the receptor and post-receptor level.

1. Debono et al, Tramadol-induced adrenal insufficiency, Eur J Clin Pharmacol (2011) 67: 865-867

2. Abs et al, Endocrine consequences of long-term intrathecal administration of opioids, J Clin Endocrinol Metab. 2000; 85(6): 2215-22

Adrenal vein sampling: the Monash health experience

Jessie Teng¹, Maeve E Hutchinson¹, James C G Doery², Kay Weng Choy², Winston Chong³, Peter Fuller¹, Jun Yang¹

1. Endocrinology, Monash Health, Clayton, Victoria, Australia

2. Pathology, Monash Health, Clayton, Victoria, Australia

3. Radiology, Monash Health, Clayton, Victoria, Australia

Adrenal vein sampling (AVS) is crucial in the diagnosis of the aetiology of primary aldosteronism (PA)[1]. However, AVS is technically demanding, difficult to interpret and lacks uniform guidelines especially with regard to the use of corticotropin (ACTH) stimulation [2]. The Endocrinology Unit at Monash Health implemented its own evidence-based, centre-specific AVS protocol in January 2010 to develop a focused expertise in the performance and interpretation of AVS.

Our aims were to: examine the impact of a dedicated protocol on the success rates of AVS; assess the utility of ACTH stimulation in AVS; and evaluate the impact of AVS on the final subtype diagnosis of PA.

An audit was conducted on all AVS procedures performed between January 2005 and May 2014 at Monash Health. Clinical information was collected on: patient demographics, screening aldosterone and renin concentration, AVS aldosterone and cortisol levels pre- and post-ACTH stimulation, adrenal imaging, blood pressure and antihypertensive requirements.

The overall technical success rate of AVS procedures was 47% before (n = 17) and 65% (n= 24) after the implementation of the AVS protocol. ACTH-stimulation permitted lateralization in one patient, however, it incorrectly obscured lateralization in two cases. Of the 12 aldosterone producing adenomas diagnosed, AVS crucially demonstrated lateralization in three patients where imaging showed bilateral or no adenomas, two of whom have had a surgical cure while the third is awaiting surgery. Furthermore, three patients had unilateral adrenal lesions on CT but bilateral aldosterone secretion on AVS. *All authors contributed equally on this abstract.

Our study demonstrates that AVS is critical in the subtype diagnosis of PA and should be performed by a dedicated radiologist with a standardized protocol. ACTH increases apparent cannulation success, but may lead to loss of lateralization. Performing AVS both pre- and post-ACTH stimulation will offer more data to determine the appropriateness of this component of the AVS procedure. The first two authors contributed equally to this work.

Pharmacokinetic-Pharmacodynamic (PK/PD) study of subcutaneous injection of Nandrolone Decanoate (ND) in an oil vehicle using Dried Blood Spots (DBS) blood sampling coupled with liquid chromatography, tandem mass spectrometry (LC-MS) assays

Gurmeet KS Singh^{1,2}, LEO A TURNER³, Reena Desai⁴, Mark Jimenez², David J Handelsman²

1. FACULTY OF PHARMACY, UNIVERSITI TENOLOGI MARA (UiTM), BANDAR PUNCAK ALAM, SELANGOR, MALAYSIA

2. ANDROLOGY DEPT CONCORD HOSPITAL, ANZAC RESEARCH INSTITUTE UNIVERSITY OF SYDNEY, SYDNEY, NSW, AUSTRALIA

3. ANDROLOGY DEPT, CONCORD HOSPITAL, SYDNEY, NSW, AUSTRALIA

4. ANDROLOGY, ANZAC RESEARCH INSTITUTE, SYDNEY, NSW, AUSTRALIA

Introduction: Testosterone (T) and nandrolone (N) esters in an oil vehicle require deep intramuscular (im) injections by skilled medical personnel. As im injections often deposit injectate into subdermal fat, more convenient self-administered subcutaneous (sc) injections may be feasible.

Aim: To investigate the (a) PK/PD of sc injection of ND in healthy volunteer men using DBS for remote time intensive blood sampling without frequent clinic visits and (b) feasibility of sc injections of androgen ester in an oil vehicle.

Methods: Healthy young eugonadal men (n=8) were administered 100 mg ND in 2 mL arachis oil vehicle by sc injection at a single abdominal site. Capillary blood by finger prick was dried onto filter paper, recording the time of sampling, before and daily for 21 days. Venous blood was sampled before and weekly to store serum and spot onto filter paper. After storage at room temperature, DBS underwent elution and extraction for assay of N and T by LC-MS. Serum N and T concentrations were adjusted for capillary blood sample volume and hematocrit to define peak (N) or nadir (T) time and concentration.

Results: Serum N rose to a peak of 2.50 ± 0.25 (SEM) ng/mL at a median (range) of 6 (4-13) days causing a reduction in serum T representing $89 \pm 3\%$ maximal suppression from baseline to a nadir of 0.38 ± 0.13 ng/mL at a median of 8 (5-16) days. Simultaneously sampled capillary and venous blood showed a high correlation for serum N and T

Conclusions: This demonstrates that (a) DBS sampling coupled with LC-MS steroid assays can achieve intensive time sampling for PK/PD studies in the community without requiring frequent clinic visits, venesection or frozen serum storage and (b) androgen esters in an oil vehicle can be delivered predictably and conveniently by sc injection

Dermatomyositis due to metastatic pheochromocytoma: case report

Thomas Ulahannan¹, Upjeet Bambery¹, Pradeep Bambery¹

1. Bundaberg hospital, Bundaberg, QLD, Australia

Dermatomyositis is well known to accompany several malignancies and was reported once before with a non functioning pheochromocytoma. We describe a novel case of dermatomyositis due to metastatic pheochromocytoma. A 77 year old female presented with malaise, cough, arthritis and unintentional weight loss of more than 14 kg over 8 weeks. Past Medical History included Right adrenalectomy for benign adrenal tumor in 1986 in London and pan- ulcerative colitis for more than 25

years on no medication for years. CT showed enlarged lymph nodes in the right lower mediastinum and an enlarged left upper para-aortic lymph node. No focal liver lesion was shown in the pancreas, remaining adrenal, small bowel, colon and kidneys. I-123 MIBG scan showed intense uptake in the right mediastinal and upper para-aortic lymph nodes consistent with likely metastatic pheochromocytoma (MP). There was normal uptake in the right adrenal gland. Investigation revealed elevated plasma 3-Methoxy Tyramine 241 pmol/L (< 110), Normetadrenalin 12,000 pmol/L (< 900) and Metadrenaline 1,290 pmol/L (< 500). She was not considered suitable for specific treatment of the pheochromocytoma due to her co-morbidities. After 4 months she was readmitted with weight loss, decreased appetite, lethargy, difficulty walking, raising arms and dyspnoea. Rheumatology review revealed normal CK, effacement of finger folds and Gottron's papules. The clinical diagnosis was amyopathic dermatomyositis, which responded to corticosteroids and methotrexate. Worsening symptoms of dermatomyositis occurred when tapering of prednisolone was attempted.

Previously dermatomyositis has been reported in connection with MP on one occasion but the tumour was non-functioning. In this case the MP was active and producing high levels of catecholamines. High doses of corticosteroids were required which led to insulin requirement for glucose control and hypokalaemia which are known complications of corticosteroid therapy. Dermatomyositis has not, to our knowledge, been reported with functioning MP before.

A Hybrid Pheochromocytoma-Ganglioneuroma in a symptomatic elderly man: case report and literature review

Sofia Velosa^{1,2}, Nicholas Hockings², Jason Hockings^{2,3}, Shenaz Seedat^{1,2}, Shinn Yeung^{2,3,4}, Elisabeth Nye¹, Gregory Hockings^{1,2}

1. Department of Endocrinology, Greenslopes Private Hospital, Greenslopes, QLD, Australia

2. School of Medicine, University of Queensland, Brisbane, QLD, Australia

3. Princess Alexandra Hospital, Brisbane, QLD, Australia

4. General Surgical Unit, Greenslopes Private Hospital, Brisbane, QLD, Australia

A 73-year-old man was referred because of an incidentally discovered right adrenal gland lesion. He had a three-year history of untreated hypertension, being previously intolerant of a beta-blocker. His symptoms included anxiety, flushing, palpitations, diarrhoea, weight loss and tremor. Medical history included benign prostatic hypertrophy, Hashimoto's disease and early Parkinson's disease. Medications comprised dutasteride/tamsulosin 500mcg/400mcg and desiccated thyroid extract. Family history was unremarkable.

On examination, blood pressure was 160/80 mmHg sitting. Pulse was 75 bpm and regular. There were no cutaneous features of NF, VHL or MEN2B. Cardiovascular examination was normal, thyroid was impalpable. Pathology revealed elevated plasma normetadrenaline (1590 pmol/L, RR<900) and 24-hour urine normetadrenaline (3.4 umol/day, RR<2.3). Plasma 3-methoxytyramine was elevated (190 pmol/L), as were urinary HMAA (49 umol/day, RR<33) and chromogranin A (106 ug/L, RR <85). A 2.9 x 2.6 x 2.8 cm right adrenal mass was identified on CT scan. It was reported as indeterminate (atypical) on the basis of a CT washout study, with an absolute washout of 46% and a pre-contrast density of 23 Hounsfield units. Serial imaging showed a minimal increase in size over a 13-month period. An I-123 MIBG scan demonstrated moderate isotope uptake.

900>A diagnosis of pheochromocytoma with low-grade secretory activity was made and the patient proceeded to laparoscopic right adrenalectomy after medical preparation with phenoxybenzamine, metoprolol and perindopril. Histopathology reported a hybrid pheochromocytoma-ganglioneuroma tumour. Post-operative plasma normetadrenaline levels were normal. He recovered uneventfully, but his hypertension persisted. His flushing episodes and diarrhoea resolved post-operatively and he regained 5 kg in weight.

This patient's case illustrates that mild and selective catecholamine elevations may still indicate significant adrenal dysfunction, that there may be underlying essential hypertension in such patients, that unusual symptoms may be caused by catecholamine excess and that radiologically atypical adrenal lesions require detailed investigation, especially in symptomatic patients¹.

1. Estey MP, Diamandis EP, Eisenhofer G et al Clin Chem 2013; 59(3): 466-472

Management of osteoporosis in patients admitted with hip and vertebral fractures – an audit at Lyell McEwan hospital

Nisha Venkatesh¹, Peak Mann Mah¹, Elaine Pretorius¹, Anthony Zimmermann¹

1. Department of Endocrinology, Northern Adelaide Local Health Network, Elizabeth, SA, Australia

Problem: Osteoporosis is a condition associated with significant morbidity, mortality and economic costs. It is a disease amenable to primary and secondary prevention. Our aim was to ascertain the quality of osteoporosis management by conducting an audit of patients presenting with minimal trauma hip and vertebral fractures to our facility.

Methods A retrospective audit of patients admitted with hip and vertebral fractures between January and December 2011 was conducted.

Results 143 patients were reviewed.

In 52 patients who had a prior diagnosis of osteoporosis:

- 80% had risk factors for secondary causes of osteoporosis, warranting a review of their diagnosis and management.
- 71% were receiving vitamin D or calcium prior to admission, increasing to 77% of patients on discharge.

- 61.5% were receiving anti-resorptive treatment (bisphosphonates, strontium) prior to admission, increasing to 64% on discharge (bisphosphonates, strontium).

In 91 patients who had no prior diagnosis of osteoporosis:

- 97.8% had at least one risk factor for osteoporosis.
- 6% of patients had bone densitometry organised during their admission.
- 26% were receiving vitamin D or calcium prior to admission, increasing to 38% on discharge.
- Anti-resorptive treatment (bisphosphonates) was only started in 7.7% of patients on discharge.

A review of 101 clinical separation summaries, the documents that enable handover of the patient's care back to their primary care clinician, was conducted (summaries of patients who were deceased, transferred or palliated were excluded; some summaries were not available for review). Specific reference to osteoporosis was recorded in only 11 summaries.

Conclusions For the majority of patients presenting with minimal trauma fractures to our facility there was a failure of the treating teams to consider osteoporosis as the underlying cause and to then initiate the appropriate investigations, treatment and organise follow up. We plan to introduce guidelines and a 'Bone protection pack' to address this treatment gap.

1. Cummings SR, Melton LJ. Epidemiology and outcomes of osteoporotic fractures. *Lancet*. 2002;359:1761-67.
2. Reginster J-Y. Antifracture efficacy of currently available therapies for postmenopausal osteoporosis. *Drugs*. 2011;71(1):65-78.

A case of severe ectopic ACTH syndrome from an occult primary – diagnostic and management dilemmas

Harish Venugopal¹, Katherine Griffin¹, Saima Amer¹

1. Department of Diabetes and Endocrinology, Gold Coast University Hospital, Gold Coast, Queensland, Australia

Case report:

We present the case of a 66-year old gentleman with Cushing's syndrome with a 12-month history of rapidly declining mobility due to severe proximal muscle weakness and atrophy associated with multiple vertebral fractures, poorly-controlled diabetes and recurrent urinary tract infections. Diagnosis of ACTH-dependant Cushing's syndrome was confirmed by non-suppression with overnight low-dose dexamethasone suppression test, elevated 24-hour urinary free cortisol and ACTH levels. Ectopic ACTH secretion was suggested by non-suppression with high-dose dexamethasone suppression test and bilateral inferior petrosal sinus sampling. CT scan of head, chest, abdomen and pelvis and a gallium-68 Dotatate-PET scan failed to identify the ectopic source.

Maximum tolerated doses of ketoconazole and metyrapone failed to control his hypercortisolaemia. Persisting severe hypercortisolism and immunocompromised state led to recurrent intra-abdominal and pelvic abscesses, requiring multiple surgical interventions. He had also developed severe cardiac strain in the process making him subsequently unfit for any further surgeries. Laparoscopic bilateral adrenalectomy was considered, however decided against given concerns of technical difficulties due to recurrent intra-abdominal infections and his moribund state. Alcohol ablation of adrenal glands by retrograde adrenal vein approach was subsequently attempted resulting in biochemical remission of Cushing's syndrome. He, thereafter, improved clinically and underwent rehabilitation.

Discussion:

Resection of the primary tumour is the management of choice in patients with ectopic ACTH syndrome¹. However, tumours may remain unidentified or occult in spite of extensive efforts at trying to locate them. This can therefore pose a major management issue as uncontrolled hypercortisolaemia can lead to life-threatening infections². Bilateral adrenalectomy should be considered if adrenolytic medical treatment fails to lower cortisol levels adequately³. However, patients may be extremely unwell and unfit to undergo such a procedure. Percutaneous interventions like retrograde adrenal vein alcohol ablation may be attempted in such patients and can induce biochemical remission^{4,5}.

1. Isidori AM, Kaltsas GA, Pozza C, Frajese V, Newell-Price J, Reznek RH, et al. The ectopic adrenocorticotrophin syndrome: clinical features, diagnosis, management and long-term follow-up. *J Clin Endocrinol Metab*. 2006;91:371–7
2. Grossman AB, Kelly P, Rockall A, Bhattacharya S, McNicol A, Balwick T. Cushing's syndrome caused by an occult source: difficulties in diagnosis and management. *Nature Clinical Practice: Endocrinology and Metabolism*. Nov 2006. Vol 2. No 11
3. Salameh JR, Borman KR, Varkarakis GM. Laparoscopic bilateral adrenalectomy for occult ectopic ACTH syndrome. *J Laparoendosc Adv Surg Tech A*. 2008 Feb;18(1):52-5
4. Venkatesan AM1, Locklin J, Dupuy DE, Wood BJ. Percutaneous ablation of adrenal tumors. *Tech Vasc Interv Radiol*. 2010 Jun;13(2):89-99
5. Gatti A, Baroni MG, Romeo S, Mandosi E, Fallarino M, Bezzi M, Paciucci L, Filetti S, Morano S. A case of severe occult ectopic adrenocorticotropin syndrome treated with retrograde venous adrenal ablation using ethanol. *J Endocrinol Invest*. 2008 Dec;31(12):1135-6

The association between vasomotor symptoms and depression during perimenopause: a systematic review

Roisin Worsley¹, Robin Bell¹, Jayashri Kulkarni², Susan Davis¹

1. Women's Health Research Program, Monash University, Melbourne, VIC, Australia

2. Monash Alfred Psychiatry Research Centre, Monash University, Melbourne

AIM: There is a high incidence of depression in women presenting to menopause clinics. The aim of this review was to determine if there is an association between depressive symptoms or major depressive disorder (MDD) and vasomotor symptoms (VMS).

METHODS: A systematic review of the literature was conducted according to PRISMA guidelines. Ovid Medline, EMBASE, CINAHL and PsychInfo were searched using combinations of the following terms: hot flashes, hot flushes, night sweats, vasomotor symptoms, depression, mood disorders, depressive disorders, climacteric, menopause, perimenopause, menopause transition, cohort studies, epidemiological studies, cross sectional studies, longitudinal studies, retrospective studies, prospective studies. After combining search terms the following limits were used: human, female, English language.

RESULTS: 33 relevant publications were found, 12 from three large studies. Overall, we found a bidirectional association between VMS and depressive symptoms. This has been established in well conducted, large cross-sectional and cohort studies. There does not appear to be a relationship between VMS and MDD. However, studies examining VMS and MDD were prone to bias.

CONCLUSION: During perimenopause there is a positive, bidirectional association between VMS and depressive symptoms. There does not appear to be an association between VMS and clinically diagnosed MDD but methodologically sound studies are needed to confirm this finding.

Parenteral thyroid replacement

Ming li Yee¹

1. Peninsula Health, Melbourne, VIC, Australia

Publish consent withheld

1. Treatment with Thyroid Hormone Bernadette Bondi and Leonard Wartofsky Endocrine Reviews June 2014 35(3) 433-512

A case of inhaled corticosteroid induced hypothalamic-pituitary-adrenal axis suppression

Anna Zheng¹, Alexia Pape¹

1. Diabetes and Endocrinology, Wollongong Hospital, Wollongong, NSW, Australia

A 75yo male presented with recurrent syncope for 6 months, on the background of chronic obstructive airway disease. He had been on inhaled corticosteroid therapy (fluticasone 500microgam BD) for over 1 year, without any oral corticosteroids. On presentation, he had asymptomatic postural hypotension of up to 10mmHg, without hypoglycaemia, hyponatraemia or hyperkalaemia.

He was found to have significant hypothalamic-pituitary-adrenal axis suppression, with low serum ACTH level of <5 pg/ml, and Synacthen stimulation found peak cortisol of 116 nmol/L. After ceasing inhaled fluticasone for one week, his hypothalamic-pituitary-adrenal axis improved, but remained suboptimal. On repeat testing, his ACTH level normalised to 28 pg/ml, and peak cortisol level was 521 nmol/L on Synacthen. CT-imaging found normal adrenals and pituitary. The patient was commenced on regular steroid supplementation, and the postural hypotension resolved. There were no further syncopal episodes reported.

All forms of corticosteroids can cause hypothalamic-pituitary-adrenal suppression, including topical as well as inhaled preparations. It is important to consider mild pituitary-adrenal suppression in inhaled corticosteroid users. The discussion will include a literature review of inhaled corticosteroid induced secondary hypoadrenalism.

1. Lipworth BJ. Systemic adverse effects of inhaled corticosteroid therapy: A systematic review and meta-analysis. Archives of Internal Medicine, 1999. 159(9): p. 941-955.
2. Mortimer KJ, Tata LJ, Smith CJP, West J, Harrison TW, Tattersfield AE, Hubbard RB. Oral and inhaled corticosteroids and adrenal insufficiency: a case-control study. Thorax, 2006. 61(5): p. 405-408.
3. Lapi F, Kezouh A, Suissa S, Ernst P. The use of inhaled corticosteroids and the risk of adrenal insufficiency. Eur Respir J, 2013. 42(1): p. 79-86.
4. Molimard M, Girodet PO, Pollet C, Fourrier-Réglat A, Daveluy A, Haramburu F, Fayon M, Tabarin A. Inhaled corticosteroids and adrenal insufficiency: prevalence and clinical presentation. Drug Safety, 2008. 31(9): p. 769-774.
5. Samaras N, Schneider A, Frangos E, Forster A, Samaras D. A rare case of adrenal insufficiency induced by inhaled corticosteroids. Journal of the American Geriatrics Society, 2013. 61(5): p. 841-842.
6. Schwartz RH, Neacsu O, Ascher DP, Alpan O. Moderate dose inhaled corticosteroid-induced symptomatic adrenal suppression: case report and review of the literature. Clinical Pediatrics, 2012. 51(12): p. 1184-1190.
7. Johnson SR, Marion AA, Vrchocky T, Emmanuel PJ, Lujan-Zilbermann J. Cushing syndrome with secondary adrenal insufficiency from concomitant therapy with ritonavir and fluticasone. The Journal of Pediatrics, 2006. 148: p. 386-388.

8. Fardon TC, Lee DKC, Haggart K, McFarlane LC, Lipworth BJ. Adrenal suppression with dry powder formulations of fluticasone propionate and mometasone furoate. *American Journal of Respiratory and Critical Care Medicine*, 2004. 170(9): p. 960-966.
9. Zöllner EW, Lombard C, Galal U, Hough S, Irusen E, Weinberg E. Hypothalamic-pituitary-adrenal axis suppression in asthmatic children on inhaled and nasal corticosteroids—more common than expected. *Journal of Pediatric Endocrinology Metabolism*, 2011. 24(7-8): p. 529-534.
10. Zöllner EW, Lombard C, Galal U, Hough S, Irusen E, Weinberg E. Hypothalamic-Pituitary-Adrenal Axis Suppression in Asthmatic School Children. *Pediatrics*, 2012. 130(6): p. 1512-1519.

Effect of intentional weight loss on bone mineral density in overweight and obese individuals - systematic review and meta-analysis

Jessica Zibellini¹, Radhika Seimon¹, Michelle Hsu¹, Crystal MY Lee¹, Alice Gibson¹, Amanda (Sainsbury) Salis^{1,2}

1. Boden Institute of Obesity, Nutrition, Exercise and Eating Disorders, Boden Institute of Obesity, Nutrition, Exercise and Eating Disorders, The University of Sydney, Sydney, NSW, Australia

2. Sydney Medical School, School of Psychology, Faculty of Science, University of Sydney, Sydney

The prevalence of obesity is escalating yearly, with diet-induced weight loss considered the primary treatment option. However, some but not all recent studies have alluded to the possibility that diet-induced weight loss has a harmful effect on bone mineral density (BMD), which could increase the risk of osteoporotic fractures.

A systematic review and meta-analysis was conducted to quantify the effect of diet-induced weight loss on BMD. Data on 40 dietary interventions, from 28 studies on healthy overweight/obese adults undergoing a diet-induced weight loss regime examining BMD at the hip, spine or total body via dual energy x-ray absorptiometry were included. A random effects model was used to examine the effect of the duration of the intervention on both weight and BMD.

Body weight decreased significantly irrespective of the length of the dietary intervention. There was a significant decrease in hip BMD with dietary interventions of 6-month ($p=0.000$, $n = 6$ interventions) and 24 month ($p= 0.047$) duration. Three of the studies that used a 6-month dietary intervention also measured BMD at 12 months from baseline. In these 3 studies, hip BMD was significantly decreased at 6 months ($p=0.000$), and the decrease from baseline remained also at 12 months ($p=0.050$). When BMD was investigated in the lumbar spine and the total body, no significant changes in BMD occurred following dietary interventions ranging from 3 to 24 months' duration.

This meta analysis has shown that loss of BMD in the hip – but not in the spine or total body – occurs in response to diet-induced weight loss in overweight and obese individuals. More investigation needs to be conducted to determine the long-term effects that diet-induced weight loss may have on bone and fracture risk.